

ORIGINAL ARTICLES

ADRENOCORTICAL TUMORS: RESULTS OF TREATMENT AND STUDY OF WEISS'S SCORE AS A PROGNOSTIC FACTOR

Antonio Marmo Lucon, Maria Adelaide Pereira, Berenice B. Mendonça, Maria Claudia Zerbini, Luiz B. Saldanha and Sami Arap

RHCFAP/3102

LUCON AM et al. - Adrenocortical tumors: results of treatment and study of Weiss's score as a prognostic factor. *Rev. Hosp. Clín. Fac. Med. S. Paulo* 57(6):251-256, 2002.

PURPOSE: The differential diagnosis between benign and malignant adrenal cortical tumors circumscribed to the gland is controversial. One hundred and seven patients with adrenal cortex tumors (excluding those with primary hyperaldosteronism) were studied to assess the 5-year survival rate of adults, children, patients stratified by pathological stage, and patients stratified according to Weiss's score of ≤ 3 or > 3 .

METHODS: The patients were evaluated both clinically and biochemically. One hundred and five patients underwent surgery and were classified pathologically as stages I, II, III, or IV. The tumors were weighed, measured, and classified according to Weiss's criteria and divided into 2 groups: ≤ 3 and > 3 .

RESULTS: After 5 years, the survival rate was 77.5% for the whole group, 74.61% for the adults, 84.3% for the children, 100% for stage I, 83.9% for stage II, 33% for stage III, and 11.7% for stage IV groups. Additionally, after 5 years, 100% of the patients with tumors with Weiss's score ≤ 3 were alive compared to 61.65% of those with Weiss's score > 3 . The average weights of the tumors of score ≤ 3 and > 3 were 23.38 ± 41.36 g and 376.3 ± 538.76 g, respectively, which is a statistically significant difference. The average sizes of tumors of Weiss's score ≤ 3 and > 3 were 3.67 ± 2.2 cm and 9.64 ± 5.8 cm, respectively, which is also a statistically significant difference.

CONCLUSIONS: Weiss's score may be a good prognostic factor for tumors of the adrenal cortex. Additionally, there was a statistically significant difference between the average weight and size of tumors with benign behavior (Weiss's score ≤ 3) and those with malignant behavior (Weiss's score > 3).

DESCRIPTORS: Adrenocortical carcinoma. Weiss's score. Adrenocortical tumors. Adrenocortical adenomas. Adrenal neoplasia.

Tumors arising in the adrenal cortex are potentially malignant. In the past, the majority of adrenal neoplasms were discovered as a result of the symptoms caused by the growth of the nonfunctioning tumor (pain, abdominal mass, or metastases) or the clinical picture of the functioning tumor: primary aldosteronism, Cushing's syndrome, virilization, or feminization either alone or in association. At the present time, very small nodules—either asymptomatic

(incidentalomas) or oligosymptomatic, for which laparoscopic ablation has shown itself to be a good option especially for benign lesions¹—are discovered by ultrasonography, computerized tomography (CT), and magnetic resonance imaging (MRI). Tumors not causing symptoms and signs of adre-

From the Department of Urology, Endocrinology and Pathology, Hospital das Clínicas, Faculty of Medicine, University of São Paulo.

nal overactivity may be biochemically functional, and those patients who from the clinical point of view present Cushing's syndrome or virilization may have excessive production of both glucocorticoids and androgens. The histopathological distinction between benign neoplasia (adenoma) and malignant neoplasia (carcinoma) is very difficult to draw. There is no question but that invasion of surrounding tissue and distant metastases define these neoplasms as carcinomas,

but in the absence of these characteristics, the histopathological analysis of the adrenal tumor is controversial and makes use of multiple histopathological criteria suggestive of malignancy, though none of them is pathognomonic³⁻⁵. Furthermore, each of the 3 most important reported systems has its particular aspects, and in some cases any one of them characterizes the tumor as benign or indeterminate while another may suggest malignancy⁶. Although the size of the tumor has been advocated as a parameter for surgical removal, because the small ones tend to be benign and the larger malignant⁷, this criterion varies according to the author—6 cm⁸, 4 cm⁷, or 3 cm⁹—demonstrating that there is no unanimity on this subject.

We reviewed our cases of adrenal cortex tumors (excluding those tumors that produced primary hyperaldosteronism) in order to analyze after a 5-year follow up the overall survival rates of adults, children, patients with tumors of pathological stages I, II, III, or IV in accordance with Macfarlane's classification¹⁰, and patients with tumors scoring 0 to 3 and 4 to 8 on Weiss's scale to verify whether that scale may be used as a prognostic factor. We also studied the correlation between the weight and size of tumors classified between 0 and 3 and 4 and 8 according to Weiss's score to assess a possible significant difference between the weight and size of the 2 groups of tumors.

METHODS

Study subjects

The records of 107 patients treated between 1979 and 1998 were reviewed retrospectively. In 105 of them, the histopathological diagnosis of adrenocortical neoplasia was made in the surgical specimen. The remaining 2 patients did not undergo surgery, and the diag-

nosis was made on the basis of the clinical picture of Cushing's syndrome with virilization, and Cushing's syndrome associated with feminization in patients with adrenal tumors seen in imaging studies. Ninety-two patients were females, and 15 were males aged between 7 months and 69 years (median age of 29 years). Of these, 29 were below 10 years of age and were included in the group of children. The race distribution was white 95.5%, black 3.3%, and Asian 1.1%.

Clinical picture

The duration of clinical history varied from 18 days to 8 years. Clinically, 40 patients presented Cushing's syndrome, 29 presented virilization, 1 Cushing's syndrome with feminization, and 10 nonfunctioning tumors, 3 of which were discovered after work up for nonspecific abdominal pain, and 7 were discovered incidentally.

Hormonal evaluation

The biochemical assessment of the production of glucocorticoids was made by measuring baseline urinary cortisol and serum cortisol before and after the administration of 2 mg of dexamethasone. Androgen production was assessed by measuring serum levels of androstenedione, dehydroepiandrosterone sulfate, and testosterone. The tumors of patients with a high basal urinary cortisol level or those whose serum cortisol was not depressed by the administration of dexamethasone were considered to be producers of cortisol. The tumors of patients that presented high levels of at least 1 of the hormones were classified as producers of androgens. Of the 40 patients with Cushing's syndrome, 39 (97.5%) had only cortisol-producing tumors, and 1 (2.5%) had a cortisol- and androgen-producing tumor. Of the

29 patients with virilization, 27 (93%) had androgen-producing tumors, and 2 (7%) had androgen- and cortisol-producing tumors. Of the 29 patients with mixed clinical syndrome, 28 (96.5%) had androgen- and cortisol-producing tumors, and 1 had a cortisol- and estrogen-producing tumor. Of the patients with clinically nonfunctioning tumors, only 1 (10%) had elevated levels of serum cortisol. In the other patients (90%), glucocorticoids, androgens, and aldosterone were at normal levels.

Imaging studies

Ultrasonography performed on 74 patients detected 82.4% of the primary tumors. CT carried out on 73 patients and MRI on 21 detected 100% of the primary tumors with precision. Nine patients had involvement of the inferior vena cava by tumor thrombi. Ultrasonography revealed tumor thrombi in 37.5% (3 out of 8), CT in 55% (5 out of 9), and MRI in 100% (4 out of 4) of the cases in which the procedure was undertaken. Only 1 patient (0.9%) had bilateral tumors; 47 (44%) had the tumor on the right side, and 54 (55%) had it on the left.

Treatment

One hundred and five patients underwent surgery. The other 2 were not candidates because they presented severe respiratory insufficiency, 1 of them with tumoral extension into the inferior vena cava and pulmonary metastases. The tumors of up to 5 cm in the imaging studies were removed by lumbotomy with resection of the 11th rib, and those of more than 5 cm were removed by thoracophrenolaparotomy. Seventy-one adrenalectomies alone; 22 adrenalectomies with nephrectomies; 8 adrenalectomies with nephrectomies and splenectomy; 1 adrenalectomy with nephrectomy, splenectomy, and caudal pancreatectomy; and 3 adrenal-

ectomies with nephrectomies and partial (right) hepatectomy were performed. Only enlarged or suspected lymph nodes were removed. No routine lymphadenectomies were performed.

Pathological findings

The weights of the tumors were available in 68 cases, varying from 4 g to 2600 g (average 249 ± 454 g). Eighty-one tumors were measured, and their sizes varied from 1.4 cm to 30 cm (average 6.8 ± 51 cm). The pathological stage was available for 95 cases: 45 patients having stage I (up to 5 cm within the capsule), 33 patients stage II (more than 5 cm within the capsule), 3 patients stage III (any size with extracapsular extension, invasion of blood vessels, or nodes), and 24 patients stage IV (distant metastases). Finally, the slides were re-assessed by one and the same pathologist (MCZ); the tumors were classified according to Weiss's criteria³, which comprise 9 parameters (nuclear grade, mitotic rate, atypical mitosis, character of cytoplasm, architecture of tumor cells, necrosis, invasion of venous structures, invasion of sinusoid structures, and invasion of the capsule of tumor); and the cases were divided into 2 groups: Weiss's score 0 to 3 and scores greater than 3. The 22 patients with metastases who underwent surgery (2 others did not) received some kind of chemotherapy: preoperative mitotane (7 patients), postoperative mitotane (18 patients), and postoperative cisplatin with etoposide (9 patients). Of these 22 patients, only 1 (a black woman) achieved complete response with total disappearance of pulmonary and hepatic metastases after undergoing adrenalectomy with nephrectomy and caudal pancreatectomy followed by chemotherapy using mitotane. The postoperative exams showed a tumor thrombus in the inferior vena cava that had not been seen or withdrawn dur-

ing the operation and was later removed during a second operation. This patient was found free of disease at an 8-year follow-up exam.

Statistical analysis

Survival periods were estimated from the time of treatment and were calculated using the product-limit method of Kaplan and Meyer¹¹. Comparisons with respect to weight and size of the tumors were performed with the Mann-Whitney nonparametric test¹². All reported *P* values are 2-tailed. *P* values of less than 0.05 were taken to indicate statistically significant differences.

RESULTS

There were no deaths in the immediate postoperative period. The patients were followed up over a period of 6 months to 240 months, and 49 of them could be evaluated after a 5-year period. After 5 years, 77.5% of the whole group was alive, with the 84.3% survival rate of the children exceeding the 74.61% of the adults (Fig. 1). Survival rates after 5 years were stage I patients, 100%; stage II, 83.96%; stage

III, 33%; and stage IV, 11.17% (1 patient) (Fig. 2). After 5 years, 100% of the patients with Weiss's scores of ≤ 3 were alive compared to 61.65% of those with Weiss's score of 4 to 8 (Fig. 3). The weight of 39 tumors with Weiss's scores of 0 to 3 varied from 2.5 g to 190 g, with an average of 23.38 ± 41.36 g and a median weight of 12 g, whereas the weight of 31 tumors with Weiss's scores of 4 to 8 varied from 4 g to 2600 g with an average of 376.13 ± 538.76 g and a median weight of 160 g, with a statistically significant difference between the groups (*P* < 0.0001) (Fig. 4). The size of 39 tumors with Weiss's scores of from 0 to 3 was 1 cm to 13 cm, with an average of 3.67 ± 2.2 cm and a median size of 3 cm. The size of 47 tumors with Weiss's scores of 4 to 8 varied from 1.5 cm to 30 cm with an average of 9.64 ± 5.8 cm and a median size of 9 cm, with a statistically significant difference between the 2 groups (*P* < 0.0001) (Fig. 5).

DISCUSSION

The normal adrenal cortex and the adrenal tumor secrete 3 main groups of hormones: mineralocorticoids, glucocorticoids, and sexual hormones

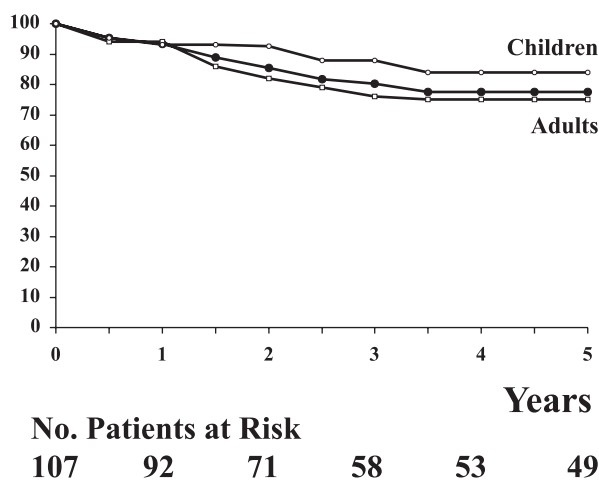


Figure 1 - Kaplan-Meier Analysis of Overall Survival among 107 patients with adrenal cortical tumor. ○ children, ● all group, and □ adults.

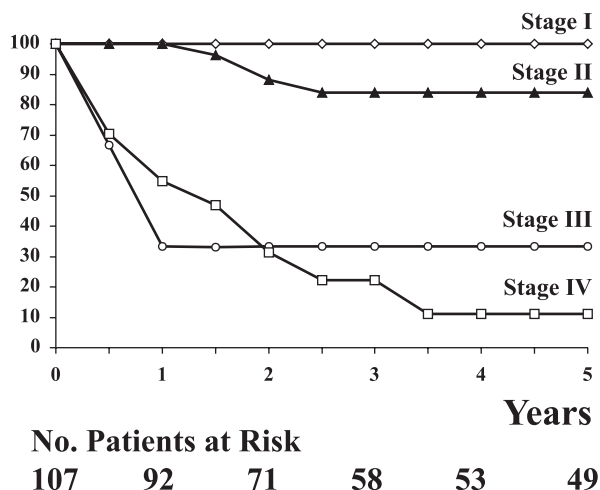


Figure 2 - Kaplan-Meier Analysis of Overall Survival among 107 patients with adrenal cortical tumor, according to the stage.

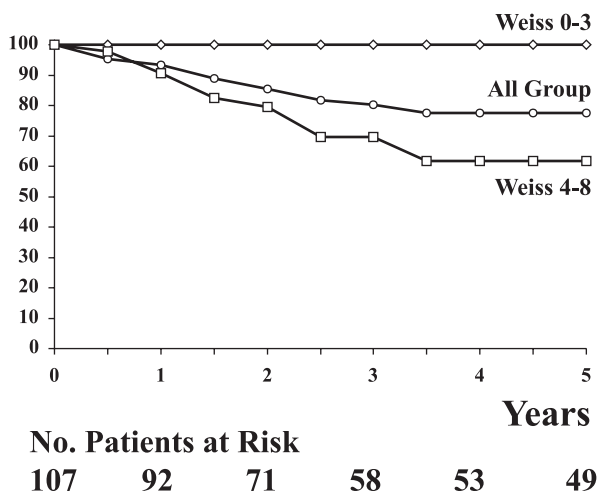


Figure 3 - Kaplan-Meier Analysis of Overall Survival among 107 patients with adrenal cortical tumor, according to the score of Weiss.

(androgens and estrogens). The tumors of the glomerulosa zone, which is physiologically responsible for aldosterone synthesis, behave differently from cortical tumors: usually they are small and functioning¹³ and are rarely malignant^{14,15}. On the other hand, cortical tumors may frequently be nonfunctioning, as is true of the incidentalomas¹⁷, and more often than the aldosterone-producing tumors may behave malignantly¹⁶. For these reasons, adrenocortical tumors that produce only aldosterone and which virtually always have excellent progn-

osis¹⁵ have been excluded from this series. The other adrenocortical tumors were also studied together without separation into the so-called adenomas and carcinomas, because it is often difficult or even impossible to make a differential diagnosis for neoplasms limited to the adrenal gland^{6,18-20} due to the nonuniform criteria^{4,5}, which are not given in detail even in recent publications^{13,16,21}. Weight and size have already been related to prognosis; however, although it has been affirmed that the majority of the adenomas weigh less than 50 g and measure less

than 5 cm²², there have been cases of tumors 3 cm long²³ or 40 g in weight²⁴ that produced metastases and were therefore correctly classified as carcinomas. It should be noted that in the study mentioned above, the 40 g tumor was initially classified incorrectly based on its histology as an adenoma²⁴. Neither does the functional status serve as a prognostic factor, because patients with both functioning and nonfunctioning carcinomas had similar survival curves^{21,25}. Although the 24-hour urinary free cortisol and serum lactate dehydrogenase levels tended to be higher among patients with carcinoma and Cushing's syndrome, no significant statistical difference was found when comparing adenomas and carcinomas¹⁶. Helicoidal computerized tomography provides acceptable sensitivity and specificity in the differentiation between adenomas and nonadenomas, but the lack of long-term follow up leads to the possible persistence of diagnostic error²⁶. The same may be said of scintigraphy with selenium cholesterol¹³. In this study, all the patients with tumors in the adrenal cortex—excluding those with primary aldosteronism—that had Weiss's scores of less than 4 at the histopathological examination of the adrenal tumor tissue were still alive after 5 years of follow up; thus the tumors behaved benignly as if they were true adenomas. On the other hand, the survival curve of patients having tumors with Weiss's scores of 4 to 8 fell over time, suggesting possible malignant behavior for this group. Another interesting aspect is that there was a statistically significant difference between the sizes and weights of the tumors with Weiss's scores of less than 4 (which behave benignly) and of those with Weiss's scores of 4 to 8 (which behave with apparent malignancy), thus supporting the idea that even small non-functioning tumors should be considered for laparoscopic removal

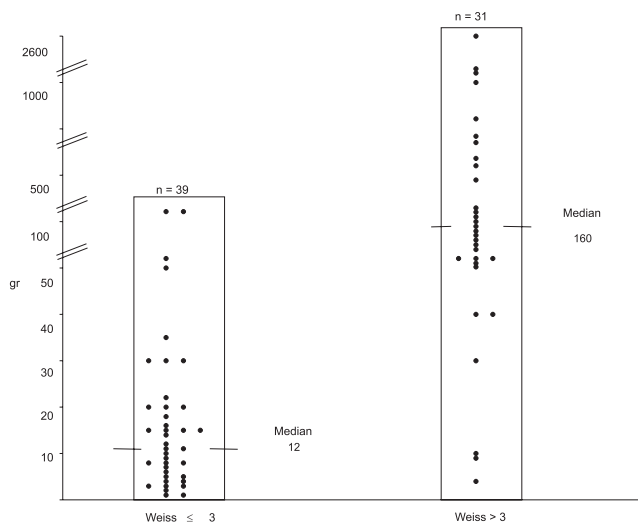


Figure 4 - Figure 4 - Weight of the adrenal tumors by Weiss's score ≤ 3 and > 3 . Each (•) represents one tumor

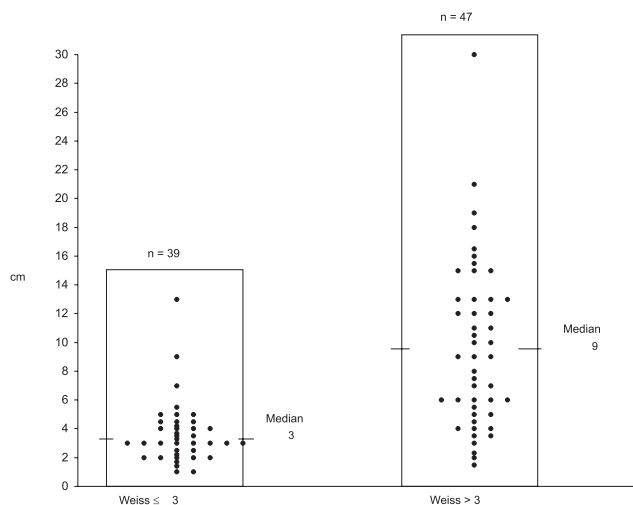


Figure 5 - Size of adrenocortical tumors by Weiss's score ≤ 3 and > 3 . Each (•) represents one tumor

because of the slight possibility of being malignant¹. As has already been reported²⁰, the children in this study survived longer on average than the adults. The 5-year survival rate of 61.65% for our patients with Weiss's scores of from 4 to 8 was considerably greater than that of the 26% to 36% reported in contemporary reviews of patients with carcinoma of the adrenal cortex^{21,27}, probably because the unmentioned criteria for the definition of malignancy were different. As was

to be expected, the 5-year survival rates for stage I (100%) and stage II (83.9%) patients who had tumors circumscribed to the adrenal gland were considerably greater than those with stage III (33.3%) and stage IV (11.17%) tumors, which were certainly carcinomas. As others have reported²⁸, no standardized lymphadenectomy was performed (only enlarged and suspected lymph nodes were removed), so the pathological staging in I and II may not have been perfect. This may

not have influenced the outcome because lymphadenectomy has not been shown to improve survival or decrease recurrence²⁷.

ACKNOWLEDGMENT

We thank Dr. João Egidio Romão Jr., Dr. Frederico A.Q. Silva, Dra. Ana C. Latrônico and Dr. Eder Quintão for their substantial contributions to this project.

RESUMO

RHCFAP/3102

LUCON AM e col - Tumores do córtex da supra-renal: resultados do tratamento e estudo do escore de Weiss como fator prognóstico **Rev. Hosp. Clín. Fac. Med. S. Paulo 57(6): 251-256, 2002.**

OBJETIVOS: O diagnóstico diferencial entre tumores benignos e malignos do córtex da supra-renal é controverso. Cento e sete pacientes com tumores do córtex da supra-renal (excluindo aqueles com hiperaldosteronismo primário) foram estudados

para avaliar a sobrevida em 5 anos de adultos, de crianças e de acordo com o estadiamento patológico ≤ 3 ou >3 segundo o escore de Weiss.

MÉTODOS: Os pacientes foram avaliados clínica e laboratorialmente. Cento e cinco pacientes foram operados e foram classificados em estadios patológicos I, II, III ou IV. Os tumores foram pesados, medidos, classificados de acordo com os critérios de Weiss e divididos em 2 grupos: ≤ 3 e >3 .

RESULTADOS: Após 5 anos a sobrevida foi de 77,5% para o grupo

inteiro, 74,61% para os adultos, 84,3% para as crianças, 100% para estadios I, 83,9% para estadios II, 33% para estadios III e 11,7% para estadios IV. Após 5 anos 100% dos pacientes com tumores com escore de Weiss ≤ 3 estavam vivos contra 61,65% dos que tinham escore de Weiss >3 . Os pesos médios dos tumores com escore de Weiss ≤ 3 e >3 foram de $23,38 \pm 41,36$ g e de $376,2 \pm 538,76$ g, os quais são estatisticamente diferentes. Os tamanhos médios dos tumores com escore de Weiss ≤ 3 e >3 foram de $3,67 \pm 2,2$

cm e $9,64 \pm 5,8$ cm que são também estatisticamente diferentes.

CONCLUSÃO: O escore de Weiss pode ser um bom fator prognóstico para tumores do córtex da supra-renal. Há também uma diferença estatística

significante entre o peso médio e o tamanho médio dos tumores com comportamento benigno (escore de Weiss ≤ 3) e aqueles com comportamento maligno (escore de Weiss >3).

DESCRITORES: Tumores adrenocorticais. Escore de Weiss. Carcinoma de córtex adrenal. Adenoma de córtex adrenal. Neoplasia da supra-renal.

REFERENCES

- JANETSCHKEK G - Surgical options in adrenalectomy: laparoscopic versus open surgery. *Curr Opin Urol* 1999; **9**: 213-218.
- LUTON JP, CERDAS S, BILLAUD L et al. - Clinical features of adrenocortical carcinoma, prognostic factors and the effect of mitotane therapy. *N Engl J Med* 1990; **322**: 1195-201.
- WEISS LM - Comparative histologic study of 43 metastasizing and nonmetastasizing adrenocortical tumors. *Am J Surg Pathol* 1984; **8**: 163-169.
- VAN SLOOTEN H, SCHABERG A, SMEENK D et al. - Morphologic characteristics of benign and malignant adrenocortical tumors. *Cancer* 1985; **55**: 766-773.
- HOUGH AJ, HOLLIFIELD JW, PAGE DL et al. - Prognostic factors in adrenal cortical tumors: a mathematical analysis of clinical and morphologic data. *Am J Clin Pathol* 1979; **72**: 390-339.
- MEDEIROS LJ & WEISS LM - Adrenal Gland. Tumors and Tumor-like Lesions. *The Difficult Diagnosis in Surgical Pathology*. Philadelphia; Saunders 1966.
- KASPERLIK - ZATUSKA AA, ROSTONOWSKA E, STONVINSKA - SRZEDNICKA J et al. - Incidentally discovered adrenal mass (incidentaloma): investigation and management of 208 patients. *Clin Endocrinol* 1997; **46**: 29-37.
- COPELAND PM - The incidentally discovered adrenal mass. *Ann Intern Med* 1983; **98**: 940-945.
- PRINZ RA, BROOKS MH, CHURCHILL R et al. - Incidental asymptomatic adrenal masses detected by computed tomographic scanning: is operation required? *JAMA* 1982; **248**: 701-704.
- MAC FARLANE DA - Cancer of the adrenal cortex the natural history, prognosis and treatment in a study of fifty-five cases. *Ann R Coll Surg Engl* 1958; **23**: 155-86.
- KAPLAN EL, MEIER P - Nonparametric estimation from incomplete observations. *J Am Stat Assoc* 1985; **53**: 457-81.
- DAMIEL WW - *Biostatistics: a foundation for analysis in the sciences*. 7th ed. New York: John Wiley, 1999.
- BARZON L, SCARONI C, SONINO N et al. - Incidentally discovered adrenal tumors: endocrine and scintigraphic correlates. *J Clin Endocrinol Met* 1988; **83**: 55-62.
- VAUGHAN ED Jr., CAREY RM - Adrenal carcinoma. Adrenal disorders. New York, Thieme Medical Publishers, 1989.
- SIREN J, VÄLIMÄKIM, HIUKURI K et al. - Adrenalectomy for primary aldosteronism long-term follow-up study in 29 patients. *World J Surg* 1998; **22**: 418-422.
- DAITCH JA, GOLDFARB DA, NOVICK AC - Cleveland Clinic Experience with Adrenal Cushing's Syndrome. *J Urol* 1997; **158**: 2051-2055.
- BARZON L, BOSCARO M - Diagnosis and management of adrenal incidentalomas. *J Urol* 2000; **163**: 398-407.
- LACK EE - Atlas of tumor pathology - tumors of the adrenal gland and extra-adrenal paraganglia. Washington-DC, Published by the Armed Forces Institute of Pathology, 1997.
- WELLS AS, MERKE DO, CUTLER Jr. GB et al. - The role of laparoscopic surgery in adrenal disease. *J Clin Endocrinol Metabol* 1998; **83**: 3041-49.
- MENDONÇA BB, LUCON AM, MENEZES CAV et al. - Clinical hormonal and pathological findings in a comparative study of adrenocortical neoplasia in childhood and adulthood. *J Urol* 1995; **154**: 2004-9.
- TRITOS NA, CUSHING GW, HEATLEY G et al. - Clinical features and prognostic factors associated with adrenocortical carcinoma: Lahey Clinic Medical Center Experience. *Am Surg* 2000; **66**: 73-79.
- TANG CK, GRAY GF - Adrenocortical neoplasms. *Prognosis and Urology* 1975; **5**: 691-695.
- ICARD, LOUVEL A, CHAPNIS Y - Survival rates and prognostic factors in adrenocortical carcinoma. *World J Surg* 1992; **16**: 753-758.
- GANDOUR MJ, GRIZZLE WE - A small adrenocortical carcinoma with aggressive behavior. An evaluation of criteria for malignancy. *Arch Pathol Lab Med* 1986; **110**: 1076-1079.
- NADER S, HICHEY RT, SELLIN RV et al. - Adrenal cortical carcinoma - Study of 77 cases. *Cancer* 1983; **52**: 707-711.
- SZOLAR DH, KAMMERHUBER F - Quantitative CT evaluation of adrenal gland masses: a step formed in the differentiation between adenomas and nonadenomas? *Radiology* 1997; **202**: 517-521.
- HARRISON LE, GAUDIN PB, BRENNAN MF - Pathologic features of prognostic significance for adrenocortical carcinoma after curative resection. *Arch Surg* 1999; **134**: 181-185.
- LEE JEL, BERGER DH, EL NAGGAR AK et al. - Surgical management, DNA content, and patient survival in adrenal cortical carcinoma. *Surgery* 1995; **18**:1090-8.

Received for publication on November 22, 2001.