
THE EFFECTS OF GLUTAMINE-SUPPLEMENTED DIET ON THE INTESTINAL MUCOSA OF THE MALNOURISHED GROWING RAT

Uenis Tannuri, Francisco R. Carrazza and Kiyoshi Iriya

RHCFAP/3009

TANNURI U et al. - The effects of glutamine-supplemented diet on the intestinal mucosa of the malnourished growing rat. *Rev. Hosp. Clín. Fac. Med. S. Paulo* 55 (3):87-92, 2000.

SUMMARY: Glutamine is the most abundant amino acid in the blood and plays a key role in the response of the small intestine to systemic injuries. Mucosal atrophy is an important phenomenon that occurs in some types of clinical injury, such as states of severe undernutrition. Glutamine has been shown to exert powerful trophic effects on the gastrointestinal mucosa after small bowel resection or transplant, radiation injury, surgical trauma, ischemic injury and administration of cytotoxic drugs. Since no study has been performed on the malnourished animal, we examined whether glutamine exerts a trophic effect on the intestinal mucosa of the malnourished growing rat. Thirty-five growing female rats (aged 21 days) were divided into 4 groups: control – chow diet; malnutrition diet; malnutrition+chow diet; and malnutrition+glutamine-enriched chow diet (2%). For the first 15 days of the experiment, animals in the test groups received a malnutrition diet, which was a lactose-enriched diet designed to induce diarrhea and malnutrition. For the next 15 days, these animals received either the lactose-enriched diet, a regular chow diet or a glutamine-enriched chow diet. After 30 days, the animals were weighed, sacrificed, and a section of the jejunum was taken and prepared for histological examination. All the animals had similar weights on day 1 of experiment, and feeding with the lactose-enriched diet promoted a significant decrease in body weight in comparison to the control group. Feeding with both experimental chow-based diets promoted significant body weight gains, although the glutamine-enriched diet was more effective.

Results: The morphological and morphometric analyses demonstrated that small intestinal villous height was significantly decreased in the malnourished group, and this change was partially corrected by the two types of chow-based diet. Crypt depth was significantly increased by malnutrition, and this parameter was partially corrected by the two types of chow-based diet. The glutamine-enriched diet resulted in the greatest reduction of crypt depth, and this reduction was also statistically significant when compared with control animals.

Conclusions: Enteral glutamine has some positive effects on body weight gain and trophism of the jejunal mucosa in the malnourished growing rat.

DESCRIPTORS: Glutamine. Aminoacid. Enteral nutrition.

Glutamine is the most abundant amino acid in the blood and in the free amino acid pool of the body¹. Additionally, it is quantitatively the most important amino acid involved in the inter-organ flux². In a number of mammalian species, the gut is a major site of glutamine utilization, and the small bowel epithelium is considered the principal organ of glutamine uptake³.

Clinical and animal experimental studies suggest that glutamine plays a

key role in the response of the small intestine to systemic injury and infection. Trauma⁴ and glucocorticoid⁵ treatment induce increased consumption of glutamine, and a reduced uptake of this amino acid has been reported in septic and trauma patients^{6,7} and animals⁸ as

From the Pediatric Surgery Laboratory (LIM-30) and the Pathology Divisions, Hospital das Clínicas, Faculty of Medicine, University of São Paulo.

a consequence of a decreased circulating concentration^{9,10}. Therefore, in cases of systemic injuries, the decrease of circulating glutamine concentration and reduced uptake of this amino acid⁶ contribute to mucosal atrophy, bacterial translocation across the gastrointestinal mucosa, and gut-mediated sepsis^{9,10}.

Mucosal atrophy is an important phenomenon that occurs in some types of clinical injuries, such as states of severe undernutrition¹¹⁻¹³. It has been sug-

gested that the absence of glutamine from enteral or parenteral nutritional solutions exacerbates such effects¹⁰. In contrast, glutamine has been shown to exert powerful trophic effects on the gastrointestinal mucosa after small bowel resection¹⁴ or transplant¹⁵, radiation injury¹⁶, surgical trauma¹⁷, ischemic injury¹⁸, and administration of cytotoxic drugs¹⁹. To our knowledge, however, the effects of a glutamine-enriched diet on the regeneration of the intestinal mucosa villi have not been assessed in malnourished growing animals. Therefore, utilizing a model of malnutrition in growing rats and histomorphometric techniques, we examined, in the present study, whether glutamine exerts a trophic effect in the intestinal mucosa.

MATERIAL AND METHODS

Animals – experimental groups

Thirty-five female growing rats (aged 21 days) were used in the study. The animals, which were allowed a minimum of 3 days to acclimate to the animal care facility, were housed in individual cages during the study period of 30 days, with water and chow diet *ad libitum*.

On experiment day 1, the animals were weighed and randomly divided into 4 groups according to the experimental procedure:

control – chow diet (n = 3)

malnutrition – lactose-enriched diet (n = 9)

malnutrition+chow diet (n = 10)

malnutrition+glutamine-enriched diet (n = 13)

Diets

Animals in the control group received a regular balanced regimen utilized for growing rats, during the entire study period. The animals of the

experimental groups received a lactose-enriched diet in order to induce diarrhea and malnutrition from experiment day 1 through experiment day 15²⁰. From experiment day 16 through experiment day 30, the rats in the malnutrition group were maintained on the same diet, while the third group received a balanced chow diet, and the fourth group received a glutamine-enriched chow diet. The components of these diets are given in Table 1. The diets were isocaloric and isonitrogenous.

Harvest procedures

On experiment day 30, the animals were weighed and sacrificed by intraperitoneal injection of thiobarbiturate 2.5%. A midline abdominal incision was made, the small intestine was removed, and a 3-cm section of the jejunum was taken and prepared for the histological studies.

The formalin-fixed gut tissues were embedded in paraffin, sectioned, and stained with hematoxylin and eosin. Villous height and crypt depth in all tissues were determined by using a Nikon microscope equipped with a 5X magnification objective and a 20X magnification eyepiece that contained a test scale of 1 mm. At least 20 to 25 well-oriented crypt-villous units per small intestinal sample were measured and averaged by two pathologists who were masked to animal groups.

Statistical Analysis

Mean and standard deviation were calculated for each parameter, and they were compared using one-way analysis of variance. When a significant difference was observed, the 4 study groups were compared using the Student-Neuman-Keuls test. The level of significance was $P < 0.05$.

RESULTS

Body weights

Body weights in the first and last days of the experiment are shown in Table 2.

All the animals had similar weights on experiment day 1 ($P > 0.05$). As shown in Table 2, feeding with the lactose-enriched diet promoted a significant decrease in body weight in comparison to the control group (79.30 ± 3.28 versus 171.07 ± 15.38). The administration of both experimental diets promoted significant body weight gains, although the glutamine-enriched diet was more effective.

Histopathology

Representative histologic sections of jejunal mucosa are shown in Figures 1 to 3. The qualitative analyses of the villi demonstrate that a significant mu-

Table 1 - Components of the diets utilized in the control and experimental groups (in %).

Components (%)	Regular chow diet	Lactose-enriched diet	Glutamin-enriched diet
Protein (casein)	18	18	16
Vitamins	1	1	1
Salts	4	4	4
Fibers	4	4	4
Soya bean oil	8	8	8
Corn starch	65	5	65
Lactose	-	60	-
Glutamine	-	-	2

Table 2 - Body weights of the rats in the first and last day of the experiment (mean±standard deviation).

Groups	Day 1	Day 30 (sacrifice)
Control	46.40±7.10	171.07±15.38
Malnourished	53.55±5.11	79.30±3.28*
Malnourished+regular chow diet	50.9±6.09	128.59±9.29*#
Malnourished+glutamine-enriched diet	51.14±6.02	157.13±10.05*#†

* $P < 0.05$ relative to control

$P < 0.05$ relative to malnourished group

† $P < 0.05$ relative to malnourished+regular diet group

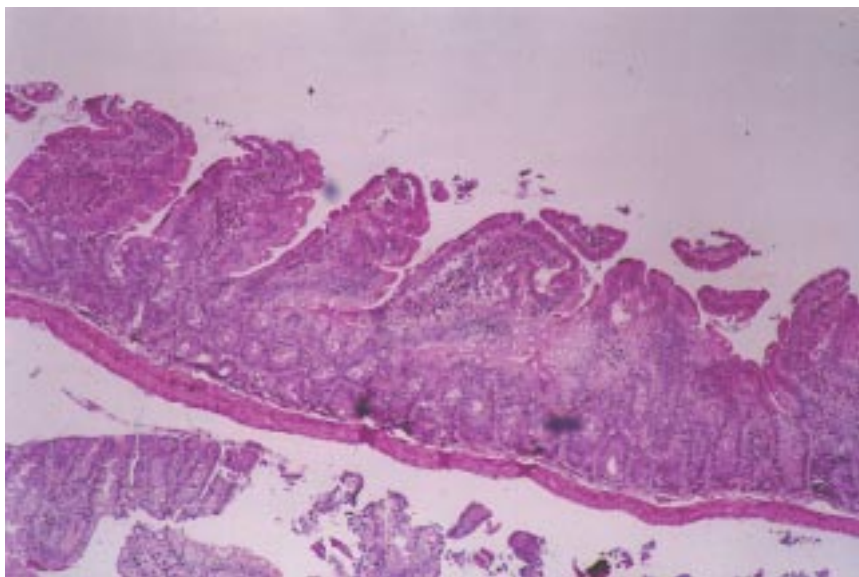


Figure 1 - Representative hematoxylin and eosin-stained section of jejunum of malnourished animal from lactose-enriched diet group. Note the markedly altered morphology of villous and decreased height. Magnification X100.

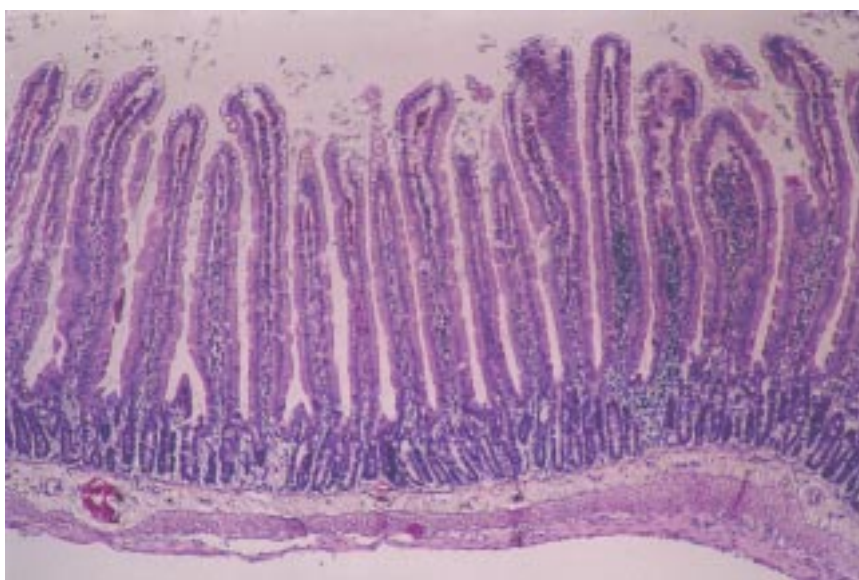


Figure 2 - Representative hematoxylin and eosin-stained section of jejunum of animal from malnutrition and regular chow diet group. Note the marked increase in villous height and the well defined morphology of villous. Magnification X100.

cosal atrophy and structural alteration of the villi occurred in the malnourished animals, and this change was reversed by the administration of both types of chow-based diets.

Histomorphometric studies

Villous height and crypt depth were determined as specific indices of mucosal growth. The effects of dietary alterations on these parameters were expressed in Tables 3 and 4

Small intestine villous height was significantly decreased (Table 3) and crypt depth was significantly increased (Table 4) in the malnourished group; these changes were partially corrected by both types of chow-based diet. Glutamine-enriched diet refeeding resulted in the greatest reduction of crypt depth, and this reduction also was statistically significant when compared with control animals ($P < 0.05$).

DISCUSSION

Malnutrition occurs frequently in pediatric surgical patients, and the association between malnutrition and surgical complications is important in clinical practice. Decreased tissue concentrations of glutamine have been reported in malnourished and trauma patients and animals²¹⁻²³. Parenteral or enteral administered glutamine is preferentially utilized by the rapidly dividing cells of the small bowel mucosa, i.e., enterocytes and lymphocytes. Therefore, the purpose of the current study was to investigate whether the administration of a glutamine-enriched diet has any trophic effect on the intestinal mucosa of the malnourished growing rat.

We used the rat model because the small intestine atrophies markedly during brief periods of starvation or malnutrition, compared with changes in total body mass and weight of other tis-

sues^{24,25}. In previous studies, it has been shown that indices of intestinal cellularity normalized in rats within 24 to 72 hours of full enteral refeeding after various periods of fasting²⁶⁻²⁸.

The lactose-enriched diet utilized to produce malnutrition in the growing rat was quite effective, since the animals demonstrated a poor weight gain during the study period, in comparison to the control group. Concomitantly, the histological and histomorphometric studies of jejunal mucosa demonstrated significant alterations, i.e., a decreased villous height and a compensatory increased crypt depth, as compared to normal rats.

The results of this study demonstrate some positive effects of a glutamine-enriched diet (2% glutamine) for the malnourished growing rat, since it resulted in significant body weight gain in comparison to a regular chow diet, although not equal to control animals, probably due to the short study period of 15 days. Additionally, enteral glutamine promoted jejunal mucosal proliferation, as reflected by the indices of mucosal villous height and crypt depth that were similar to the control animals.

The morphometric analysis of the mucosal villous height supported the conclusion that refeeding with the chow diet was efficacious (Table 3), since the villous height of this group was similar to the control and glutamine-enriched diet groups. Considering only the parameter of villous height, we may conclude that the amino acids of casein were sufficient to promote mucosal villous trophism, and the enrichment with glutamine would not be necessary. In fact, Wirén et al.¹⁷ concluded that an excess of glutamine (4% glutamine diet) in the jejunal lumen may have a potentially negative effect and may decrease the proliferation and villous cell turnover.

Several investigations have demonstrated the positive effects of parenteral

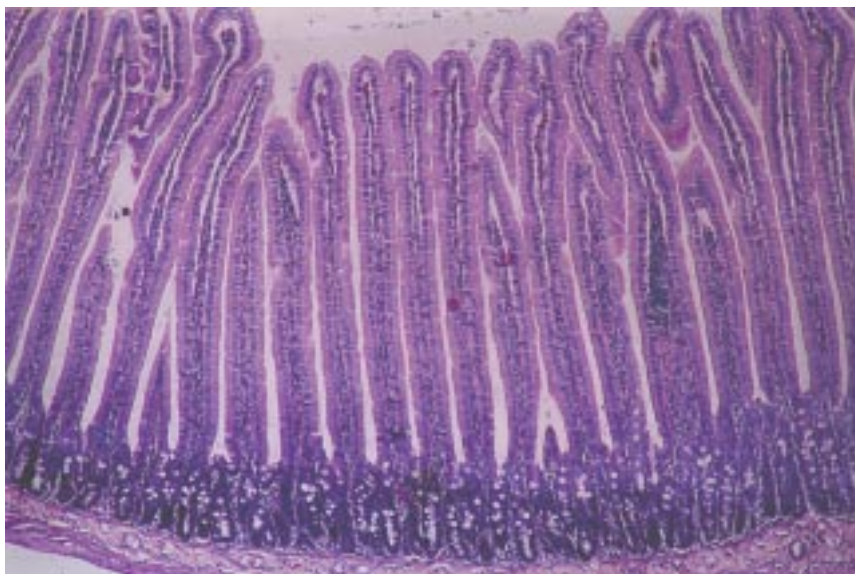


Figure 3 - Representative hematoxylin and eosin-stained section of jejunum of animal from glutamine-enriched diet group. Note that the aspect is similar to the former group. Magnification X100.

Table 3 - Villous height of jejunal mucosa.

Groups	Villous height in mm (number of observations)
Control	0.57±0.12 (40)
Malnourished	0.31±0.11* (60)
Malnourished+regular chow diet	0.50±0.12*# (165)
Malnourished+glutamine-enriched diet	0.49±0.10*# (140)

*P<0.05 relative to control

#P<0.05 relative to malnourished group

Table 4 - Cript depth of jejunal mucosa.

Groups	Cript Depth in mm (number of observations)
Control	0.15±0.033 (40)
Malnourished	0.244±0.055* (60)
Malnourished+regular chow diet	0.23±0.050*# (165)
Malnourished+glutamine enriched diet	0.134±0.036*#† (140)

*P<0.05 relative to control

#P<0.05 relative to malnourished group

†P<0.05 relative to malnourished+regular diet group

infusion of glutamine^{9,10,14,15,29}. The importance of the studies of enteral administration of glutamine in relation to parenteral infusion is based on the fact that the extraction rate of glutamine is higher after intraluminal administration than from parenteral administration³⁰. This difference suggests that the intraluminal extraction reflects utilization

by enterocytes rather than lymphocytes.

Positive effects of glutamine might be expected in other situations when demands are increased because this amino acid is a nonessential one. Recent investigations have shown that in the ischemic-injured intestine, glutamine and transforming growth

factor-alpha stimulate extracellular regulated kinases and enhance recovery of villous surface area¹⁸. Also of interest is that in tumor-bearing rats, occurs an altered mucosal glutamine metabolism that leads to an increased gut permeability and loss of gut barrier function³¹.

In conclusion, this study shows that enteral glutamine has some positive effects on body weight gain and trophism of the jejunal mucosa in the malnourished growing rat. The clinical applications of these results should be considered, mainly in the treatment of mal-

nourished pediatric surgical patients.

ACKNOWLEDGMENTS: The authors thank Maria Cecilia M. Coelho and Neide Aparecida S. R. dos Santos for their excellent technical assistance.

RESUMO

RHCFAP/3009

TANNURI U e col. – Os efeitos de dieta com suplementação de glutamina sobre a mucosa intestinal do rato desnutrido em crescimento.

Rev. Hosp. Clín. Fac. Med. S. Paulo 55(3):87-92, 2000.

A glutamina é o aminoácido mais abundante no sangue e exerce papel importante na resposta do intestino delgado às agressões sistêmicas. Atrofia da mucosa intestinal ocorre em algumas afecções clínicas como desnutrição grave. Foi demonstrado que a glutamina tem ação trófica em situações como período pós-operatório de ressecção ou transplante intestinal, radioterapia, trauma cirúrgico, isquemia intestinal ou administração de drogas citotóxicas. Tais estudos não foram realizados em animais desnutridos em fase de crescimento. Desta forma, no

presente trabalho verificamos se a glutamina exerce ação trófica sobre a mucosa intestinal do rato desnutrido em fase de crescimento. Foram utilizadas 35 ratas com 21 dias de idade, e divididas em 4 grupos: controle – dieta normal; desnutrição – provocada por diarreia induzida pela administração de dieta rica em lactose durante 15 dias; desnutrição+dieta normal durante os 15 dias subsequentes; desnutrição + dieta rica em glutamina (2%). Após 30 dias de experimento os animais foram pesados, mortos e um segmento de jejuno foi colhido para estudos histológicos e histomorfométricos. Os grupos de animais apresentaram médias de pesos semelhantes no primeiro dia de estudo, sendo que a alimentação com dieta rica em lactose (grupo desnutrido) provocou significativa queda de peso em relação aos controles. A re-ali-

mentação com ambos os tipos de dieta promoveu ganho significativo de peso corpóreo, embora a dieta rica em glutamina tenha sido mais eficaz. Os estudos histológicos e histomorfométricos demonstraram que a desnutrição provocou significativa redução do comprimento das vilosidades e aumento das criptas, sendo estas alterações parcialmente corrigidas por ambos os tipos de dieta. A redução no comprimento das criptas foi mais significativa no grupo com glutamina. Conclui-se que a administração enteral de glutamina tem efeitos positivos sobre o ganho ponderal e sobre o trofismo da mucosa intestinal em animais desnutridos em fase de crescimento.

DESCRITORES: Glutamina. Aminoácido. Nutrição enteral.

REFERENCES

1. BERGSTRON J, FURST P, NORÉEL-O et al. - Intracellular free amino acid concentration in human muscle tissue. **J Appl Physiol** 1974; **36**:693-697.
2. ELIA M - The inter-organ flux of substrates in fed and fasted man as indicated by arterio-venous balance studies. **Nutr Res Rev** 1991; **4**:3-31.
3. SOUBA WW, SMITH RJ & WILMORE DW - Glutamine metabolism by the intestinal tract: invited review. **J Parent Ent Nutr** 1985; **9**:608-617.
4. SOUBA WW & WILMORE DW - Postoperative alterations of arteriovenous exchange of amino acids across the gastrointestinal tract. **Surgery** 1983; **94**:342-350.
5. SOUBA WW, SMITH RJ & WILMORE DW - Effects of glucocorticoids on glutamine concentrations in visceral organs. **Metabolism** 1985; **34**:450-456.
6. SOUBA WW, HERSCOWITZ K, KLIMBERG S et al. - The effects of sepsis and endotoxemia on gut glutamine metabolism. **Ann Surg** 1990; **211**:543-549.
7. SALLOUM RM, COPELAND EM & SOUBA WW - Brush border transport of glutamine and other substrates during sepsis and endotoxemia. **Ann Surg** 1991; **213**:401-410.
8. ARDAWI MSM, ABDULRAHMAN J, ASHY A et al. - Glucose and glutamine metabolism in the small intestine of septic rats. **J Lab Clin Med** 1990; **115**:660-668.

9. SOUBA WW, KLIMBERG S & PLUMLEY DA - The role of glutamine in maintaining a healthy gut and supporting the metabolic response to injury and infection. **J Surg Res** 1990; **43**:383-391.
10. WILMORE DW, SMITH RJ, O'DWYER ST et al.- The gut: a central organ after surgical stress. **Surgery** 1988; **104**:917-923.
11. COFFEY JÁ, MILHOAN RA, ADULLAH A et al. - Bonbesin inhibits bacterial translocation from the gut in burned rats. **Surg Forum** 1988; **39**:109-110
12. JONES WG, MINEI JP, BARBER AE et al. - Bacterial translocation and intestinal atrophy after thermal injury and burn wound sepsis. **Ann Surg** 1990; **211**:399-405.
13. TRAN TA, MACRY J, MEDY F et al. - The effect of acute phase inflammation small intestinal morphology and function in the rat. **Clin Nutr** 1991; **10**:56-62.
14. WANG XD, JACOBS DO, O'DWYER ST et al. - Glutamine-enriched parenteral nutrition prevents mucosal atrophy following small bowel resection. **Surg Forum** 1988; **39**:44-46
15. FRANKEL WL, ZHANG W, ALFONSO J et al. - Glutamine enhancement of structure and function in transplanted small intestine in the rat. **J Parent Ent Nutr** 1983; **17**:47-45.
16. KLIMBERG VS, SOUBA WW, DOLSON DJ et al. - Prophylactic glutamine protects the intestinal mucosa from radiation injury. **Cancer** 1990; **66**:62-68.
17. WIRÉN M, SKULLMAN S, WANG F et al. - Intraluminal glutamine refeeding supports mucosal growth in rat jejunum. **Transpl Proc** 1994; **26**:1460-1463.
18. BLIKSLAGER AT, RHOADS JM, BRISTOL DG et al. - Glutamine and transforming growth factor-alpha stimulate extracellular regulated kinases and enhance recovery of villous surface area in porcine ischemic-injured intestine. **Surgery** 1999; **125**:186-194.
19. O'DWYER ST, SCOTT T, SMITH RJ et al. - 5-fluorouracil toxicity on small intestine mucosa but not white blood cells is decreased by glutamine. **Clin Res** 1987; **35**:369A
20. NUÑEZ MC, AYUDARTE MV, MORALES D et al. - Effect of dietary nucleotides on intestinal repair in rats with experimental chronic diarrhea. **J Parent Ent Nutr** 1985; **14**:598-604
21. BUCHMAN AL - Glutamine: Is it a conditionally required nutrient for the human gastrointestinal system? **J Am Coll Surg** 1996; **15**:199-205.
22. CZERNICHOW B, GALLUSER M, HASSELMANN M et al. - Effect of amino acids in mixtures given by enteral or parenteral route on intestinal morphology and hydrolases in rats. **J Parent Ent Nutr** 1992; **16**:259-263.
23. BLOMVIK BI, HAMMARQVIST F, VON DER DECKEN A et al. - Glutamine and alfa ketoglutarate attenuate the fall in muscle free glutamine concentration after total hip replacement. **Clin Nutr (supp)** 1993; **12**:12-13
24. ZIEGLER TR, ALMAHFOUZ A, PEDRINI MT et al. - A comparison of rat small intestinal insulin and insulin-like growth factor I receptors during enteral refeeding. **Endocrinology** 1995; **136**:5148-5154.
25. ESTIVARIZ CF, JONAS CR, GU LH et al. - Gut-trophic effects of keratinocyte growth factor in rat small intestine and colon during enteral refeeding. **J Parent Ent Nutr** 1998; **22**:259-267.
26. STEINER M, BOURGES HR, FREEMAN LS et al. - Effect of starvation on the tissue composition of the small intestine in the rat. **Am J Physiol** 1968; **269**:C385-391.
27. GOODLAD RA & WRIGHT NA - The effects of starvation and refeeding on intestinal cell proliferation in the mouse. **Virchows Archiv B Cell Pathol** 1984; **45**:63-73
28. HAGEMANN RF & STRAGAND JJ - Fasting and refeeding: cell kinetic response of jejunum ileum and colon. **Cell Tissue Kinet** 1977; **10**:3-14.
29. CHEN K, OKUMA T, OKAMURA K et al.- Glutamine-supplemented parenteral nutrition improves gut mucosa integrity and function in endotoxemic rats. **J Parent Ent Nutr** 1994; **18**:167-171.
30. WINDMUELLER HG - Glutamine utilization by the small intestine. **Adv Enzymol** 1982; **53**:201-237.
31. BLAAUV I, DEUTZ NEP, VAN DER HULST RRWW et al. - Glutamine depletion and increased gut permeability in nonanorectic, non-weight-losing tumor-bearing rats. **Gastroenterology** 1997; **112**: 1218-1226.

Received for publication on the 26/05/00