

## CASE REPORT

# PARACOCCIDIOIDOMYCOSIS: INFILTRATED, SARCOID-LIKE CUTANEOUS LESIONS MISINTERPRETED AS TUBERCULOID LEPROSY

Silvio Alencar MARQUES(1), Joel Carlos LASTÓRIA(1), Maria Stella de M.A. PUTINATTI(1), Rosangela Maria Pires de CAMARGO(1) & Mariangela E. A. MARQUES(2)

### SUMMARY

The authors report a case of paracoccidioidomycosis misinterpreted as tuberculoid leprosy, both on clinical and histological examination. Sarcoid-like cutaneous lesion as the initial presentation is rare in young patient with paracoccidioidomycosis and can simulate other infectious or inflammatory diseases. On histology, tuberculoid granuloma presented similar difficulties. Treatment with dapsone, a sulfonamide derivative, could have delayed the presumed natural clinical course to the classical juvenile type of paracoccidioidomycosis, observed only 24 months after the patient had been treated for leprosy.

**KEYWORDS:** Granuloma/Pathology; Leprosy; Paracoccidioidomycosis; Sarcoid Lesion.

### INTRODUCTION

Paracoccidioidomycosis (PCM) is the most prevalent systemic mycosis in immunocompetent individual in Brazil. The etiologic agent, *Paracoccidioides brasiliensis*, usually infects the patient through inhalation of airborne propagules, the lungs being the portal of entry. The infection may: i- regress with the destruction of fungi and formation of sterile scars, ii- regress with the persistence of viable fungi, in latent foci, with possible evolution to clinical disease or, iii- progress to overt disease<sup>7</sup>. The possible clinical expression of PCM-disease has been classified as: 1- *acute-subacute* form, which is the prevalent clinical form in the young and characterized by tropism of the fungus to the reticuloendothelial system and, 2- *chronic* form, most prevalent in adults presenting progressive pulmonary or extra-pulmonary manifestations<sup>5</sup>. Cutaneous lesions in PCM are reported to occur from 30 to up to 54% of the patients<sup>6</sup>. When present the skin lesion may originate from a preexisting contiguous one, usually from a neighboring mucosa; from the hematogenous dissemination of the fungus; or rarely, from the direct inoculation of the *P. brasiliensis* into the skin<sup>3,6</sup>. The face is the most common site of skin lesions and ulcer or ulcerous-vegetative lesions are the commonest morphological type followed by the infiltrative pattern<sup>6</sup>.

Leprosy (Hansen's disease) is still a prevalent cutaneous-neurological disease in Brazil<sup>1</sup>. The tuberculoid type of leprosy can be represented as a chronic, infiltrated skin lesion, erythematous or violaceous in appearance, with sharp limits, localized on any region

including the face. In tuberculoid leprosy the cell-mediated immune response is so strongly expressed that the infection is restricted to few skin sites and peripheral nerves. The histological picture displays a tuberculoid granuloma and acid-fast bacilli are rarely seen<sup>1,4</sup>. Clinical and histopathological misinterpretation may occur due to similarities among cutaneous sarcoidosis, infiltrative-sarcoid-type PCM and the tuberculoid leprosy<sup>9</sup>.

### CASE REPORT

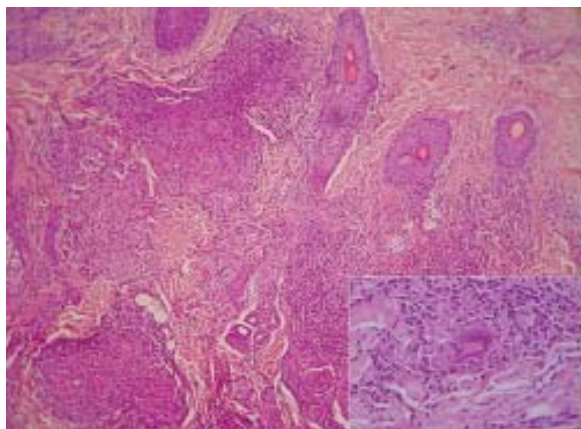
A 19-year-old student female, from Assis-SP, was hospitalized for investigation of an acute, febrile, cutaneous and systemic disease, referred as drug reaction as the possible etiology. She had been followed in her own town for one and half year due to skin lesions compatible, on clinical and histological examination, with tuberculoid leprosy (Fig. 1). At that time, she was given dapsone, 100 mg daily and rifampicin 600 mg, monthly supervised, as a paucibacillary multidrug therapy schedule. Six months after the initial treatment she was given the same regimen as the ancient lesions were still present. Few months later, as there was no improvement, her treatment was changed to that recommended for multibacillary leprosy with addition of clofazimine 300 mg on a daily basis, plus a monthly controlled dose clofazimine (300 mg). Her diagnosis was then challenged, but the hypothesis of leprosy prevailed. She was admitted weeks later, with fever, malaise, abdominal pain, weight loss and lymph node hypertrophy.

On physical examination infiltrated, sarcoid-type, erythematous,

(1) Departamento de Dermatologia e Radioterapia. Faculdade de Medicina de Botucatu, Universidade Estadual Paulista, UNESP, Botucatu, SP, Brasil.

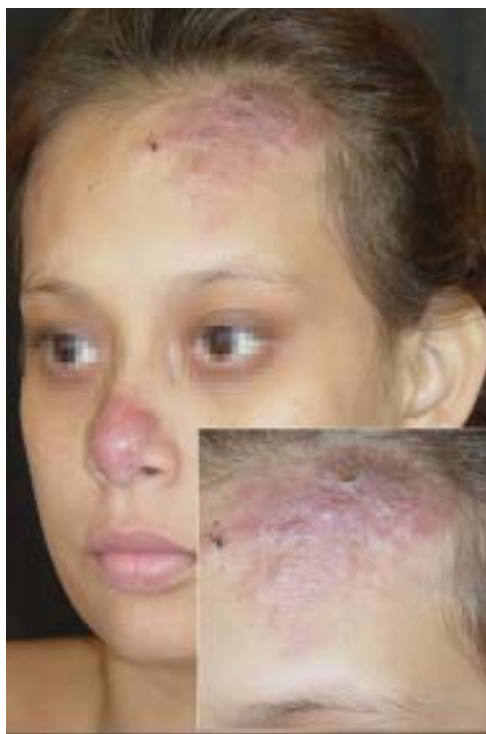(2) Departamento de Patologia. Faculdade de Medicina de Botucatu, Universidade Estadual Paulista, UNESP, Botucatu, SP, Brasil.

**Correspondence to:** Prof. Silvio Alencar Marques, Dep. Dermatologia e Radioterapia, Faculdade de Medicina/UNESP, Campus de Botucatu, 18618-000 Botucatu, SP, Brasil. E-mail: smarques@fmb.unesp.br

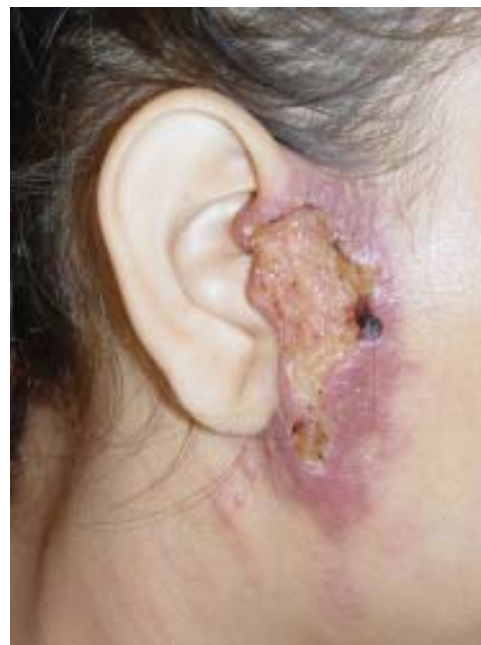

**Fig. 1** - The skin biopsy taken at the first appointment showed a compact granulomatous inflammatory infiltrate. Around the granuloma the lymphocytes are arranged as a dense infiltrate. (HE: 100X). A giant-cell inside the granuloma is showed in close-up. (HE: X 200).

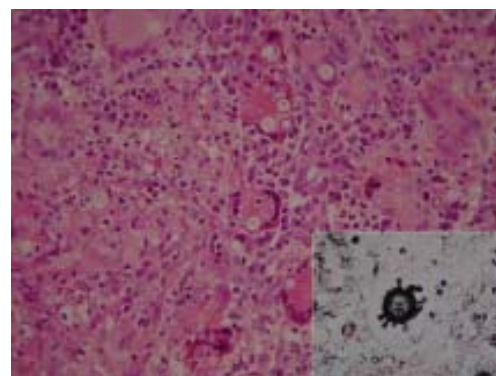
plaque lesions were observed on the skin of her face (Fig. 2). An ulcer with infiltrative edge was present on the pre-auricular region (Fig. 3). Lymph node hypertrophy with involvement of the cervical, submandibular, supraclavicular and axillary chains as well as liver and spleen enlargement were also detected. The lymph nodes were coalescent, tender on examination and without inflammatory signals. Laboratorial investigation revealed the following results: hemoglobin, 7.6 g/dL (normal range: 14-16 g/dL); hematocrit 23.2% (38-47%); eosinophil  $0.5 \times 10^3/\mu\text{L}$  ( $0-0.4 \times 10^3/\mu\text{L}$ ), erythrocyte sedimentation rate, 135 mm/h (1-10 mm/h); hypoalbuminemia, 1.6 g/dL (3.5-5.0



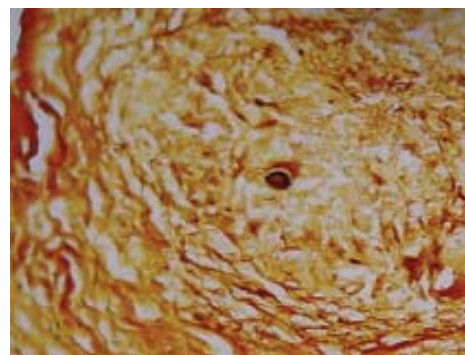
**Fig. 2** - Erythematous and violaceous infiltrative, sarcoid-like, lesions were observed on the face. Close-up of the frontal lesion shows erosions recovered by scales and crusting.



**Fig. 3** - An ulcer 5 x 3 cm wide with infiltrative edge was observed as an evolution from a sarcoid lesion.



**Fig. 4** - Paracoccidioidomycosis: multiple fungi are observed free on the stroma or engulfed by giant cells. (100 X HE). A typical *P. brasiliensis* budding yeast cell is presented in close-up. (Silver Methenamine: X 200).



**Fig. 5** - Paracoccidioidomycosis: a solitary fungal cell is demonstrated when reviewing the same sample took at the time of the first appointment. (Silver Methenamine: X 100).

g/dL); alkaline phosphatase 329 units/L (38-126 U/L); gamma-glutamyltransferase, 235 U/L (12-43 U/L). The investigation for HIV-1 and HIV-2 (ELISA), HBV (AgHBe, AgHBs, anti-HBe, anti-HBs, anti-HBc, anti-HBcIgM) and HCV (anti-HCV)-infection were all negative. High serum titers of antibodies anti-*P.brasiliensis* were detected by ELISA (1/12800) and double immunodiffusion test (1/32) (reference value = negative). Abdominal computerized tomography scanning showed homogeneous hepatosplenomegaly, multiple adenopathy (at the hepatic hilus, periaorta and mesenteric chains) and ascites. The direct search for fungal elements, and histopathological examination of skin biopsy showed the classical image of *P. brasiliensis* (Fig. 4) which quickly defined the diagnosis of paracoccidioidomycosis, presented as a severe *subacute* clinical form<sup>5,9</sup>. No acid-fast bacilli were visualized on biopsy specimens or in a Ziehl-Neelsen staining of slit-skin smears. A careful reevaluation of the slides of her first biopsy, which had been taken two years before in her town, using silver-methenamine stain, allowed the identification of *P. brasiliensis* (Fig. 5). Therefore, the diagnosis was paracoccidioidomycosis since the beginning, in a previously healthy patient, with only sporadic incursion to rural area, displaying an uncommon clinical and histopathological aspect which should be called as sarcoid-type paracoccidioidomycosis. The patient was initially treated with itraconazole, 400 mg/day with partial response followed by Amphotericin B, 2000 mg of total dose plus sulphamethoxazole-trimethoprim, 2400 mg/day, of sulphamethoxazole on outpatient basis with clinical improvement.

## DISCUSSION

Reviews of cutaneous manifestations in paracoccidioidomycosis have shown that the infiltrative pattern corresponded to up to 26.6% of the skin lesions observed, which included the sarcoid-type<sup>6</sup>. Usually, patients of any age presenting this clinical pattern have few and indolent lesions, probably as consequence of a certain equilibrium between agent and host defense. However, this equilibrium could be disturbed at some point in the natural course of the disease and it would be no surprising the late appearance of a typical clinical picture of the PCM, such as lymph node hypertrophy and manifestations of systemic disease, as observed in the present case. The reasons why the evolution is initially so indolent and the equilibrium is preserved for so long in patients bearing the *subacute* clinical form remain unclear. We could speculate, in this case, that dapsone (4, 4'-diamino-diphenyl sulfone), a drug structurally similar to sulfonamides, could have partially acted therapeutically and, for some time, delayed the natural course of the infection. In another very similar case (our unpublished data), a 16 year-old patient initially diagnosed as tuberculoid leprosy received dapsone as the only drug for almost two years and later her clinical picture was still of few skin lesions and few lymph nodes with mild hypertrophy on clinical examination. In both cases the clinical appearance was coherent with the histological picture of a tuberculoid granuloma, consistent with tuberculoid leprosy. However, in both cases the review of histological slides, using silver stain, allowed the correct diagnosis of paracoccidioidomycosis since the very beginning.

In a country where leprosy is still a public health problem and the primary care physician is instructed to be alert to that disease, the mistake here reported could be understood as acceptable at the first moment. This chance of misinterpretation of the presence of sarcoid-like lesions associated with a tuberculoid granuloma had already been

discussed. PROENÇA *et al.* (1984)<sup>10</sup> studied 10 patients firstly interpreted as presenting cutaneous sarcoidosis and when reviewed two to five years later, three were proven to be leprosy and one to be paracoccidioidomycosis. These observations reinforce the clinical and histological similarities among these diseases at an early stage. However, the persistence of lesions after the correct scheduled leprosy treatment, the change of an infiltrative lesion to an ulcerous one could be understood as an alert signal to review the initial diagnosis. Tuberculoid leprosy usually takes months, and not years, to respond to the correct treatment, and this should have been taken into account. During the late course of the disease, the appearance of constitutional symptoms plus signals of systemic compromise as lymph node hypertrophy and hepatosplenomegaly were interpreted as a severe drug reaction (a drug-hypersensitivity syndrome) caused by rifampicin or dapsone<sup>2</sup>, or as an atypical type 1 leprosy reaction. The first hypothesis, drug reaction with eosinophilia and systemic symptoms, a drug-hypersensitivity syndrome nowadays known by the acronym, DRESS usually develops two to six weeks after starting the medication, most commonly phenytoin, carbamazepine, phenobarbital or sulfonamides and presents fever, facial edema and cutaneous rash<sup>11,13</sup>. Except for dapsone as the suspected drug, the others have not been taken. Dapsone had been used for many months and there were not new skin lesions, facial edema or a morbiliform eruption to support that hypothesis. Type 1 reaction is associated with borderline leprosy and characterized by acute neuritis, face, hands or feet edema, swelling and tenderness of previous existing skin lesions and/or the appearance of new skin lesions without constitutional symptoms<sup>8</sup>, therefore this hypothesis could have also been ruled out at the beginning of the observation.

Histological diagnosis of granulomatous infectious diseases will be accurate when there are characteristic histological features or sufficient number of infectious agents to be detected by histochemistry. Therefore, the presence of compact epithelioid granulomas, with a central caseous necrosis and dense peripheral lymphocytic accumulation indicates tuberculosis<sup>14</sup>. Granuloma with nerve involvement suggests tuberculoid leprosy but, in lepromatous leprosy the finding will be of a diffuse infiltration with numerous leprotic bacilli<sup>14</sup>. Mixed granulomatous and suppurative inflammation with lymphocytes, plasma cells and occasional eosinophils are classically seen on deep and subcutaneous mycosis. On the other hand, the noncaseating granulomas of epithelioid cells with pale-staining nuclei and a rim of few number of lymphoid cells surrounding the granuloma, the naked tubercle, is suggestive of sarcoidosis<sup>12</sup>. However, the classical pattern is not always present and can be altered by individual response such as immunosuppression or hypersensitivity to a specific agent. In order to allow more accurate diagnosis of epithelioid granulomas, including those observed in sarcoidosis, it is recommended not only to stain slides with histochemistry methods, to highlight fungi and acid fast bacilli, but also promote clinical-histologic correlation and, when necessary, use ancillary techniques such as immunohistochemistry and PCR<sup>12,14</sup>.

In conclusion, this case report illustrates how difficult it is to interpret infiltrative, sarcoid-type skin lesion and its counterpart, the tuberculoid granuloma, particularly, in an endemic region with high prevalence of infectious diseases which have similar clinical and histological presentations.

## RESUMO

### **Paracoccidioidomicose: lesões cutâneas, infiltrativas, sarcoidose-símile, diagnosticadas como Hanseníase tuberculóide**

Os Autores relatam um caso de paracoccidioidomicose diagnosticado como se fora Hanseníase tuberculóide, tanto do ponto de vista clínico como histopatológico. Lesão cutânea de padrão sarcóidico é raramente observada como lesão inicial da paracoccidioidomicose em jovens e pode simular outras dermatoses infecciosas ou inflamatórias. O achado histológico de granuloma tuberculóide apresenta dificuldade diagnóstica similar. O tratamento realizado com dapsone, um derivado sulfamídico, pode ter retardado a evolução clínica esperada para o padrão clássico da paracoccidioidomicose tipo juvenil, o qual apenas se materializou 24 meses após a paciente ter iniciado tratamento como Hanseníase.

## REFERENCES

1. ARAUJO, M.G. - Hanseníase no Brasil. **Rev. Soc. bras. Med. trop.**, 36: 373-382, 2003.
2. BUCARETCHI, F.; VICENTE, D.C.; PEREIRA, R.M. & TRESOLDI, A.T. - Dapsone hypersensitivity syndrome in an adolescent during treatment of leprosy. **Rev. Inst. Med. trop. S. Paulo**, 46: 331-334, 2004.
3. CASTRO, R.M.; CUCÉ, L.C. & FAVA-NETTO, C. - Paracoccidioidomicose: inoculação acidental "in anima nobile". Relato de um caso. **Med. cut. ibero lat.-amer.**, 4: 289-292, 1975.
4. FOSS, N.T. - Hanseníase: aspectos clínicos, imunológicos e terapêuticos. **An. bras. Derm.**, 74: 113-119, 1999.
5. FRANCO, M.; MONTENEGRO, M.R.; MENDES, R.P. *et al.* - Paracoccidioidomycosis: a recently proposed classification of its clinical forms. **Rev. Soc. bras. Med. trop.**, 20: 129-132, 1987.
6. MARQUES, S.A. - Cutaneous lesions. In: FRANCO, M.; LACAZ, C.S.; RESTREPO-MORENO, A. & DEL-NEGRO, G., ed. **Paracoccidioidomycosis**. Boca Raton, CRC Press, 1994. p. 259-266.
7. MONTENEGRO, M.R. & FRANCO, M. - Pathology. In: FRANCO, M.; LACAZ, C.S.; RESTREPO-MORENO, A. & DEL-NEGRO, G., ed. **Paracoccidioidomycosis**. Boca Raton, CRC Press, 1994. p. 131-150.
8. NERY, J.A.C.; VIEIRA, L.M.M.; MATOS H.J.; GALLO, M.E.N. & SARNO, E.N. - Reactional states in multibacillary Hansen disease patients during multidrug therapy. **Rev. Inst. Med. trop. S. Paulo**, 40: 363-370, 1998.
9. PEREIRA, R.M.; BUCARETCHI, F.; BARISON, E.M.; HESSEL, G. & TRESOLDI, A.T. - Paracoccidioidomycosis in children: clinical presentation, follow-up and outcome. **Rev. Inst. Med. trop. S. Paulo**, 46: 127-131, 2004.
10. PROENÇA, N.G.; PEDROZO B.R.; MULLER, H. & KLIEMAUNT, T.A. - Dificuldades para diagnóstico de sarcoidose exclusivamente cutânea. **Rev. Ass. méd. bras.**, 30: 101-104, 1984.
11. PRUSSICK, R. & SHEAR, N.H. - Dapsone hypersensitivity syndrome. **J. Amer. Acad. Derm.**, 35: 346-349, 1996.
12. REICH, J.M. - What is sarcoidosis? **Chest**, 124: 367-371, 2003.
13. TAS, S. & SIMONART, T. - Management of drug rash with eosinophilia and systemic symptoms (DRESS syndrome): an update. **Dermatology**, 206: 353-356, 2003.
14. ZUMLA, A. & JAMES, D.G. - Granulomatous infections: etiology and classification. **Clin. infect. Dis.**, 23: 146-158, 1996.

Received: 4 May 2007

Accepted: 30 August 2007