

RENAL INVOLVEMENT IN PROLONGED SALMONELLA BACTEREMIA: THE ROLE OF SCHISTOSOMAL GLOMERULOPATHY

Reinaldo MARTINELLI (1), Luis José Cardoso PEREIRA (1), Edilson BRITO (2) & Heonir ROCHA (1)

SUMMARY

Renal involvement has been well documented in patients with hepatosplenic schistosomiasis and in patients with prolonged salmonella bacteremia (PSB). Whether there is a specific renal lesion related to PSB or the chronic bacterial infection aggravates a pre-existing schistosomal glomerulopathy has been a matter of controversy. To analyze the clinical manifestations and histopathological findings of the renal involvement, 8 patients with hepatosplenic schistosomiasis and PSB (group I) were compared with 8 patients with schistosomal glomerulopathy (group II) matched by sex and glomerular disease. The mean age in group I was 17.7 years. All patients presented with hematuria, in 4 cases associated with non-nephrotic proteinuria. In group II the mean age was 23 years; nephrotic syndrome was the clinical presentation in 7 of the 8 patients in the group. All patients in group I experienced remission of the clinical and laboratory abnormalities as the salmonella infection was cured; in group II the patients had persistent, steroid-resistant, nephrotic syndrome. On histological examination, no difference was noted between the two groups, except for pronounced glomerular hypercellularity and interstitial mononuclear cell infiltration in group I. These observations strongly suggest that PSB exacerbates a pre-existing sub-clinical schistosomal glomerulopathy by the addition of active lesions directly related to the prolonged bacteremia.

KEY WORDS: Schistosomiasis mansoni; Prolonged salmonella bacteremia; Glomerulonephritis; Clinical manifestations; Histopathology.

INTRODUCTION

A superimposed salmonella infection in patients with hepatosplenic schistosomiasis mansoni can result in chronic bacteremia characterized by prolonged fever, weight loss and hypoalbuminemia; renal involvement has been reported in 60% of these patients^{15, 19}. The immuno-

logical pathogenesis for the glomerular involvement in patients with hepatosplenic schistosomiasis and prolonged salmonella bacteremia infection has been established^{5, 10, 12}. Whether there is a specific renal lesion related to the prolonged salmonella bacteremia or whether the chronic

This study was supported by Conselho Nacional de Desenvolvimento Científico e Tecnológico — CNPq (Grant 400507/88-89)

Departamentos de Medicina (1) e Patologia (2) — Faculdade de Medicina, Universidade Federal da Bahia — Salvador, Bahia, Brasil.

Address for correspondence: Reinaldo Martinelli; Hospital Universitário Prof. Edgard Santos, Laboratório 1117 — Nefrologia; Rua João das Botas, s/n — Canela, 40140 Salvador — Bahia — Brasil

bacterial infections aggravates a pre-existing schistosomal mansoni glomerulopathy, has been a matter of controversy.

CARVALHO et al⁴, studying the renal involvement in patients with hepatosplenic schistosomiasis and chronic salmonella bacteremia, reported the findings of renal biopsies in 9 patients: mesangiocapillary glomerulonephritis was diagnosed in 5, focal segmental glomerulosclerosis in 2, mesangial proliferative glomerulonephritis in 1 and minimal histologic changes in one. The pattern of glomerular involvement observed was similar to that reported in schistosomal glomerulopathy², and the authors concluded that the salmonella infection aggravated the schistosomal mansoni glomerulopathy. LAMBERTUCCI¹¹ and GODOY⁹, however, in prospective, clinical and histological studies, found evidence for the existence of a distinct glomerulopathy, directly related to the salmonella infection and different from the schistosomal glomerulopathy. LAMBERTUCCI et al¹² also reported the presence of salmonella antigens, immunoglobulins and C3 in the glomeruli of 3 patients with hepatosplenic schistosomiasis and chronic salmonella bacteremia. Clinical and histological resolution followed treatment of the salmonella infection, and the authors conclude in favor of a direct role for salmonella in the pathogenesis of the glomerulopathy in this chronic infectious disease. It should be emphasized, however, that in these studies a search for glomerular deposition of *S. mansoni* antigens was not performed, and that schistosomal glomerulopathy has been well demonstrated in asymptomatic patients^{14, 17, 18}.

The purpose of the present study was to analyze the clinical manifestations and histopathological findings of the renal involvement in patients with hepatosplenic schistosomiasis and prolonged salmonella bacteremia, and to compare these findings with those observed in patients with schistosomal mansoni glomerulopathy, matched by sex and glomerular disease, in order to elucidate the role of the bacterial infection in the pathogenesis of prolonged salmonella bacteremia-associated glomerulonephritis.

MATERIALS AND METHODS

A total of 16 patients were included in the present study. The clinical manifestations and

renal histological findings of patients with the diagnosis of prolonged salmonella bacteremia (Group I) were analysed and compared with those of patients with hepatosplenic schistosomiasis mansoni and glomerulonephritis (Group II) matched by sex and glomerular disease. As our patients with prolonged salmonella bacteremia tended to be younger, we selected patients with schistosomal nephropathy in such a way that the mean age in the two groups were similar.

At the time of initial evaluation, a detailed history was obtained and physical examination was performed. Clinical presentation, evidence of systemic or multiple system disease which could be related to the renal disease as well as evidence of recent streptococcal infection, were recorded. Laboratory evaluation included serum levels of urea nitrogen, creatinine, albumin and cholesterol.

Schistosomiasis mansoni was diagnosed by the demonstration of viable eggs of *S. mansoni* in stools. All patients had, on physical examination, an enlarged and firm liver with an irregular surface and prominent left lobe as well as a greatly enlarged spleen. Prolonged salmonella bacteremia (PSB) was diagnosed by documenting prolonged fever (>4 weeks) along with blood cultures positive for salmonella, in patients with hepatosplenic schistosomiasis.

For the purpose of the present study, nephrotic syndrome was diagnosed by the presence of edema, urinary protein excretion greater than 3.5 g/24 hs and serum albumin levels below 3.0 g/dl. Non-nephrotic proteinuria was defined as urinary protein excretion below 3.5 g/24 hs; microscopic hematuria by the finding of more than 5 red blood cell per high power field on examination of urinary sediment. Renal failure was defined by a serum creatinine level greater than 1.4 mg/dl and/or blood urea nitrogen exceeding 25 mg/dl. Arterial hypertension was defined as blood pressure levels above 140/95 mmHg.

All patients underwent percutaneous renal biopsy as part of the evaluation of the renal disease. The specimens were fixed in Bouin's solution, processed by routine techniques, and section of 2 μ m thickness containing at least 8 glomeruli were stained with hematoxylin and eosin, PAS, PAS-silver methanamine and Heide-

nhain's stain for connective tissue (AZAN) and read blindly by a renal pathologist using the criteria of CHURG et al⁶.

The clinical course of each patient was evaluated by following blood pressure, serum levels of creatinine, BUN and albumin, urinalysis, and by recording the use of medications. An illustrative case of a patient with hepatosplenic schistosomiasis and prolonged salmonella bacteremia is herein presented.

CASE REPORT

A 30 year-old male was admitted to Hospital Universitário Prof. Edgard Santos — UFBA, with a history of fever of unknown etiology. At admission the blood pressure was 90/60 mmHg and the pulse rate 90/min; there was hepatosplenomegaly and mild ankle edema. Laboratory evaluation showed 200 mg/dl proteinuria and microscopic hematuria; viable eggs of *S. mansoni* were identified on stool examination. The serum creatinine was 2.1 mg/dl and BUN was 40 mg/dl. Blood and urine cultures were positive for *S. typhi*. Pronounced and rapid clinical improvement was seen upon treatment with chloramphenicol and oxamniquine. During the hospitalization a percutaneous renal biopsy was performed diagnosing focal segmental glomerulosclerosis. The patient was discharged with normal urinalysis, BUN, and serum creatinine, and negative blood, urine and stool cultures.

One year later the patient was well, the physical examination revealed hepatosplenomegaly and laboratory evaluation was normal. Eight years later, arterial hypertension was diagnosed, and at that time, non-nephrotic range proteinuria and persistent abnormal serum creatinine (2,1 mg/dl) were first recorded. Over the next 12 years, the patient's blood pressure remained well controlled, however, persisting non-nephrotic proteinuria and mild, although progressive, renal insufficiency, were noted.

RESULTS

Of the 16 patients, 8 had the diagnosis of chronic salmonella bacteremia and 8 had hepatosplenic schistosomiasis. Each group consisted of 5 male and 3 female patients. The mean ages were 17.7 years in group I and 23.0 years in group II.

Clinical manifestations — hematuria was the most frequent clinical manifestation of renal disease in group I and was recorded in all patients in this group; in two it was macroscopic. In 4 patients the hematuria was associated with non-nephrotic proteinuria. In group II, nephrotic syndrome was the most frequent clinical manifestation of renal disease, occurring in 7 patients, followed by abnormalities of urinalysis (non-nephrotic proteinuria and microscopic hematuria). Red blood cells casts were not detected in any of the 16 patients. One patient in group I and two in group II had arterial hypertension, and one patient in each group had mild renal failure at the time of initial evaluation (Table 1).

After treatment with appropriate antibiotics and cure of the salmonella infection, the clinical and laboratory abnormalities in all patients in group I had resolved. The clinical course of the patients with schistosomal glomerulopathy, however, was characterized by a persistent, steroid-resistant nephrotic syndrome.

Renal pathology — the glomerular lesions found were mesangiocapillary glomerulonephritis in 5 patients, mesangial proliferative glomerulonephritis in 2 and focal segmental glomerulosclerosis in 1 patient. On histological examination, there were no specific findings on light

Table 1
Clinical presentation of the renal involvement in patients with prolonged salmonella bacteremia and with schistosomal mansoni glomerulonephritis

	Group I	Group II
Microscopic hematuria	4	—
Proteinuria and microscopic hematuria	4	1
Nephrotic syndrome	—	7
.....		
Arterial hypertension	1	2
Renal insufficiency	1	1

TABLE 2
Glomerular pathology in patients with prolonged salmonella bacteremia and in patients with schistosomal glomerulonephritis

	Group I	Group II
Mesangiocapillary glomerulonephritis	5	5
Mesangial proliferative glomerulonephritis	2	2
Focal segmental glomerulosclerosis	1	1

microscopy that could differentiate between the groups (Table 2), although glomerular hypercellularity and interstitial mononuclear cell infiltration (Fig. 1) were more evident in patients with chronic salmonella bacteremia (Table 3).

DISCUSSION

In the present study we observed differences between the 2 groups of patients in age, initial presentation and clinical course. As has also been noted by LAMBERTUCCI¹¹, the mean age

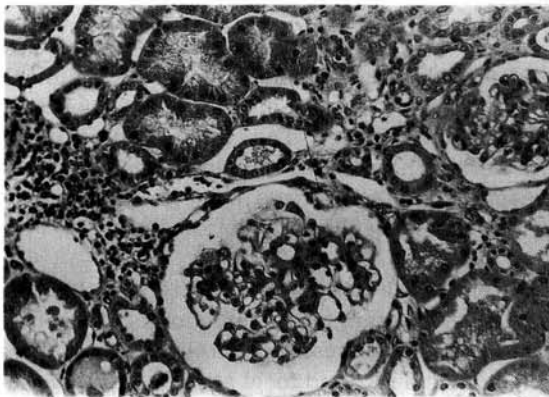


Fig. 1 — Focal segmental glomerulosclerosis (patient with prolonged salmonella bacteremia). Glomerular hypercellularity, collapse of capillary loops, sclerotic mesangial matrix and adhesion to Bowman's capsule. Interstitial mononuclear cells infiltration. PAS 200x.

TABLE 3
Renal histopathological findings in patients with prolonged salmonella bacteremia and in patients with schistosomal glomerulonephritis

	Group I	Group II
Glomerular changes		
hypercellularity	++++	+++
mesangial matrix increase	+++	++++
splitting of the glomerular basement membrane	++++	+++
focal segmental sclerosis	++	++
subendothelial deposits	++	++
crenated	+	++
Tubular changes		
atrophic tubules	+	++
hyaline and granular casts	++	+++
Interstitial changes:		
mononuclear cells infiltrates	+++	++
fibrosis	++	+++
Vasculopathy (endoarterites)	+++	++

of patients with prolonged salmonella infection was lower than patients with schistosomal glomerulonephritis: this finding was not unexpected since the influence of the duration of the *S. mansoni* infection on the clinical manifestation of the glomerulopathy is well recognized^{7, 8, 13}. Hematuria, suggesting more acute disease, was the clinical presentation of renal disease in patients with chronic salmonella bacteremia, in contrast with nephrotic syndrome which was the most frequent manifestation of schistosomal glomerulopathy. In addition, upon light microscopic examination no differences could be found between the two groups. Furthermore, the pattern of glomerular lesions in patients with prolonged salmonella bacteremia was very similar to that reported in patients with schistosomal mansoni glomerulopathy². These data, taken together, strongly suggest an important pathogenic role for schistosomal glomerulopathy in the renal involvement in prolonged salmonella bacteremia. It is conceivable that the concurrent salmonella infection in patients with hepatosplenic schistosomiasis could aggravate an early and clinically undetectable glomerulopathy, which could then revert to the silent stage after the eradication of the bacterial infection. The presented case report supports the notion of a pre-existing schistosomal glomerulopathy.

Diffuse proliferative glomerulonephritis as reported by others¹² was not observed in the present series. The reasons for this are not readily apparent; possible factors could include the severity and duration of the bacterial infection at the time of diagnosis, geographical differences or genetic factors.

The possibility of a specific glomerular lesion related to salmonella infection per se, however, can not be neglected: SITPRIJA et al¹⁶ demonstrated a specific immune complex-mediated glomerulitis in patients with typhoid fever. Although BASSILY et al³ could not find anti-salmonella antibodies in the glomeruli of patients with prolonged salmonella infection, LAMBERTUCCI et al¹² demonstrated salmonella antigens, immunoglobulins and C3 in the glomeruli of all 3 patients studied and these changes resolved after treatment of the bacterial infection. Although the role of salmonella infection in the glomerular disease of patients with salmonella — schistosomiasis mansoni infection is well established, a

specific salmonella glomerulopathy remains to be confirmed. A pre-existing early schistosomal glomerulopathy has never been convincingly ruled out in patients with prolonged salmonella infection. *S. mansoni* antigens have been demonstrated in the glomeruli of infected patients, even in the early stage of the disease, in the absence of clinical manifestations of renal involvement^{17, 18}.

In summary, the analysis of the clinical and histological findings suggest that in *S. mansoni* — salmonella infections, the prolonged salmonellosis exacerbates a latent schistosomal glomerulopathy.

RESUMO

Envolvimento renal na salmonelose septicêmica prolongada: papel da glomerulopatia esquistossomótica

Envolvimento renal tem sido documentado em pacientes com o diagnóstico de salmonelose septicêmica prolongada (SSP). Entretanto, ainda é controversa a existência de uma glomerulopatia especificamente relacionada a SSP ou se a infecção bacteriana prolongada agrava a glomerulopatia esquistossomótica pré-existente. Com o objetivo de analisar as manifestações clínicas e histológicas do envolvimento renal, 8 pacientes com o diagnóstico de SSP foram estudados e comparados com 8 pacientes portadores de glomerulopatia esquistossomótica, pareados por sexo e doença glomerular. A idade média dos pacientes com SSP foi de 17,7 anos; a manifestação clínica do envolvimento renal foi de hematuria, em todos, estando associada a proteinúria não nefrótica em 4 deles. Entre os pacientes com glomerulopatia esquistossomótica, a idade média foi de 23,0 anos e síndrome nefrótica foi a manifestação clínica da nefropatia em 7 dos 8 pacientes. Relacionada a cura de infecção pela salmonela, houve remissão completa com o diagnóstico de glomerulopatia esquistossomótica tiveram um curso caracterizado por síndrome nefrótica persistente, corticosteróide-resistente. Exceto pela hiperplasticidade glomerular e o infiltrado intersticial por células mononucleares, mais pronunciada entre os pacientes com SSP, não foram observadas diferenças na histologia renal entre os dois grupos de pacien-

tes. Os dados fortemente sugerem que a SSP exacerba a glomerulopatia esquistossomótica, clinicamente não manifesta, pela adição de lesões ativas, relacionadas a septicemia prolongada.

REFERENCES

1. ANDERSON, R. M. & MAY, R. M. — Population dynamics of human helminth infections: control by chemotherapy. *Nature*, 297: 557-563, 1982.
2. ANDRADE, Z. A. & ROCHA, H. — Schistosomal glomerulopathy. *Kidney Int.*, 16: 23-29, 1979.
3. BASSILY, S.; FARID, Z.; BARSDUM, R. S.; SOLIMAN, L. A.; HIGASHI, G. I. & MINER, W. F. — Renal biopsy in Schistosoma-Salmonella associated nephrotic syndrome. *Amer. J. trop. Med. Hyg.*, 79: 256-258, 1976.
4. CARVALHO FILHO, E.; BRITO, E.; GUSMÃO, E.; TEIXEIRA, R. S. & ROCHA, H. — Envolvimento renal na salmonelose septicêmica prolongada. *Rev. Soc. bras. Med. trop.*, 11: 175-180, 1977.
5. CARVALHO, E. M.; ANDREW, B. S.; MARTINELLI, R.; DUTRA, M. & HEONIR, H. — Circulating immune complexes and rheumatoid factor in schistosomiasis and visceral leishmaniasis. *Amer. J. trop. Med. Hyg.*, 32: 61-68, 1983.
6. CHURCH, J. & SOBIN, M. A. — *Renal disease: classification and atlas of glomerular disease*. Tokyo, Igaku-Shoin, 1982.
7. COUTINHO, A. — Fatores relacionados com o desenvolvimento das formas clínicas da esquistossomose mansônica. *Rev. Ass. med. bras.*, 25: 185-188, 1979.
8. ELSHEIKH, H.; DOEHRING-SCHWERDTFEGER, E.; KAISER, C.; ABDELRAHIM, J. M.; ALI, G. M.; FRA-NHE, D.; PARROTH, K.; KARDOFF, R. & EHRICH, J. H. H. — Renal function in sudanese school children with *Schistosoma mansoni* infection. *Pediat. Nephrol.*, 3: 259-264, 1989.
9. GODOY, P. — Glomerulonefrite da salmonelose septicêmica prolongada (SSP): Caracterização morfológica e posição nosológica. Belo Horizonte, 1986. (Tese — Faculdade de Medicina da Universidade Federal de Minas Gerais)
10. HIGASHI, G. I.; FARID, Z.; BASSILY, S. & MINER, W. F. — Nephrotic syndrome in schistosomiasis mansoni complicates by chronic salmonellosis. *Amer. J. trop. Med. Hyg.*, 24: 713-714, 1975.
11. LAMBERTUCCI, J. R. — Contribuição ao estudo das alterações renais na Salmonelose septicêmica prolongada. Belo Horizonte, 1984. (Tese — Faculdade de Medicina da Universidade Federal de Minas Gerais)
12. LAMBERTUCCI, J. R.; GODOY, P.; NEVES, J.; BAMBIRRA, E. A. & FERREIRA, M. D. — Glomerulonephritis in *Salmonella-Schistosoma mansoni* association. *Amer. J. trop. Med. Hyg.*, 38: 97-102, 1988.

13. MARTINELLI, R.; GUSMÃO, E.; BRITO, E. & ROCHA, H. — Aspectos da evolução clínica da glomerulopatia associada a esquistossomose mansônica. *J. bras. Nefrol.*, 1: 20-24, 1979.
14. MARTINELLI, R.; BRITO, E. & ROCHA, H. — Value of B1c globulin serum levels as an early index of glomerular involvement in *S. mansoni* infection. *Amer. J. trop. Med. Hyg.*, 29: 882-885, 1980.
15. NEVES, J. & MARTINS, N. R. L. — Long-duration of septicemic salmonellosis. Thirty-five cases with twelve implicated species of Salmonella. *Trans. roy. Soc. trop. Med. Hyg.*, 61: 541-552, 1967.
16. SITPTIJA, V.; PIPATANAGUL, V.; BOONPUCKNAV, G. V. & BOONPUCKNAVIG, S. — Glomerulitis in typhoid fever. *Ann. intern. Med.*, 81: 210-213, 1974.
17. SOBH, M. A.; MOUSTAFA, F. E.; SALLY, S. M.; DEELDER, A. M. & GHONIEM, M. A. — Characterization of kidney lesions in early schistosomal-specific nephropathy. *Nephrol. Dial. Transplant.*, 3: 392-398, 1988.
18. SOBH, M. A.; MOUSTAFA, F. E.; EL-ARBOGY, A.; SHEBAB ELDIN, M.; SHAMAA, A. & AMER, G. — Nephropathy in asymptomatic patients with active *Schistosoma mansoni* infection. *Int. Urol. Nephrol.*, 22: 37-43, 1990.
19. TEIXEIRA, R. — Typhoid fever of protracted course. *Rev. Inst. Med. trop. S. Paulo*, 2: 65-70, 1960.

Recebido para publicação em 23/8/1991.

Aceito para publicação em 7/4/1992.