

## CASE REPORT

### LEISHMANIASIS IN THE GENITAL AREA

Ismery CABELLO(1,2), Alejandro CARABALLO(2) & Yaneth MILLÁN(1)

---

#### SUMMARY

Two patients from the gold mines of Bolivar State, Venezuela, presenting cutaneous leishmaniasis in the genital region, an unusual location, are described. The first patient showed an ulcerated lesion of the glans penis. Leishmanin skin test was positive. A biopsy specimen revealed a granulomatous infiltrate containing *Leishmania* parasites. In the second patient, Leishmanin skin test was positive, HIV and VDRL were negative. *Leishmania* parasites were present in a biopsy of an ulcerated lesion in the scrotum, with an indurated base, infiltrative borders with a yellowish exudate. Patients were treated with meglumine antimoniate and the lesions healed.

**KEYWORDS:** Mucocutaneous leishmaniasis; Genital ulcers; Venezuela.

---

#### INTRODUCTION

Cutaneous Leishmaniasis is an infectious disease caused by protozoa of the gender *Leishmania*, transmitted by stings of female insects of the gender *Phlebotomus* in the Old World and *Lutzomyia* in the New World. More than twenty species of *Leishmania* pathogenic for humans and other mammals have been identified worldwide<sup>12</sup>.

The clinical manifestations of leishmaniasis depend on the interaction between the characteristic virulence of the species and the host's immune response<sup>11</sup>.

In America, cutaneous leishmaniasis caused by several species of the complex *brasiliensis* and *mexicana* are suggested<sup>5,7,8</sup>. We present 2 cases of cutaneous leishmaniasis in the genital area, a very unusual localization.

#### CASE REPORTS

**Case 1:** An 18-year-old gold mine worker from Parapapoy, Piar Municipality, Bolivar State, Venezuela, presented with a three-months history of an ulcerative lesion over the glans penis. The patient was treated with Penicillin intramuscularly (2.4 million IU).

The ulcer measured 1 cm in diameter, with an indurated base and raised, infiltrative borders (Fig. 1). No regional lymph nodes were noted. VDRL (Venereal Disease Research Laboratories) and FTA-ABS (Fluorescent Treponemal Antibody Absorption) was negative.

Montenegro's intradermal test was positive: indurated papule, 26 mm diameter. Histopathological study showed ulceration of epidermis and a diffuse inflammatory infiltrate in the dermis composed of lymphocytes, histiocytes, plasma cells and giant cells with granuloma formation and presence of *Leishmania* amastigotes (Fig. 2). The patient was treated with meglumine antimoniate intramuscular (20 mg of Sb+/kg/day) during three weeks; with fully healed lesion at the end of therapy.

**Case 2:** A man of 38 years from gold mines of Ikabaru, Gran Sabana Municipality of the Bolivar State, Venezuela, was suffering from a tumor in the scrotum for 5 months. The clinical diagnosis was squamous cell carcinoma. At physical examination, an ulcerated tumor of 5 cm x 3 cm in diameter, with an indurated base and raised, infiltrative borders with a yellowish exudate was noted (Fig. 3). Leishmanin skin test was positive, HIV (enzyme-linked immuno-sorbent assay [ELISA]), and VDRL were negative. Histology showed pseudoepitheliomatous hyperplasia, a necrotic area and ulceration of epidermis and a diffuse inflammatory infiltrate in the dermis composed of lymphocytes, plasma cells, polymorphonuclear cells and vacuolated histiocytes with the presence of *Leishmania* amastigotes (Fig. 4). The patient was treated with meglumine antimoniate intramuscular (20 mg of Sb+/kg/day) three weeks; with complete cicatrization of the lesion.

#### DISCUSSION

In the last years, an increment of the number of cutaneous leishmaniasis in the Bolivar State, Venezuela, have been observed<sup>6</sup>.

---

(1) Servicio de Dermatología, Complejo Hospitalario Universitario Ruiz y Páez, Ciudad Bolívar, Venezuela.

(2) Escuela de Medicina, Núcleo Bolívar, Universidad de Oriente, Ciudad Bolívar, Venezuela.

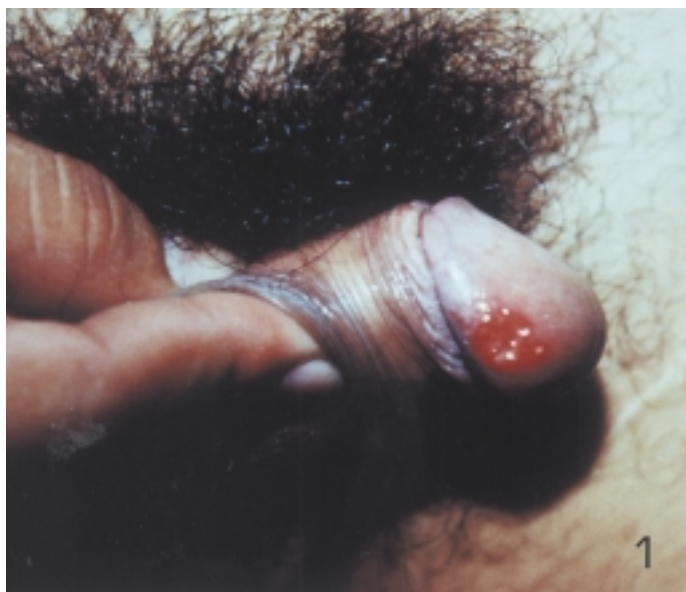

Fig. 1 - Ulcer of glans penis.

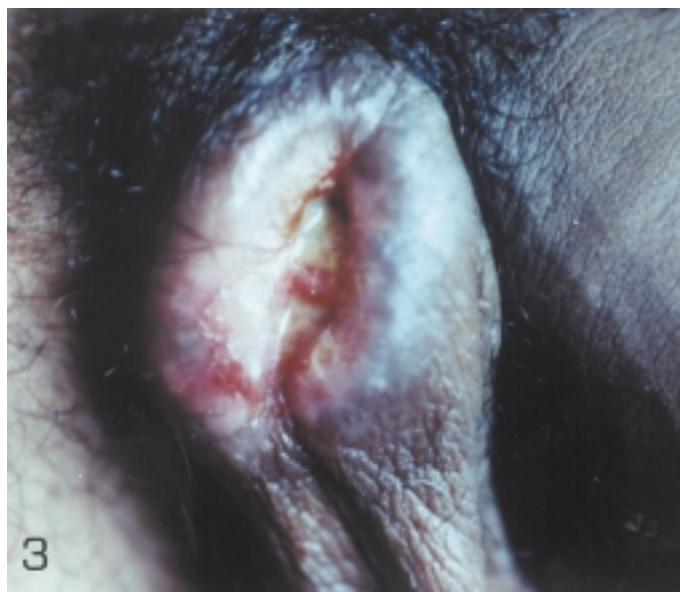


Fig. 3 - Ulcerated tumor in scrotum.

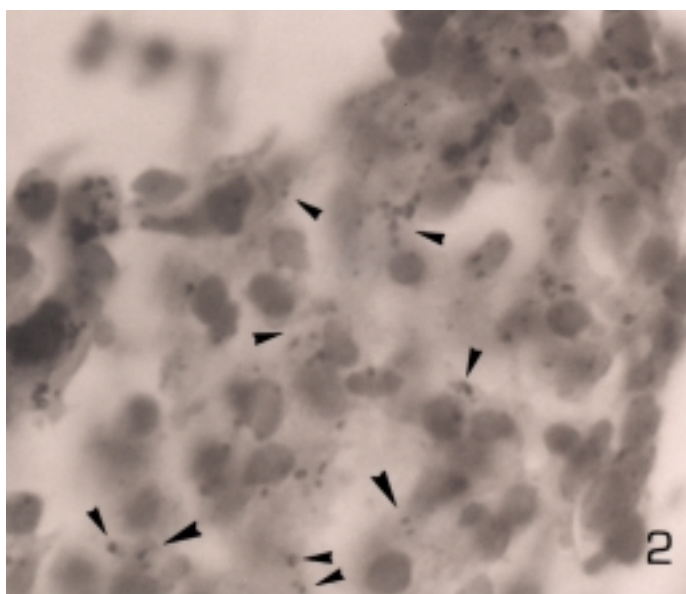


Fig. 2 - Granulomatous infiltrate from biopsy of penis, some amastigotes are seen (arrow head). Hematoxylin-eosin stain, 400X.

The lesions caused by cutaneous leishmaniasis are generally located in exposed areas of the body. In our cases 70% are in the extremities<sup>2</sup>.

In the two presented cases, the genital area localization claims for accurate differential diagnosis. In the first patient, the clinical characteristics of the lesion, and will be better and patient's age suggested primary syphilis, settling down specific treatment without observing improvement. In the second case, a diagnosis of squamous cell carcinoma was considered. After biopsy and histopathological study, the diagnosis of leishmaniasis was confirmed. Both patients informed the habit of sleeping undressed and outside the house.

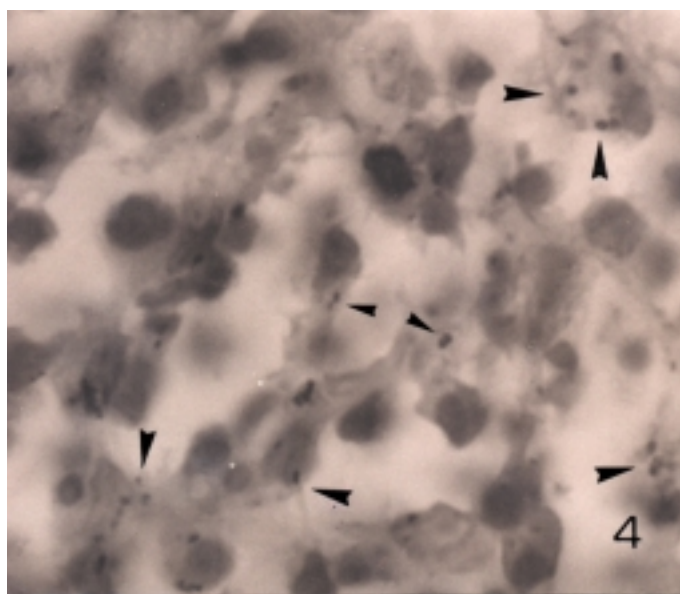


Fig. 4 - Granulomatous infiltrate from ulcerate tumor in the scrotum and presence of amastigotes (arrow head). Hematoxylin-eosin stain, 1,000 X.

There are few published cases of leishmaniasis located in the genital area, settling down in most of them that the lesions are due to direct inoculation of the parasite<sup>4,9,13</sup>.

Some authors suggest that the genital localization can result of the possible blood dissemination in those patients<sup>10</sup>. The tropism of leishmania for testicle have been demonstrated in experimental studies with *L. braziliensis*<sup>1</sup>. Histological studies of 137 cases of cutaneous leishmaniasis demonstrate the existence of species *braziliensis* and *mexicana* and that both species are major causes of cutaneous leishmaniasis in Venezuela<sup>2,3</sup>.

The reported cases presented an unusual localization of cutaneous leishmaniasis, which should be outlined mainly in those patients coming from endemic areas, being the key to practice necessary complementary exams to confirm the diagnosis.

## RESUMO

### Leishmaniose na região genital

São descritos os casos de dois pacientes procedentes do Estado de Bolívar, Venezuela. Ambos apresentavam leishmaniose cutânea na região genital, uma rara localização desta parasitose. O diagnóstico foi confirmado em ambos os casos pela histopatologia que demonstrou presença de amastigotas. Após tratamento com antimoniato de meglumina, as lesões cicatrizaram.

## REFERENCES

1. ARCAJ, de L.P.; OCHOA, de N.M. & ERCOLI, N. - Nuevas observaciones sobre lesiones genitales ocasionadas por *Leishmania mexicana amazonensis*. *Acta cient. venez.*, **29**: 35-41, 1978.
2. CABELLO, I. - Leishmaniasis cutánea en el Estado Bolívar. Estudio clínico-histopatológico. Venezuela, 1989. (Trabajo de Ascenso para Profesor Agregado - Universidad de Oriente).
3. CABELLO, I. - Identificación *in situ* de amastigotas en leishmaniasis cutánea, mediante anticuerpos monoclonales. Venezuela, 1993. (Trabajo de Ascenso para Profesor Asociado - Universidad de Oriente).
4. CASTRO, C.A.; HIDALGO, H.H.; SOLANO, A.E. *et al.* - Leishmaniasis of the genital organs. *Med. cut. ibero. lat.-amer.*, **15**: 145-150, 1987.
5. CUPOLILLO, E.; GRIMALDI Jr., G. & MOMEM, H. - A general classification of new world *Leishmania* using numerical zymotaxonomy. *Amer. J. trop. Med. Hyg.*, **50**: 296-311, 1994.
6. GONZÁLEZ, R.; DEVERA, R.; MADRID, C. & ZGHAYER, S. - Evaluación de un brote de leishmaniasis tegumentaria americana en una comunidad rural del Estado Bolívar, Venezuela. *Rev. Soc. bras. Med. trop.*, **33**: 31-37, 2000.
7. GRIMALDI Jr., G.; TESH, R.B. & McMAHON-PRATT, D. - A review of the geographic distribution and epidemiology of leishmaniasis in the new world. *Amer. J. trop. Med. Hyg.*, **41**: 687-725, 1989.
8. GRIMALDI Jr., G. & TESH, R.B. - Leishmaniasis in the new world: current concepts and implications for future research. *Clin. Microbiol. Rev.*, **6**: 230-250, 1993.
9. GRUNWALD, M.H.; AMICHAJ, B. & TRAU, H. - Cutaneous leishmaniasis on an unusual site: the glans penis. *Brit. J. Urol.*, **82**: 928, 1998.
10. MARSDEN, P.D. - Mucosal leishmaniasis ("espundia", Escomel, 1911). *Trans. roy. Soc. trop. Med. Hyg.*, **80**: 859-876, 1986.
11. PEARSON, R.D. & SOUSA, A.Q. - Clinical spectrum of leishmaniasis. *Clin. infect. Dis.*, **22**: 1-13, 1996.
12. RIDLEY, D.S. - A histological classification of cutaneous leishmaniasis and its geographical expression. *Trans. roy. Soc. trop. Med. Hyg.*, **74**: 515-521, 1980.
13. SCHUBACH, A.; CUZZI-MAYA, T.; GONÇALVES-COSTA, S.C.; PIRMEZ, C. & OLIVEIRA NETO, M.P. - Leishmaniasis of glans penis. *J. Europ. Acad. Derm. vener.*, **10**: 226-228, 1998.

Received: 20 December 2000

Accepted: 26 October 2001