

## WIDESPREAD CUTANEOUS LESIONS DUE TO *Sporothrix schenckii* IN A PATIENT UNDER A LONG TERM STEROIDS THERAPY

Luiz Carlos SEVERO (1), Moira FESTUGATO (2), César BERNARDI (3) & Alberto Thomaz LONDERO (4)

### SUMMARY

A case of sporotrichosis in a woman presenting 63 cutaneous lesions distributed all over the tegument is related. The patient had both humoral (Immunoglobulins) and cellular (Lymphocytes subpopulations) immunity within normal limits, but was under treatment with steroid during a long time (Prednisone 10 mg daily for 2 years), due to a sciatic pain. In addition a review of the Brazilian literature on this type of lesions was carried out and commented.

**KEYWORDS:** Sporotrichosis; *Sporothrix schenckii*; Corticosteroid; Side effect.

### INTRODUCTION

*Sporothrix schenckii* usually is introduced into the human body by direct intracutaneous inoculation or, rarely, by the respiratory route. Inoculated, it causes a subcutaneous mycosis; inhaled, it can elicit manifestations similar to those caused, usually, by the other thermal dimorphic pathogenic fungi, which are agents of systemic mycoses. *S. schenckii* also may act as an opportunistic fungus<sup>6,8</sup>.

Widespread cutaneous lesions is a very uncommon occurrence in subcutaneous sporotrichosis, but they are frequent in the systemic and opportunistic presentation of the mycosis<sup>5,10,11</sup>.

A case of a patient under a long corticoid therapy presenting widespread cutaneous lesions caused by *S. schenckii* will be herein related. In addition the Brazilian literature will be reviewed and commented.

### CASE REPORT

The patient is a 65 year-old black housewife, living in Porto Alegre, Rio Grande do Sul. One month ago, while bathing, she noted many cutaneous nodules. She denied any symptoms. She was using steroids since a long time (Prednisone 10 mg daily for 2 years), due to a sciatic pain. On physical examination she presented with 63 non-painful, movable, nonattached subcutaneous nodules of irregular shape (averaging 3 cm in greatest dimension),

distributed all over her body (Fig. 1): 17 lesions on the lower right limb, 6 on the lower left limb, 4 on the right limb, 14 on the upper left limb, 7 on the back, 6 on the buttocks, 6 on the thorax and 3 on the abdominal wall (Fig. 2). None of these lesions had a lymphangitic component. Laboratory findings were: hemogram, slight anemia; fasting glycemia 104 mg/dL (normal 70-110); VDRL non reagent; FTA-ABS negative; Mantoux non reactive. A chest X-ray showed no pleuro-pulmonary abnormalities.

Two biopsies were performed, one of which in a recent nodule. H&E stained sections showed in both specimens epithelioid histiocytes in concentric zones with central area of neutrophils with a dermal necrotic focus. Homogenized fragments were seeded on Sabouraud medium and incubated at 25°C; fast growing membranous white colonies were obtained; microscopically the colonies were composed of delicate septate branched hyaline hyphae and oval or piriform conidia (2-3/4 µm). Subcultures on BHI (Difco), incubated at 37°C, revealed the characteristic yeast-like forms of *S. schenckii*. New sections of biopsied tissue were obtained and stained by Gomori methenamine silver stain; several single and budding round yeast cells compatible with the tissue forms of *S. schenckii* were, then, detected.

Due to the atypical presentation of the mycosis, the patient underwent immunological assessment: total lymphocytic count was 3162/mm<sup>3</sup> (normal 1250-4500), from which 50% were T lymphocyte and 9% B lymphocytes; subpopulations of lymphocytes CD4 885/mm<sup>3</sup>, CD8 316/mm<sup>3</sup>, ratio CD4/CD8 = 2.8 (normal 0.9-

(1) Pesquisador do CNPq; Faculdade de Medicina, Universidade Federal do Rio Grande do Sul (UFRGS), RS, Brasil.

(2) Serviço de Dermatologia, UFRGS, Santa Casa, RS, Brasil.

(3) Chefe do Serviço de Dermatologia, UFRGS, Santa Casa, RS, Brasil.

(4) Universidade Federal de Santa Maria, Santa Maria, RS, Brasil.

Correspondence to: L. C. Severo, M.D., Laboratório de Microbiologia Clínica, IPD - Santa Casa, Annes Dias 285, 90020-090 Porto Alegre, RS, Brazil. Fax 00 55 51 214 8435 - E-mail: severo@santacasa.tche.br

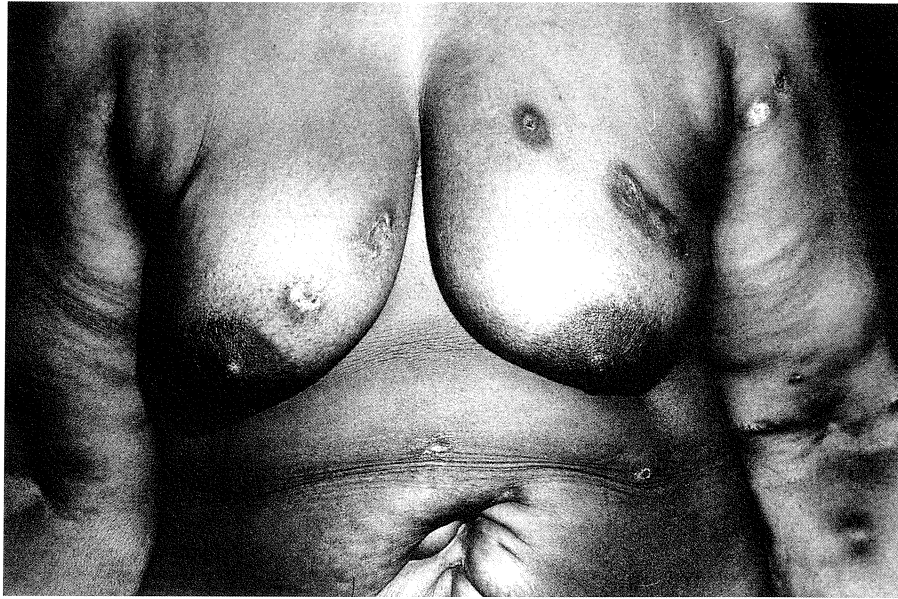


Fig. 1 - Cutaneous lesions widely distributed in breast, abdomen and left upper limb.

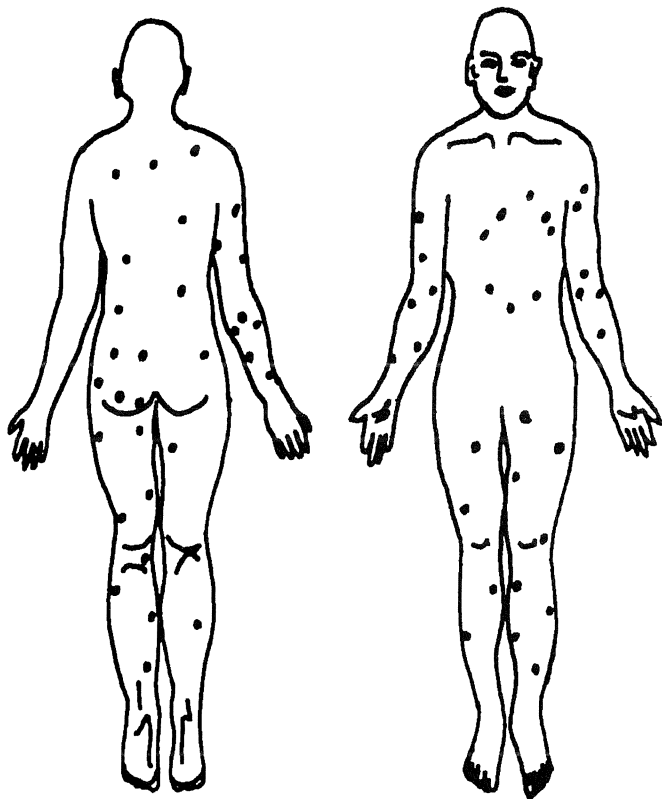


Fig. 2 - Schematic distribution of patient's 63 cutaneous lesions.

3.0); Immunoglobulins: IgG 3.630 mg/dL (normal 690-1400), IgA 591 mg/dL (normal 70-370) and IgM 269 mg/dL (normal 40-240); complement C3 163 mg/dL (normal 20-600) and C4 39 mg/dL (normal 5-260).

Steroid therapy was discontinued and the patient received potassium iodide in an initial dosage of 5 drops three times a day followed by 120 drops per day. The lesions cleared in one month but the treatment continued for two months. Seven months later the patient remained very well.

## DISCUSSION

Five cases of sporotrichosis presenting with widespread skin lesions could be gathered in the Brazilian literature. Patient's data, clinical manifestations and associated conditions and treatment are shown in Table 1.

In four patients (cases 1, 3, 4, and 5) cutaneous lesions were associated with osseous involvement, consequently a presentation of systemic sporotrichosis. Involvement of bones in the most frequent extracutaneous lesion in this type of infection<sup>5,11</sup>. One of these four patients (case 5) presented also a very destructive mucosal lesion, an unusual occurrence. In the remaining patient (case 2) no extracutaneous lesions were detected, consequently a presentation of subcutaneous sporotrichosis.

In spite of no clinical evidence of extracutaneous lesions in

**TABLE 1**  
Widespread cutaneous lesions in reported Brazilian cases of sporotrichosis

Case (Ref.)	Nº	Patient's data and major clinical manifestations	Associated Conditions	Treatment/Results
1	(4)	4 year-old white female. Fifty nodules distributed on the face, neck, upper and lower limbs. Tumefaction of two fingers. Periostitis and osteoperiostitis of many bones of both hands. Slight hepatosplenomegaly.	Not recorded	Potassium iodide/ Follow-up not recorded
2	(8)	23 year-old black female. Nodules on the trunk and limbs.	Chagas' disease	Potassium iodide/ Cured
3	(8)	36 year-old black male. Nodules and ulcerations distributed over the body. Osteolytic lesions in the bones of the legs, forearms, both hands and both feet.	Not recorded	Potassium iodide/ Skin lesions cured; bone lesions improved
4	(2)	10 year-old white boy. Nodules, ulcerations and scars on the face, upper and lower limbs. Osteolytic lesion in the right ulna and in many bones of both hands.	Not recorded	Potassium iodide/ Follow-up not recorded
5	(1)	21 year-old white male. Scarred atrophic hypochromic lesions on the face and limbs. Tumefaction of the left foot and deformities of the fingers and toes. Osteolytic lesions in the left ulna and in many bones of the hands and feet.	Not recorded *	Ketoconazole 200 mg, amphotericin B 2450 mg/ Skin lesions cured; bone lesions improved
6 (present case)		65 year-old black woman. Sixty three subcutaneous nodules distributed over the body	Steroids **	Potassium iodide/ Cured

(\*) Normal reaction to delayed hypersensitivity test. T and B lymphocytes and immunoglobulins within normal limits.  
(\*\*) Total lymphocytes and T and B lymphocytes, CD4-CD8 ratio and immunoglobulins within normal limits.

our patient, they can not be excluded because visceral lesions can run an asymptomatic course, only detected by histological examination of internal organs<sup>9</sup>. We may also presume that our patient acquired the infection by traumatic route but spreading of skin lesions resulted from hematogenous dissemination, which was facilitated by steroid therapy<sup>3,5,6,11</sup>.

Treatment of iodides seems to be effective in patients with widespread skin lesions without extracutaneous involvement, as it occurred in case 2 and in our patient.

## RESUMO

### Lesões generalizadas causadas por *Sporothrix schenckii* em paciente sob corticoterapia de longa duração.

É relatado caso de esporotricose em mulher apresentando 63 lesões cutâneas distribuídas pelo tegumento. A paciente tinha imunidade humoral (Imunoglobulinas) e celular (Subpopulações linfocitárias) dentro dos limites da normalidade, mas estava sob corticoterapia de longa duração (Prednisona 10 mg/dia por 2 anos), para ciática. Em acréscimo uma revisão da literatura brasileira, deste tipo de lesões, é feita e comentada.

## REFERENCES

1. CASTRO, R.M.; SABOGAL, M.F.; CUCE, L.C. & SALEBIAN, A. - Disseminated sporotrichosis. Report of a clinical case with mucocutaneous, osteo-articular and ocular lesion. *Mykosen*, 24: 92-96, 1981.
2. CURBAN, G.V.; LACAZ, C. da S.; BELFORT, E.; DILLON, N. & AUADA, J. - Esporotricose disseminada. Registro de um caso. *Rev. Hosp. Clin. Fac. Med. S. Paulo*, 15: 369-371, 1960.
3. FRIEDMAN, S.J. & DOYLE, J.A. - Extracutaneous sporotrichosis. *Int. J. Derm.*, 22: 171-176, 1983.
4. GOMES, J.M. - Um caso de esporotricose generalizada. *An. paul. Med. Cirurg.*, 11: 197-199, 1920.
5. LYNCH, P.J.; VOORHEES, J.J. & HARREL, E.R. - Systemic sporotrichosis. *Ann. intern. Med.*, 73: 23-30, 1970.
6. MORGAN, M.A.; COCKERILL, F.R.; CORTESE, D.A. & ROBERTS, G.D. - Disseminated sporotrichosis with *Sporothrix schenckii* fungemia. *Diagn. Microbiol. infect. Dis.*, 2: 151-155, 1984.
7. RIPON, J.W. - *Medical Mycology. The pathogenic fungi and the pathogenic actinomycetes*. 3. ed. Philadelphia, W. B. Saunders, 1988. p. 373-380.
8. SAMPAIO, S.A.P.; LACAZ, C. da S. & ALMEIDA, F. - Aspectos clínicos da esporotricose em São Paulo. Análise de 235 casos. *Rev. Hosp. Clin. Fac. Med. S. Paulo*, 9: 391-402, 1954.
9. SCHAMROTH, J.M.; GRIEVE, T.P. & KELLER, P. - Disseminated sporotrichosis. *Int. J. Derm.*, 27: 28-30, 1988.
10. SMITH, P.W.; LOOMIS, G.W.; LUCKASEN, J.L. & OSTERHOLM, R.K. - Disseminated cutaneous sporotrichosis. *Arch. Derm.*, 117: 143-144, 1981.
11. WILSON, D.E.; MANN, J.J.; BENNETT, J.E. & UTZ, J.P. - Clinical features of extracutaneous sporotrichosis. *Medicine (Baltimore)*, 46: 265-279, 1967.

Received: 02 June 1998

Accepted: 03 December 1998