

HUMAN CYCLOSPORIASIS DIAGNOSIS: REPORT OF A CASE IN SÃO PAULO, SP, BRAZIL

Andréia Otaviani Di Pietro FERNANDES, Maria Cristina Casaqui CAROLLO,
Lúcia Maria Almeida BRAZ, Vicente AMATO NETO & Maria Sílvia Hadler VILLELA

SUMMARY

Diagnosis of the human cyclosporiasis is reported in São Paulo, SP, Brasil. *Cyclospora cayetanensis* has been identified in the feces of a patient by a modified Kinyoun staining method, with later sporulation in a solution of 2.5% potassium dichromate.

The probability that this parasite is the eventual cause of gastrointestinal disturbances in the country was stimulated by this finding, which was arrived at by a simple technique. It had been kept in mind that the disease was expressing itself mainly among immunocompromised patients, whose number is increasing; especially in those with acquired immunodeficiency syndrome (AIDS), which is caused by the human immunodeficiency virus (HIV).

KEYWORDS: Coccidia; *Cyclospora*; Human host; Kinyoun staining

INTRODUCTION

The first infection by *Cyclospora cayetanensis* in human beings was reported by ASHFORD in 1979, and occurred in Papua New Guinea³.

For several years, *Cyclospora* was taken as a "cyanobacterium-like body". For a while, its identity was mistaken with a fungal spore, a species of *Blastocystis*¹⁴ and *Cryptosporidium* sp. Because of this it was referred to as a large *Cryptosporidium*^{6,9,10,11,14,15}.

Only as recently as 1993, ORTEGA et al., succeeded at inducing the sporulation of the *Cyclospora* oocysts and noticed that they presented, when mature, two sporocysts, each one containing two sporozoites inside^{9,12}. The oocysts are 8 to 10 µm in diameter^{4,6,7,9,13,16,17}.

Regarding the epidemiological feature, *C. cayetanensis* has been observed in the human feces on the following continents: North, Central and South America; Africa; Bangladesh; southeast Asia; Australia; England and Eastern Europe. The parasitism has occurred according to a marked seasonality, i.e., at a determined time of year. In most of the cyclosporiasis episodes in immunocompetent persons, the parasite was associated with travel to tropical countries by foreigners, especially between May and September^{4,8}. Patients infected by the human immunodeficiency virus (HIV), who are infected by this parasite, deserve special mention¹⁷.

Clinical manifestations most commonly observed during the cyclosporiasis are: fatigue, nausea, abdominal cramps, anorexia, weight loss of 5% to 10% , vomiting and diarrhea. The diarrhea may not be present, though it is possible to be present, but alternating between constipation and melena^{4,5,12,14,16}. The duration, in immunocompetent individuals, is approximately 7 weeks with self-limiting, and oocyst excretion is associated with clinical illness¹³.

By means of this communication we have reported the finding of *C. cayetanensis* in a feces examination at the request of an individual in São Paulo, Brazil.

CASE REPORT

In April, 1998, the Parasitology Laboratory of the " Instituto de Medicina Tropical de São Paulo ", received a sample of feces from a 30 years old man. This happened during the comparative study of applied techniques to diagnosis the criptosporidiasis. The sample was from the " Laboratório Fleury ", which engages in activities of Clinical Pathology (Rua Cincinato Braga, 282, São Paulo, SP, Brazil). The analysis of the pasty sample was done, by the modified Kinyoun staining method¹, and acid-fast organisms stained deep pink, of 8 to 10 µm in diameter, were observed (Fig. 1). To verify sporulation of the possible *Cyclospora cayetanensis* oocysts, a solution of 2.5 % potassium dichromate was added and maintained at 28° C for seven days. After this,

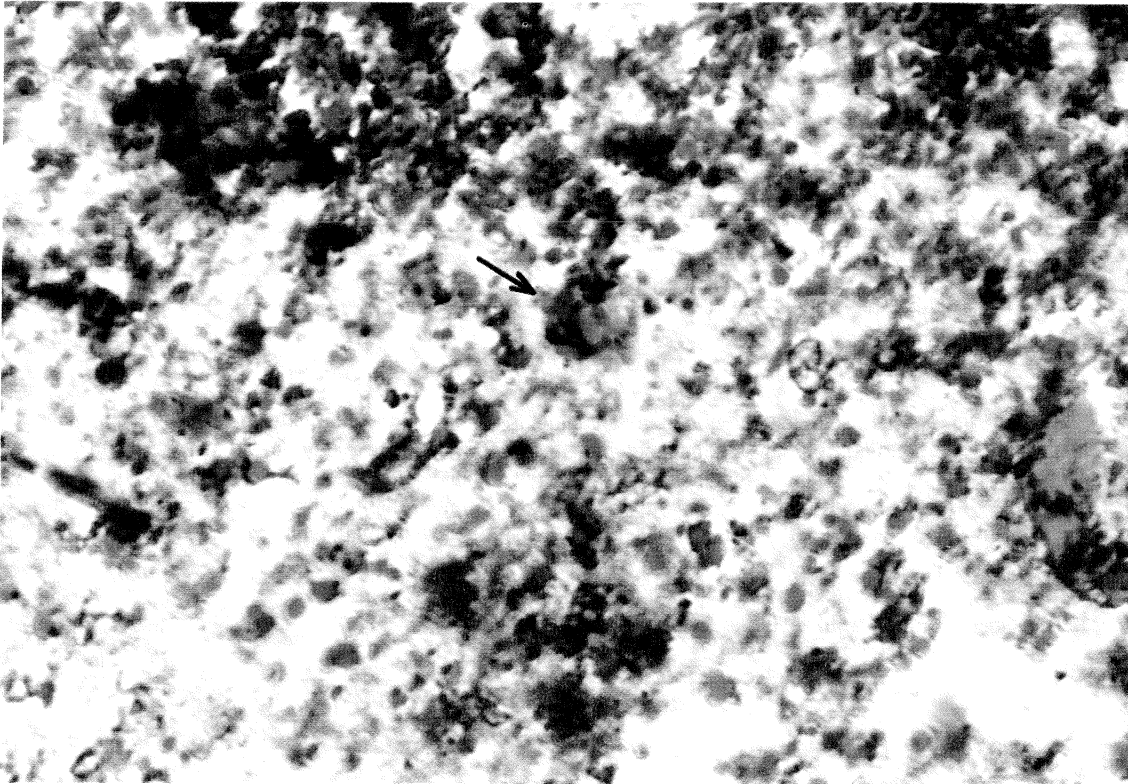


Fig. 1 – Morphologic and staining characteristics of *Cyclospora cayetanensis*. Oocyst stained deep pink with modified Kinyoun method (x 1000).

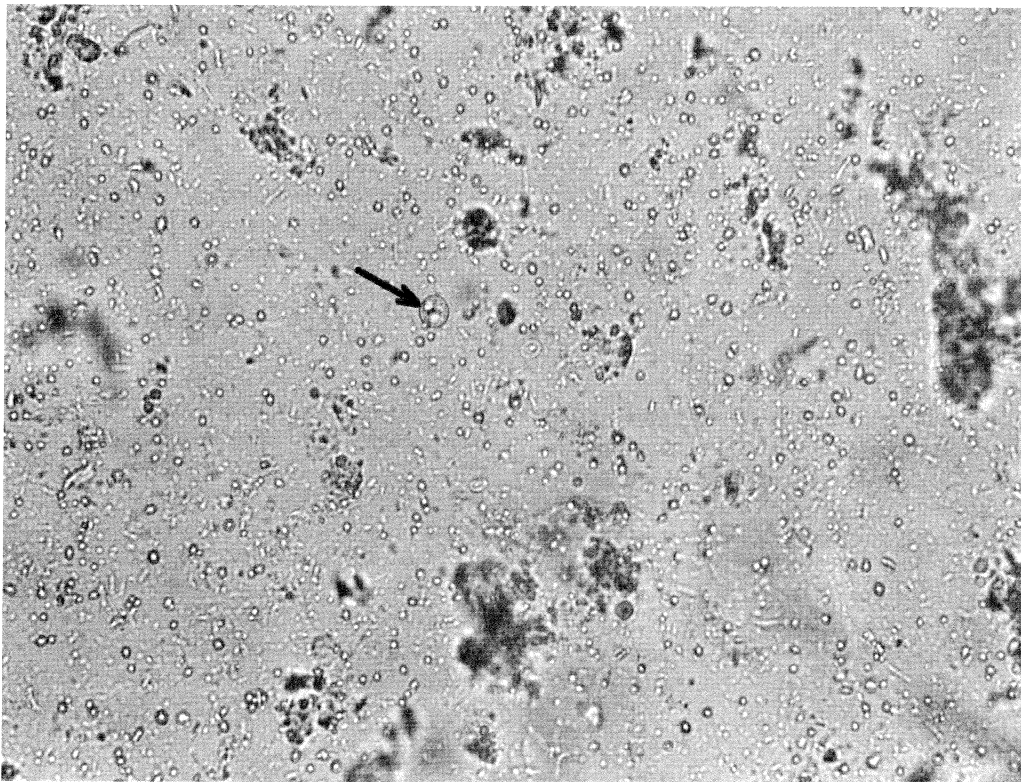


Fig. 2 – Sporulated oocyst of *Cyclospora cayetanensis* containing two sporocysts seen in direct wet mount (x 400)

spherical bodies, containing two sporocysts (Fig.2), which were not seen before in the fresh sample, were seen in the light microscope. Thus, because of this feature, it was possible to confirm that it were *C. cayetanensis* oocysts^{14,17}.

The feces were from a person who requested the parasitological examination on his own initiative. Unfortunately, in spite of our appeals, the mentioned laboratory management was not able to obtain more illustrative data in relation to the subject of this analysis due to internal policies.

COMMENTS

World-wide statistics indicate prevalence rates from 0.1% in developed countries to 11% in developing countries such as Kathmandu¹⁴.

In order to determine the true extent of infection by this protozoa in Brazil and to provide sufficient care, it is necessary to correctly diagnose the *Cyclospora*; first by means of relatively simple procedure which are already well known and in use, then side by side with new alternatives after they have been standardized, such as by a polymerase chain reaction. In this way, other complications notwithstanding, incorrect treatment of gastrointestinal disturbances can be avoided.

In Brazil, ARAÚJO et al., in 1995, identified *Cyclospora* in patient feces with the human immunodeficiency virus (HIV), presenting diarrhea for three months, along a significant weight loss². Later, YAI et al., 1997, identified the protozoan, for the first time, in dog feces. They have suggested that besides untreated water, other transmission means, along with canine contact, could be important factors in the human diarrheic disease associated with the mentioned protozoan¹⁶. Through this report, we wish to call attention to this protozoan, which must be infecting more people than is realized, and to point out that it is becoming imperative to bring this out by means of techniques which already exist and which are not necessarily complex. Besides this, we wish to note that it is important not to forget, that now with the constant rise of immunocompromised patients, and the increased influence of HIV and subsequent AIDS, that cyclosporiasis should not be overlooked as an opportunistic infection.

RESUMO

Relato de caso de ciclosporíase humana diagnosticado em São Paulo, SP, Brasil

É relatado o diagnóstico de ciclosporíase humana em São Paulo, SP, Brasil. *Cyclospora cayetanensis* foi encontrada nas fezes de um indivíduo através de exame pelo método de coloração de Kinyoun modificado, com posterior esporulação em dicromato de potássio a 2,5%.

Esta verificação deve estimular a necessidade de considerar a ciclosporíase como eventual causa de distúrbios gastrointestinais

no país, podendo ela ser reconhecida até mesmo por meio de técnica razoavelmente simples. Foi ainda lembrado que esta parasitose vem adquirindo expressividade sobretudo pelo fato de não raramente acometer imunodeprimidos, agora cada vez mais numerosos em especial como decorrência da infecção pelo vírus da imunodeficiência humana (HIV), que causa a síndrome da imunodeficiência adquirida (AIDS).

ACKNOWLEDGEMENTS

We wish to thank Dr. Pedro Paulo Chieffi from "Laboratório de Imunopatologia – IMT" for his assistance in confirming the diagnosis and Almir Robson Ferreira from "Setor de Programação Visual – IMT" for the photographic composition.

REFERENCES

1. AMATO NETO, V.; BRAZ, L.M.A.; DI PIETRO, A.O. & MÓDOLO, J.R. - Pesquisa de oocistos de *Cryptosporidium sp* em fezes: comparação entre os métodos de Kinyoun modificado e de Heine. *Rev. Soc. bras. Med. trop.*, 29: 575-578, 1996.
2. ARAÚJO, A.L.T.; TERAMUSSI, L.A.; MANGINI, A.C.S. et al. - Descrição de um caso de ciclosporose em paciente portador de SIDA/AIDS, Brasília-DF, Brasil. In: CONGRESSO BRASILEIRO DE PARASITOLOGIA, 14., Goiânia, 1995. *Resumos*. p.244. (*Rev. Pat. trop.*, 23 (supl). jul/dez, 1994).
3. ASHFORD, R.W. - Occurrence of an undescribed coccidian in man in Papua New Guinea. *Ann. trop. Med. Parasit.*, 73: 497-500, 1979.
4. BERLIN, O.G.W.; NOVAK, S.M.; PORSCHE, R.K. et al. - Recovery of *Cyclospora* organisms from patients with prolonged diarrhea. *Clin. infect. Dis.*, 18: 606-609, 1994.
5. COLLEY, D.G. - Widespread foodborne cyclosporiasis outbreaks present major challenges. *Emerg. infect. Dis.*, 2: 354-356, 1996.
6. GONZÁLEZ-RUIZ, A. & BENDALL, R.P. - Size matters: the use of the ocular micrometer in diagnostic parasitology. *Parasit. today*, 11: 83-85, 1995.
7. MEDINA-DE LA GARZA, C.E.; GARCÍA-LÓPEZ, H.L.; SALINAS-CARMONA, M.C. & GONZÁLEZ-SPENCER, D.J. - Use of discontinuous Percoll gradients to isolate *Cyclospora* oocysts. *Ann. trop. Med. Parasit.*, 91: 319-321, 1997.
8. ORTEGA, Y.R.; STERLING, C.R. & GILMAN, R.H. - *Cyclospora cayetanensis*. *Advanc. Parasit.*, 40: 399-418, 1998.
9. ORTEGA, Y.R.; STERLING, C.R.; GILMAN, R.H.; CAMA, V.A. & DÍAZ, F. - *Cyclospora* species: a new protozoan pathogen of humans. *New Engl. J. Med.*, 328: 1308-1312, 1993.
10. PIENIAZEK, N.J. & HERWALDT, B.L. - Reevaluating the molecular taxonomy: is human-associated *Cyclospora* a mammalian *Eimeria* species? *Emerg. infect. Dis.*, 3: 381-383, 1997.
11. RELMAN, D.A.; SCHMIDT, T.M.; GAJADHAR, A. et al. - Molecular phylogenetic analysis of *Cyclospora*, the human intestinal pathogen, suggest that it is closely related to *Eimeria* species. *J. infect. Dis.*, 173: 440-445, 1996.

12. SIFUENTES-OSORNIO, J.; PORRAS-CORTÉS, G.; BENDALL, R.P. et al. - *Cyclospora cayetanensis* infection in patients with and without AIDS: biliary disease as another clinical manifestation. **Clin. infect. Dis.**, 21: 1092-1097, 1995.
13. SMITH, H.V.; PATON, C.A.; GIRDWOOD, R.W.A. & MTAMBO, M.M.A. - *Cyclospora* in non-human primates in Gombe, Tanzania. **Vet. Rec.**, 138: 528, 1996.
14. SOAVE, R. - *Cyclospora*: an overview. **Clin. infect. Dis.**, 23: 429-437, 1996.
15. SUN, T.; ILARDI, C.F.; ASNIS, D. et al. - Light and electron microscopic identification of *Cyclospora* species in the small intestine. Evidence of the presence of asexual life cycle in human host. **Amer. J. clin. Path.**, 105: 216-220, 1996.
16. VISVESVARA, G.S.; MOURA, H.; KOVACS-NACE, E.; WALLACE, S. & EBERHARD, M.L. - Uniform staining of *Cyclospora* oocysts in fecal smears by a modified safranin technique with microwave heating. **J. clin. Microbiol.**, 35: 730-733, 1997.
17. YAI, L.E.O.; BAUAB, A.R.; HIRSCHFELD, M.P.M.; OLIVEIRA, M.L. & DAMACENO, J.T. - The first two cases of *Cyclospora* in dogs, São Paulo, Brazil. **Rev. Inst. Med. trop. S. Paulo**, 39: 177-179, 1997.

Received: 28 July 1998

Accepted: 24 September 1998