

## TUMOR-LIKE LESION DUE TO CHAGAS' DISEASE IN A PATIENT WITH LYMPHOCYTIC LEUKEMIA

Pedro Rippel SALGADO(1), Anthony Guerra GORSKI(2), Andréa Ribeiro ALEIXO(3) & Eugênio Oliveira Martins de BARROS(4)

---

### SUMMARY

A 73 year-old white male, living in the interior of the state of Mato Grosso do Sul, in central Brazil, after an initial diagnosis of sinusitis was transferred to the neurology service with a 3-day evolution of intracranial hypertension.

Exams showed lymphocytic leukemia and a tumor-like lesion, either an expanding inflammatory process such as an abscess or a neoplasm. Treatment with Ceftriaxone and Decadron was started and intracranial hypertension was controlled.

Methotrexate was injected on the occasion of the next puncture considering a possible leukemia infiltration. Flagellate forms of *T. cruzi* were observed in the CSF and treatment with Benznidazole was started. After 4 days the CSF presented fractionated forms of trypomastigotes. The protein level was 27%. Signs of intracranial hypertension ceased. Tomography and magnetic resonance images showed an important reduction of the tumor-like lesion. The clinical condition of the patient improved.

**KEYWORDS:** Chagas' disease; Leukemia; Tumor-like lesion.

---

### INTRODUCTION

Chagas' disease is an endemic parasitosis caused by *Trypanosoma cruzi* in some regions of South America<sup>1,3</sup>. The flagellar protozoan is transmitted by blood sucking triatomine insects, blood transfusion<sup>7</sup> and vertical transmission. It can produce damage in several organs, the heart and the digestive tract being the most common. During the acute phase the Central Nervous System (CNS) may be affected by the parasite which may produce meningoencephalitis. The parasite has been isolated from Cerebrospinal Fluid (CSF)<sup>6</sup>. A common finding is an excess of protein and lymphocytes, with positive serologic tests<sup>6</sup>.

Pathologically, the acute meningoencephalites may be multifocal or diffuse or, in some cases, necrotic<sup>7</sup>.

Parasites in the amastigote form may be seen, especially inside cells such as macrophages, glial cells<sup>3,7,10</sup> and, less frequently, in neurons<sup>7,10</sup>, or free in the parenchyma, where they tend to form pseudocysts<sup>10</sup>, although less frequently.

### CASE REPORT

A 73 year-old white male, 70 kg, living in the interior of the state of Mato Grosso do Sul (MS), central Brazil, presented behavioral disorders in February 1994, followed by an intensive and progressive frontal headache accompanied by tinnitus. He looked for medical care and received a diagnosis of sinusitis. The patient was referred to our service because no remission was observed.

---

(1) Assistant Professor of Neurology-UFMS – Universidade Federal de MS, Brazil.

(2) Medical Resident.

(3) Medical Resident.

(4) Assistant Professor of Epidemiology – UFMS, Brazil.

**Correspondence to:** Dr. Eugênio O.M. de Barros. R. Quintino Bocaiúva, 298, 79050-110 Campo Grande, Mato Grosso do Sul, Brasil.

He arrived on the 3<sup>rd</sup> day of evolution, presenting left brachiofaciocrural paresis, with signs and symptoms of severe intracranial pressure (ICP). The patient mentioned that he had been exposed to the triatomine in his youth. He also reported a blood transfusion about 6 years ago, when he was submitted to cardiac surgery for myocardial revascularization at another institution. Routine tests revealed the presence of lymphocytic leukemia. Treatment with Leukeran® (Clorambucil) was initiated.

A lumbar puncture was performed on February 17, which revealed 80 mg% protein, 70 mg% glucose, 100 mg% chloride and 34.6 IU/L LDH. Bacteriology and culture were negative, and an expansive inflammatory process was considered to be present. Rocephin® (Ceftriaxone) 1 g i.v. 12/12 h was started. Brain Computed Tomography (CT) (Figure 1) showed an expansive 2.5 x 3.0 cm lesion located in the right occipitoparietal lobe, and surrounded by a partially cystic edematous lesion in the periventricular area producing a mass effect on adjacent structures.

The diagnostic hypothesis was an expansive tumor or an inflammatory process such as an abscess. Considering these hypotheses, corticosteroids (Dexamethasone-Decadron®), 4 mg 6/6 h, were started on February 20 in order to reduce the inflammatory process and the perilesional edema.

On February 25, the lumbar puncture was repeated. The clinical symptoms of intracranial hypertension were

reduced. Ten ml of CSF were obtained and 5 mg of methotrexate were injected intrathecally, considering the hypothesis of leukemia infiltration.

Flagellate forms of *T. cruzi* were observed in the CSF. The expansive intracranial process was attributed to the agent of Chagas' disease.

On the 26<sup>th</sup>, specific treatment for Chagas' disease was started with Rochagan® (Benznidazole), 150 mg twice a day for 60 days, 5 mg/kg/day.

On March 1, the CSF showed fractionated forms of trypomastigotes, with 27 mg% of protein, a level that persisted thereafter. Signs of intracranial hypertension ceased.

In 1994, the patient, who was under neurologic observation, presented focal left seizures, with secondary generalization. At present he is taking Tegretol® (Carbamazepine) 400 mg, twice a day. Clinically he presents equilibrium disorders, probably due to visual problems, and a gait disorder predominantly on the right.

Moderate muscle weakness, hypotonia and profound hyperreflexia were observed on the left side of the body.

During the current year the patient was submitted to a series of exams to: (A) confirm diagnosis; (B) exclude diagnosis; and (C) control clinical conditions.

(A) - A Myelogram for leukemia revealing that 80% of the cell population was replaced by mature lymphocytes.

- Positive ELISA and immunofluorescence serologic Chagas' tests.

- Upper digestive endoscopy due to a complaint of gastritis 26 years ago. The endoscopy showed second degree esophagitis and acute duodenitis.

(B) - Negative Toxoplasmosis serology;

- Negative anti-HIV serology;

- Serum protein electrophoresis showed slightly reduced total protein and alpha-1 and gamma globulin.

(C) - Hematologic tests showed leucocytosis: 33,300/mm<sup>3</sup> to 84,600/mm<sup>3</sup>; with an 88 to 90% predominance of lymphocytes, and hypochromic macrocytic anemia.

- Magnetic Resonance Imaging performed on April, 25 (Figure 2) disclosed areas of intense signals in T2 involving the white matter surrounding the anterior horn of the lateral ventricle, extending to the white-cortex transition, which is delineated by a short T1 signal (methemoglobinemia) and some irregularly contrasted right temporoparietooccipital area and in the left precentral

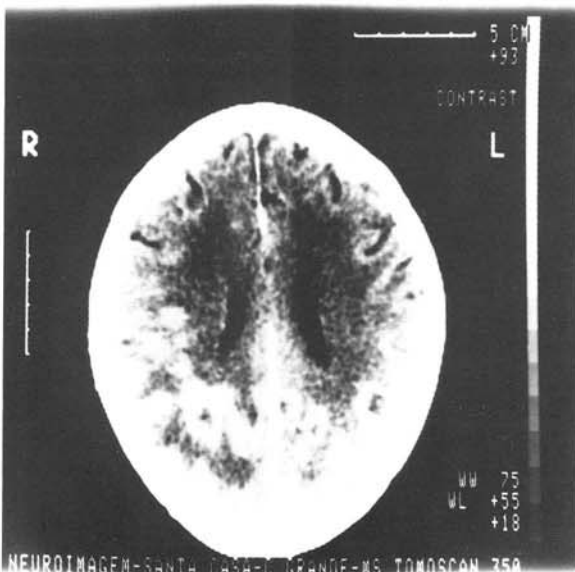


Fig. 1 - Expansive lesion at the right occipitoparietal lobe. -

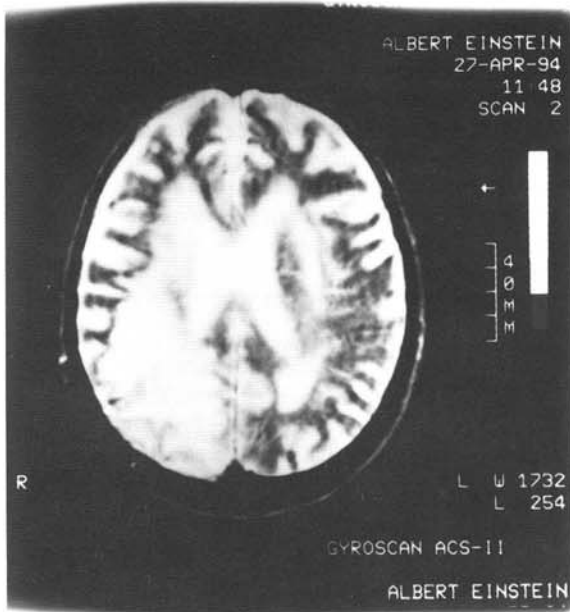


Fig. 2 - Effacement of the adjacent sulcus and compression of the right posterior ventricular horn.

gyrus, causing effacement of the adjacent sulcus and some compression on the right posterior ventricular horn, suggesting encephalitis, vasculitis and a demyelination process, involving the white matter and some right laminar temporoparietooccipital areas of necrosis.

– A CT done on August 29 (Figure 3) suggested areas of encephalomalacia in the right parietal lobe and degenerative cerebrovascular alterations.

Both the MRI and CT showed an important reduction of the cerebral mass (Figure 1, 2 and 3).

Except for the esophagitis and duodenitis, he reported no other common chronic complications of Chagas' disease such as cardiac and gastrointestinal disorders.

## DISCUSSION

Chagas' disease is still a major health problem in Brazil as well as in other South American countries. The state of Mato Grosso do Sul (MS) is considered an endemic area with a prevalence of 2.5%<sup>4</sup>. A report of a survey done by the State Coordination of the National Health Foundation<sup>4</sup> revealed that of 22,733 triatomine specimens examined 111 (0.5%) were infected with the protozoan parasite *T. cruzi*.

The risk of transfusion-associated infection has been estimated to be between 12 and 18%, and in individuals

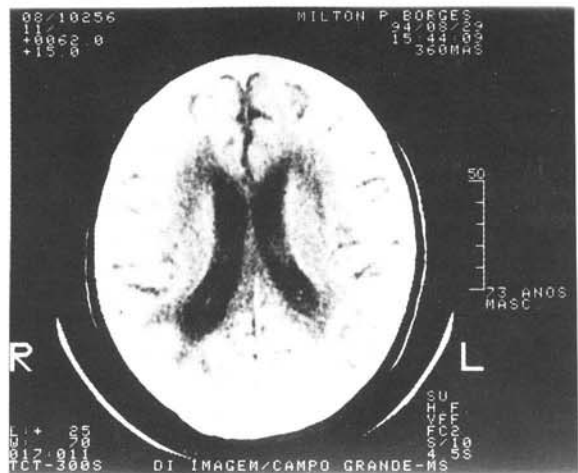


Fig. 3 - Reduction of the cerebral mass observed previously.

submitted to several transfusions this risk may increase to 22.2%, in spite of the use of specific prophylactic measures<sup>5</sup>.

CORONA et al.<sup>1</sup> stated that: "Another fact that hinders the diagnosis is the low probability of identifying the transfusion responsible for the infection". We could not trace transfusions done about 6 years ago at another service.

In this case evidence for both vector transmission and blood transfusions was present. This could be either a primary infection or a recrudescence of the disease acquired by the patient in his youth and reactivated by his immunosuppressed condition. Reactivation of the disease in the CNS during the chronic phase is uncommon and occurs only in immunosuppressed subjects such as patients with AIDS, transplants, leukemia and lymphomas<sup>9</sup>. This is considered to be a reactivation of the acute phase. Focal encephalitis tend to progress to local necrosis and eventually become a tumor-like lesion, also described as a mass effect.

According to MONTEVERDE et al.<sup>8</sup>, the greater susceptibility to infections occurring in blood disorders, specially lymphomas and leukemias, is due to immunological alterations typical of these blood disorders consequent to bone marrow failure and to the administration of antibiotics that destroy the agent, thus breaking the biological balance, and to the action of drugs used for the treatment of these diseases. These aspects could lead to a suppression of the bone marrow and of the immunological system.

The first case of Chagasic encephalitis with chronic lymphocytic leukemia was mentioned by MONTE-

VERDE<sup>8</sup> and described by FRANÇA et al. in Brazil in 1969.

In post-mortem histological preparations QUEIROZ<sup>12</sup> detected the first purely cerebral infection producing a tumor-like lesion of the brain caused by *T. cruzi*, with predominance of amastigote forms, suggesting a neurotropic strain, as later confirmed by other experimental studies.

The protozoan produces in the CNS forms of meningoencephalitis that range from a diffuse to a multifocal or, in some cases, to a necrotic<sup>7</sup> lesion producing a mass effect, with compression of the surrounding structures.

Among the cases of cerebral mass reported, one of the rarest types, even in endemic areas, is the cerebral granuloma, or chagasic cerebral cyst. Some studies from Argentina have reported a chagasic cerebral mass in immunosuppressed patients, all of them HIV positive.

HOFF et al.<sup>6</sup> demonstrated that *T. cruzi* is frequently present in the CSF during the acute phase. This can be better demonstrated by culture instead of direct examination when a small number of organisms is present.

In the present study there was a direct observation of the protozoan after the use of corticosteroids which might have reduced the edema, favoring the outflow of the trypomastigote forms.

In most of the studies mentioned, the authors used anatomic-pathological examination of the cerebral mass and visualized amastigote forms in cerebral tissue, a procedure that was not performed in the present case. The clinical condition of this patient has improved with the treatment adopted.

## RESUMO

### Massa cerebral devido a Doença de Chagas em paciente com leucemia linfocítica

Paciente masculino, 73 anos, do interior de Mato Grosso do Sul, com diagnóstico inicial de sinusite, evoluiu em 3 dias para quadro de hipertensão intracraniana severa.

Transferido para o serviço de neurologia, os exames evidenciaram leucemia linfocítica e indicaram ainda processo inflamatório expansivo como abscesso ou tumor (exame do líquido e tomografia). Instituiu-se Ceftriaxone e Decadron.

Foi feita nova punção lombar, injetou-se metotrexate considerando possível infiltração leucêmica.

No líquido observou-se formas flagelares de *T. cruzi*. Iniciou-se benzonidazol. Após 4 dias o líquido apresentou formas fracionadas de tripomastigotas. O nível de proteínas se estabilizou em 27%. Cessou a sintomatologia da hipertensão. Tomografia e ressonância magnética posterior mostraram importante redução da formação tumoral observada anteriormente. Houve melhora das condições clínicas do paciente.

## REFERENCES

1. CORONA, S.; AMANALES, C.; AVARIA, M.A. et al. – Granuloma chagásico del cerebro en un paciente con leucemia linfoblástica. *Rev. méd. Chile*, 116:676-680, 1988.
2. COSTA, S.C.G.; CALABRESE, K.S.; ALENCAR, A.A. & LAGRANGE, P.H. – *Trypanosoma cruzi* invasion of structures related to development and central nervous system. *Rev. bras. Neurol.*, 22:183-190, 1986.
3. DEL CASTILLO, M.; MENDOZA, G.; OVIEDO, J. et al. – AIDS and Chagas' disease with central nervous system tumor-like lesion. *Amer. J. Med.*, 88:693-694, 1990.
4. FURLAN, M.B. – Distribuição de triatomíneos capturados em ambiente domiciliar, no período de 1984 a 1986, no Estado do Mato Grosso do Sul. Mato Grosso do Sul, 1987. (Monografia apresentada para a obtenção de título de sanitária, SP/UFMS).
5. GLUCKSTEIN, D.; CIFERRI, F. & RUSKIN, J. – Chagas' disease: another cause of cerebral mass in the acquired immunodeficiency syndrome. *Amer. J. Med.*, 92:429-432, 1992.
6. HOFF, R.; TEIXEIRA, R.S.; CARVALHO, J.S. & MOTT, K.E. – *Trypanosoma cruzi* in the cerebrospinal fluid during the acute stage of Chagas' disease. *New Engl. J. Med.*, 298:604-606, 1978.
7. LEIGUARDA, R.; RONCORONI, A.; TARATUTO, A.L. et al. – Acute CNS infection by *Trypanosoma cruzi* (Chagas' disease) in immunosuppressed patients. *Neurology*, 40:850-851, 1990.
8. MONTEVERDE, D.A.; TARATUTO, A.L. & LUCATELLI, N. – Meningoencefalitis chagásica aguda en pacientes inmunosuprimidos. *Rev. neurol. argent.*, 2:260-266, 1976.
9. PITTELLA, J.E.H. – Central nervous system involvement in Chagas' disease. An updating. *Rev. Inst. Med. trop. S. Paulo*, 35:111-116, 1993.
10. ROSEMBERG, S.; CHAVES, C.J.; HIGUCHI, M.L. et al. – Fatal meningoencephalitis caused by reactivation of *Trypanosoma cruzi* infection in a patient with AIDS. *Neurology*, 42:640-642, 1992.
11. VILLELA, E. & VILLELA, E. – Elementos do sistema nervoso central parasitados pelo *T. cruzi*. *Mem. Inst. Oswaldo Cruz*, 26:77-79, 1932.
12. QUEIROZ, A.C. – Tumor-like lesion of the brain caused by *Trypanosoma cruzi*. *Amer. J. trop. Med. Hyg.*, 22:473-476, 1973.