

## HISTOPATHOLOGY OF CUTANEOUS AND MUCOSAL LESIONS IN HUMAN PARACOCCIDIOIDOMYCOSIS

Fabio URIBE (1), Angela I. ZULUAGA (1), Walter LEÓN (2) & Angela RESTREPO (1)

### SUMMARY

Biopsies from cutaneous and mucosal lesions from 40 patients with active paracoccidioidomycosis, were studied histopathologically. All cases exhibited chronic granulomatous inflammation and 38 also presented suppuration; this picture corresponded to the mixed mycotic granuloma (MMG). Pseudoepitheliomatous hyperplasia and the transepidermic (or epithelial) elimination of the parasite, were observed in all cases. In paracoccidioidomycosis elimination takes place through formation of progressive edema, accompanied by exocytosis. The edema gives rise to spongiosis, microvesicles and microabscesses which not only contain the fungus but also, various cellular elements.

Cells in charge of the phagocytic process were essentially Langhans giant cells; PMN's, epithelioid and foreign body giant cells were poor phagocytes. An additional finding was the presence of fibrosis in most biopsies.

**KEY WORDS:** Paracoccidioidomycosis — Histopathology; Mixed mycotic granuloma; Transepithelial elimination of parasites.

### INTRODUCTION

The histopathologic examination of the tegumentary lesions produced by the various subcutaneous and systemic mycoses, is usually performed with the aim of establishing a diagnosis. Consequently, finding and identifying the microorganism in the tissues constitutes a more important task than studying the host's response to fungal invasion<sup>3</sup>.

There is agreement between pathologists and mycologists concerning the characteristic of the various fungal structures in tissues. However, the interpretation of the tissue alterations caused by the presence of the etiologic agent, is far from being homogenous. Focusing the attention on paracoccidioidomycosis, some authors consider that, at the skin level,

the presence of polymorphonuclear neutrophils (PMN's) is due to ulceration and secondary infection of the granulomas<sup>1</sup>. Others believe that the intraepidermic microabscesses frequently observed in this disease, are the result of the predilection shown by *P. brasiliensis* for the epithelial cells; this, in turn, causes acantholysis and cavity formation, with the PMN's penetrating into the interior of such cavities<sup>5</sup>.

In a previous publication, we attempted to define the physiopathology of the skin granulomata in various mycoses common to the tropics<sup>15</sup>. It was found that in some of these mycoses the various elements constituting the granuloma, that is, mature macrophages such as histiocytes, epithelioid cells and/or giant cells,

(1) Corporación para Investigaciones Biológicas (CIB), Hospital Pablo Tobón Uribe, Medellín, Colombia.

(2) Sección de Dermatología, Hospital Universitario San Vicente de Paul, Medellín, Colombia.

Presented at the International Colloquium on Paracoccidioidomycosis, Medellín, Colombia, February 1986.

Address for reprints: Fabio Uribe, M.D., Corporación para Investigaciones Biológicas, Apartado Aéreo 7378, Medellín, Colombia, South America.

were arranged in a compact formation and appeared free of other inflammatory cell components such as PMN's. To this group belonged histoplasmosis and Lobo's disease. On the other hand, chromoblastomycosis, sporotrichosis and paracoccidioidomycosis, presented a granuloma which was deeply modified by the presence of such PMN's<sup>11,15</sup>. According to PINKUS<sup>14</sup> the latter type of granuloma should be designated as "mixed granuloma"; we have adopted the term mixed mycotic granuloma (MMG) to differentiate it from other mixed granulomata described by the same author<sup>14</sup>. Furthermore, the MMG may appear in two forms, one in which the granuloma is organized in three concentric zones, as formerly described for sporotrichosis by the BEURMAN and GOUGEROT<sup>6,7</sup>. The second type of MMG contains all the above elements but they appear distributed at random in a disorganized fashion, probably as a result of long-standing disease<sup>1,3,5,9,10,11,12,15</sup>.

An additional important characteristic of the MMG is the active participation exhibited by the stratified epithelium covering the lesions. Often, this epithelium gives rise to pseudoepitheliomatous hyperplasia which is conducive to transepidermic or transepithelial elimination of the fungus<sup>2,15,16</sup>.

This study presents data pertaining to the histological reactions occurring in the integuments as a result of the invasion by *P. brasiliensis*, with emphasis on its physiopathology.

#### MATERIAL AND METHODS

Forty biopsy specimens obtained from patients with active paracoccidioidomycosis were studied. Of these, 25 corresponded to mucosal and 15 to skin lesions. Concerning the former, 22 were obtained from the oral cavity, 2 from the larynx and 1 from the epiglottis. In the skin, 9 of these specimens came from the face, 2 from the neck; the remaining 4 were taken from scrotum, back, toe and heel, respectively.

Several non-consecutive sections were obtained from each of the 40 paraffin embedded specimens and stained by the H & E technique; there were a total of 365 sections (8.5 sections per biopsy). Additionally, 22 biopsies were stained by the silver methenamine staining method (2 sections per biopsy).

In the H & E stained sections the following parameters were analyzed:

- a. The characteristics of the cellular infiltrate, both in the dermis and the epithelium.
- b. The way in which the various cellular elements in the infiltrate associated to constitute the MMG.
- c. The alteration of the stratified epithelium covering the lesion and its participation in the transepidermic (or transepithelial) elimination of the fungus.
- d. The phagocytic process in relation to the type of cell (polymorphonuclear or monocyte), performing such function.
- e. The appearance of dermal fibrosis.

In the silver methenamine slides, the size of the fungal cells was recorded; measurements were taken with the use of an ocular micrometer disc previously calibrated against a stage micrometer slide.

#### RESULTS

The H & E stained sections revealed that there were no major differences between lesions of the mucosae and lesions of the skin. Consequently, the results will be analyzed together.

The characteristic of the infiltrate in the dermis (or the submucosae) are presented in Table 1. It can be seen that among the cells representing the polymorphonuclear phagocytic system, PMN's were present in 38 of the 40 cases (95.0%). Eosinophils were observed in only half of the cases. As far as the mononuclear phagocytes, epithelioid cells were observed in 33 biopsies (82.5%), Langhans giant cells in 40 (100%) and foreign body giant cells in 24 cases (60%). Other cellular elements found were lymphocytes or histiocytes (37 cases, 92.5%) and plasma cells (28 cases, 70%).

Regarding the various elements constituting the MMG, we found that most cases (28 or 70.0%) had all the constitutive elements present but that they were not organized in the classic, three zone pattern. The latter formation was observed in 10 biopsies (25.0%) (Fig. 1), but always in conjunction, in the same or in a different tissue section, with the unorganiz-

**T A B L E I**  
Characteristics of the dermal infiltrate in 40 cases of active paracoccidioidomycosis

Elements in the infiltrate	Cases	
	No.	%
<b>Polymorphonuclear phagocytic system</b>		
neutrophils	38	95
eosinophils	20	50
<b>Mononuclear phagocytic system</b>		
epithelioid cells	33	82.5
foreign body giant cells	24	60.0
Langhans giant cells	50	100
<b>Other elements:</b>		
lympho-and histiocytes	37	92.5
plasma cells	28	70.0

ed MMG. In 2 (5.0%) biopsies, we observed the granulomatous components but not the suppurative counterpart; these were punch biopsies from skin lesions.

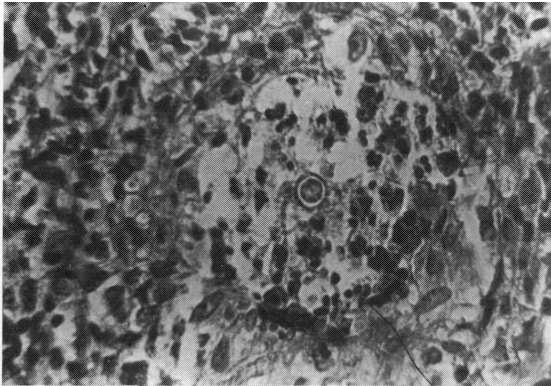


Fig. 1 — Mixed mycotic granuloma (MMG) presenting the 3-zone arrangement; fungus in the center, surrounded by the suppurative and the granulomatous areas and by granulation tissue at the periphery (X 415).

When studying the alterations of the stratified epithelium (Table 2), we observed that all biopsies exhibited pseudoepitheliomatous hyperplasia. Progressive edema was observed regularly and was accompanied by formation of spongiosis in 37 cases (92.5%), of microvesicles in 35 (87.5%), of microabscesses in 30 (75.0%) and of acantholytic cells in 16 (40%) (Fig. 2).

In the edematous areas of the epithelium, the cells of the infiltrate (Table 3), were of various types. The phagocytic polymorphonuclear system was represented by PMN's (37 cases,

**T A B L E II**  
Changes occurring in the stratified epithelium in 40 patients with active paracoccidioidomycosis

Type of change	Cases	
	No.	%
<b>Pseudoepitheliomatous hyperplasia</b>	40	100.0
<b>Edema: various stages</b>		
— intercellular (spongiosis)	37	92.5
— microvesicles	35	87.5
— microabscesses	30	75.0
— acantholytic cells	16	40.0

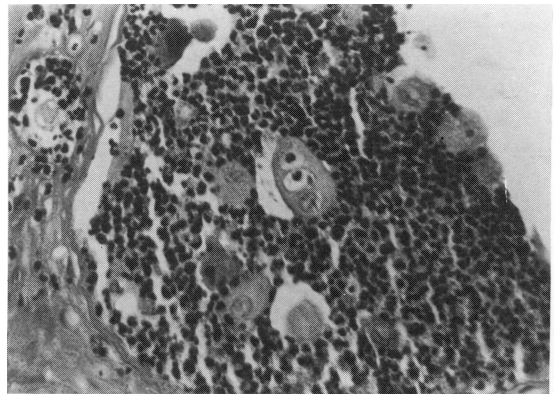


Fig. 2 — Acantholytic cells: a consequence of both the edema and the cellular infiltrate (X 166).

92.5%) and eosinophils (20 or 50%). The mononuclear phagocytic system had a predominance of both epithelioid and Langhans giant cells, 23 cases each (57.5%); foreign body giant cells were less frequent, 6 cases (15.0%). Lymphocytes-histiocytes were common cells, 39 cases (97.5%); plasma cells, on the other hand, were scarce (9 cases or 22.5%).

As shown in Table 4, the study of the trans-epithelial elimination of the fungus, revealed that although the microorganism was seen both within the spongiotic areas (12 cases, 30.0%) and the microvesicles (11 or 27.5%), most of the fungal cells were lying in the micro-abscesses (23 cases, 57.5%) (Fig. 3).

The interaction between the fungal cells and the phagocytes was complex. In certain proportion (27 cases, 67.5%), PMN's were seen surrounding the fungus; however, we were unable to show, with the optical microscope, that such cells had phagocytized the fungus. Eosino-

T A B L E III  
Characteristics of the epithelial infiltrate in 40 cases of active paracoccidioidomycosis

Elements in the infiltrate	Cases	
	No.	%
Polymorphonuclear		
Phagocytic system		
neutrophils	37	92.5
eosinophils	20	50.0
Mononuclear phagocytic system		
epithelioid cells	23	57.5
foreign body giant cells	6	15.0
Langhans giant cells	23	57.5
Other elements:		
Lympho-and histiocytic infiltrate	39	97.5
Plasma cells	9	22.5

T A B L E IV  
Transepithelial elimination of *P. brasiliensis* in 40 patients with active paracoccidioidomycosis

Location of <i>P. brasiliensis</i> in tissue	Cases	
	No.	%
Spongiotic area	12	30.0
Microvesicles	11	27.5
Microabscesses	23	57.5

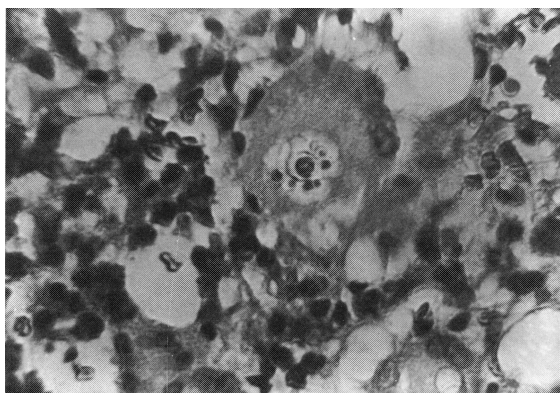


Fig. 3 — Fungal cell in a microabscess, nearby the elimination surface (X 133)

phils were not seen interacting with the fungus. Concerning the mononuclear phagocytes, the epithelioid cells and the foreign body giant cells were seldom seen in contact with *P. brasiliensis*. The most active phagocytic cell proved to be the Langhans giant cell, which was seen to have ingested the fungus in 39 of the 40 cases (97.5%). Notwithstanding, *P. brasiliensis* cells were found multiplying and budding inside of the Langhans phagocytic cells (19 cases, 47.5%) (Fig. 4). In some epithelial

cells, specially acantholytic ones, we observed inclusions which could have corresponded to fungal cells as described by BRITO et al<sup>5</sup>, but which were not furtherly identified.

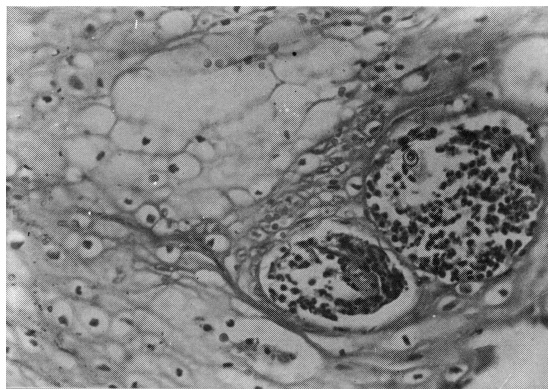


Fig. 4 — *P. brasiliensis* producing multiple buds inside a phagocytic Langhans giant cell (X 600).

It was interesting to note that the phagocytic activity of the Langhans cells extended to other tissue elements. Thus, in 31 biopsies (77.5%), these cells appeared phagocytizing erythrocytes, PMN's (Fig. 5), eosinophils, lymphocytes, cellular debris and even collagen fibers. Foreign body giant cells, on the other hand, were seen interacting with tissue elements in only 4 cases (10%).

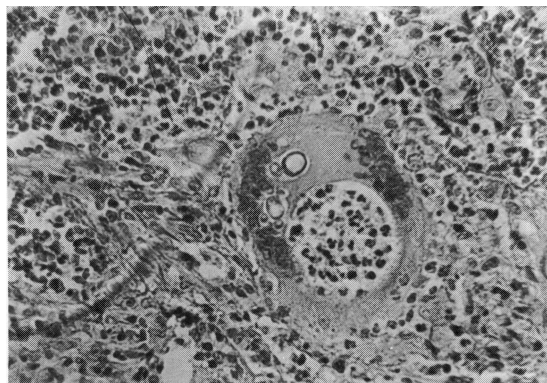


Fig. 5 — Langhans giant cell engulfing PMN's and *P. brasiliensis* (X 333).

Another tissue change that was frequently observed was fibrosis, occurring both in the dermis and submucosae. Fibrosis was recorded in 34 of the specimens processed (85.0%).

Concerning the size of the fungal cells, they ranged from 5 to 10 micra. Larger yeast cells (over 11 micra) were the predominating struc-

ture in 3 of the 22 specimens studied by the silver methenamine stain. In the remaining 19 cases (86.2%) the yeast cells were smaller (5-10 micra). Those biopsies with larger cells had few microorganisms and they appeared degenerated. On the other hand, the smaller yeast cells were present in abundance and appeared intact.

## DISCUSSION

The results of this study confirm previous publications<sup>11,15</sup>, concerning the type of granulomatous reaction occurring in paracoccidioidomycosis, namely, the mixed mycotic granulomata (MMG). Thirty-eight of the 40 biopsies exhibited both granulomatous and suppurative reactions. In the remaining 2 cases, such association was not visualized probably because of the small size of the specimens.

In spite of the fact that all the elements which integrated the granuloma were observed in the various specimens, they were associated in a disorganized fashion. Only in 10 biopsies was classic, 3-zone arrangement, observed. This is the elemental histological unit which explains the pathogenesis of the lesions<sup>15</sup>. Thus, the arrival of the fungus into the tissues induces the influx of PMN's, which surround the microorganism, forming a well-delimited microabscess (central, suppurative zone)<sup>8,15</sup>. PMN's fail to arrest fungal multiplication and mononuclear phagocytic cells, — especially epithelioid and Langhans giant cells — come into play; these, in turn, surround the microabscess (granulomatous zone), in an attempt to wall-off the infection. Failure ensues at this level too and giant cells which had previously ingested the fungus, are damaged, liberating fungal cells, some of which had already multiplied. Freed fungal cells attract a fresh wave of PMN's and a new cycle begins<sup>4,16</sup>. There is, finally, a third zone formed by granulation tissue, rich in blood vessels, characterized by a dense infiltrate of lymphocytes, histiocytes and plasma cells<sup>6,14</sup>.

It was interesting to observe that both the dermis and the epithelium had a similar cell infiltrate of PMN's (95% and 92.5%, respectively), as well as eosinophils (50% in both); on the other hand, the dermis had a larger proportion of giant cells than the epithelium, 60% vs. 15% for the foreign body type and 100% vs. 57.5% for the Langhans type. Epithelioid cells were

observed in the same proportion at both levels, 60.0 and 57.7%, and the same happened with lymphocytes and histiocytes (92.5 and 97.5%), but not with plasma cells (70.0 vs. 22.5%).

In those diseases characterized by formation of the MMG, such as chromoblastomycosis and sporotrichosis<sup>2,5</sup>, the stratified epithelium covering the lesions plays an active role in shaping the histologic appearance of the lesion as well as in the transepithelial elimination of *P. brasiliensis*. We observed pseudoepitheliomatous hyperplasia in all the biopsies we studied; this is not a new finding as it has been reported previously<sup>1,3,9,11,12</sup>. We believe that in paracoccidioidomycosis, the elimination takes place by a different system to the one exhibited by the other mycoses, namely, formation of a progressive edema which, in turns, gives rise to intraepithelial cavities. Initially, there is spongiosis with the intercellular bridges becoming clearly visible and with lymphocytes and PMN's accumulating at the site; these changes were observed in most of our biopsies (92.5%). The spongiotic changes had been previously observed by FRANCO and MONTENEGRO<sup>9</sup>, but had not been interpreted as part of the elimination process. With time and with the progression of the edema and the rupture of the intercellular bridges, microvesicles are formed; this type of alteration was recorded in 75% of our cases. When various microvesicles coalesce, they form larger cavities, which become filled with PMN's and form microabscesses; such a change occurred in 75.0% of the specimens we examined. The edema and the infiltrate may also result in formation of acantholytic cells; these were recorded in 40.0% of the biopsies studied.

Based on the present findings, it is clear that transepithelial elimination does indeed occur in paracoccidioidomycosis albeit by a different procedure.

The cellular infiltrate which accompanies the fungus in the microabscesses, stems from those cells which, at the beginning of the process, had originated in the dermis. Such a cellular infiltrate, fills the edema resulting cavities<sup>12</sup>. It was through these micro-abscesses that 57.5% of the fungal elimination took place in this study. In lesser proportion, the fungus was also eliminated by means of the microvesicles (27.5%) and the spongiotic areas (30.0%). It

should be recalled that the natural upward movement of all cells from the basal layer to the surface is the driving force of the transepithelial elimination<sup>12</sup>.

The interaction between the fungal elements and the various phagocytic cells was revealing. Although PMN's approached the fungus (67.5%), it appeared that they were unable to phagocytize the parasite, as has been previously shown by others<sup>4,8,13</sup>. The epithelioid — and the foreign body — giant cells were not very active in the phagocytic process, as described by HIRSCH<sup>10</sup>; on the other hand, the Langhans giant cells were able to engulf the fungus (97.5%). That this type of giant cell is quite active in paracoccidioidomycosis was demonstrated earlier by FRANCO and MONTENEGRO<sup>9</sup>. Also, their ability to phagocyte other tissue elements such as PMN's, plasma cells and collagen fibers had been previously reported by URIBE et al.<sup>5</sup>.

In the integument, as well as in the lungs, healing of the paracoccidioidomycotic lesions takes place by fibrosis<sup>1,3,9,11</sup>. A large proportion (85%) of the lesions whether in the skin or in the mucosae, presented such a change, indicating that this is a peculiarity of paracoccidioidomycosis.

## RESUMO

### Histopatologia de lesões cutânea e mucosa em paracoccidioidomicose humana

Biopsias de lesões cutânea e mucosa de 40 pacientes com paracoccidioidomicose ativa foram estudadas em seu aspecto histopatológico. Todos os casos mostravam inflamação granulomatosa crônica e 38 também apresentavam supuração; este quadro correspondia ao granuloma micótico misto (MMG). A eliminação do parasita ocorre através da formação de edema progressivo, acompanhado por exocitose. O edema evolui a espongióse, microvesículas e microabscessos que não só contém o fungo, mas também vários elementos celulares. As células encarregadas do processo fagocitário eram essencialmente células gigantes de Langhans; polimorfonucleares, células epitelióides e células gigantes de corpos estranhos eram fagócitos pobres. Um achado adicional foi a presença de fibrose na maioria das biópsias.

## ACKNOWLEDGEMENTS

The authors express their sincere appreciation to Dr. Raul Jimenez of the Department for Oral Pathology, School of Dentistry, University of Antioquia, for his kindness in furnishing us with several biopsy specimens for our study. Thanks are also expressed to Maria E. Salazar, M.T., who kindly cooperated with the photographic studies.

## REFERENCES

1. ANGULO-ORTEGA, A. & POLLAK, L. — Paracoccidioidomycosis. In: BAKER, R. D., ed. — The pathological anatomy of the mycoses. Berlin, Springer Verlag, 1971. p. 507-576.
2. BATRES, E.; WOLF, J. E.; RUDOLF, A. H. & KNOWX, J. M. — Transepithelial elimination of cutaneous chromomycosis. *Arch. Derm.*, 114: 1231-1232, 1978.
3. CHANDLER, J. A.; KAPLAN, W. & AJELLO, L. — Color atlas and text of the histopathology of mycotic diseases. Chicago, Year Book Medical Publishers, 1980. p. 88-91; 246-252.
4. DAHL, M. — Clinical immunodermatology. Chicago, Year Book Medical Publishers, 1981. p. 134.
5. De BRITO, T.; FURTADO, S. J.; CASTRO, M. & MANINI, M. — Intraepithelial parasitism in human paracoccidioidomycosis (South American Blastomycosis). *Virchows. Arch. path. Anat.*, 351: 129-138, 1973.
6. De BEURMAN, L. & GOUGEROT, H. — Les sporotrichoses. Paris, Felix Alcon, 1912.
7. De GRACIANSKY, P. & BROULLE, S. — Sporotrichose. Atlas de Dermatologie. Paris, Librairie Malone, 1952. v. 9, p. 1-6.
8. FLEISCHMAN, J. & LEHRER, R. I. — Phagocytic mechanisms in host response. In: HOWARD, D. H., ed. — Fungi pathogenic for humans and animals. Part B: Pathogenicity and detection. New York, Marcel Dekker, 1985. p. 123-149.
9. FRANCO, M. F. & MONTENEGRO, M. R. G. — Anatomia patológica. In: DEL NEGRO, G.; LACAZ, C. S. & FIORILLO, A. M. — Paracoccidioidomicose (Blastomycose Sulamericana). São Paulo, Sarvier, 1982. p. 97-117.
10. HIRSCH, B. C. & JOHNSON, W. C. — Concepts of granulomatous inflammation. *Int. J. Derm.*, 23: 90-100, 1984.
11. HIRSCH, B. C. & JOHNSON, W. C. — Pathology of granulomatous diseases. Mixed inflammatory granulomas. *Int. J. Derm.*, 23: 585-597, 1984.
12. LEVER, F. & SCHAUMBURG-LEVER, G. — Histopathology of the skin. 6th ed. Philadelphia, Lippincott, 1983. p. 346-347.

13. MENDES, E. — *Imunopatologia*. São Paulo, Sarvier, 1980. p. 201-208.
14. PINKUS, H. & MEHREGAN, A. H. — *A guide to dermatohistopathology*. 3rd.ed. New York, Appleton Croft, 1981. p. 247-259.
15. URIBE, F.; LEÓN, W. & VELASQUEZ, J. P. — Modificaciones tisulares a nivel de la piel en algunas micosis. *Acta med. colomb.*, 7: 171-179, 1982.
16. URIBE, F.; ZULUAGA, A.; LEÓN, W. & RESTREPO, A. — Aspectos histológicos de la esporotricosis y búsqueda del agente etiológico por métodos inmunoenzimáticos. *Acta med. colomb.*, 10: 65-74, 1985.

---

Recebido para publicação em 3/9/86.