

IMMUNOHISTOCHEMICAL CHANGES IN KIDNEY GLOMERULAR AND TUBULAR PROTEINS CAUSED BY RATTLESNAKE (*Crotalus vegrandis*) VENOM

María E. GIRÓN(1), Irma AGUILAR(1) & Alexis RODRÍGUEZ-ACOSTA(2)

SUMMARY

Renal damage is an important cause of death in patients who have survived the early effects of severe crotalid envenomation. Extracellular matrix of renal tissue is altered by *Crotalus* toxin activities. The aim of this study was to describe how cytoskeletal proteins and basal membrane components undergo substantial alterations under the action of *Crotalus vegrandis* crude venom and its hemorrhagic fraction (Uracoina-1) in mice. To detect the proteins in question, the immunoperoxidase method with monoclonal and polyclonal antibodies was used. Cell types within renal lesions were characterized by phenotypic identification, by means of immunohistologic analysis of marker proteins using different primary antibodies against mesangial cells, endothelial cells, cytoskeletal proteins (intermediate filament), extracellular matrix and basal membranes. Samples for morphological study by standard procedures (biotin-streptavidin-peroxidase technique) using light microscopy were processed. Positive and negative controls for each antigen tested in the staining assay were included. After crude venom and hemorrhagic fraction inoculation of mice, the disappearance of cytoskeletal vimentin and desmin and collagen proteins in the kidney was observed. In extracellular matrix and basal membranes, collagen type IV from envenomed animals tends to disappear from 24 h to 120 h after venom injection.

KEYWORDS: Collagen; *Crotalus vegrandis*; Extracellular matrix; Kidney; Laminin; Venom; Vimentin.

INTRODUCTION

The incidence of snakebites in Venezuela is approximately 5000 each year, with *Crotalus* representing about 12%³ of the envenomed cases. *Crotalus vegrandis* is a small rattlesnake living in a circumscribed eastern area of Monagas State, Venezuela. Its toxic activity produces neurotoxicity, respiratory paralysis, hypotension, shock, acute renal insufficiency³², myotoxicity²⁹, hepatotoxicity³⁵ and hemorrhagic alterations^{2,16,32,34}. *C. vegrandis* incidence is not known, and has probably been underestimated since many cases are not reported.

It is well known that acute renal failure is an important cause of death in patients who have suffered severe crotalid envenomation³¹. The essential cause of this renal failure seems to be a tubular necrosis. However, the pathophysiological mechanisms which play a part in the development of the necrosis are not known. Alterations in glomerular and tubular extracellular matrix following injection of snake venom have been demonstrated in Asian snakes (*Trimeresurus flavoviridis*)⁷, but as far as we know studies of glomerular and tubular immunohistochemical alterations following injection of rattlesnake venom have not been carried out. The objective of this study was to investigate the glomerular and tubular extracellular matrix component alterations after uracoan rattlesnake (*Crotalus vegrandis*) venom injection in mice. Cytoskeletal

proteins (vimentin and desmin) and basal membrane components (collagen type IV) were assessed by immunohistochemical identification in serial time studies from 24, 48, 72, 96 and 120 hours after venom injection.

MATERIALS AND METHODS

Venom from *C. vegrandis* captive specimens at the serpentarium of the Tropical Medicine Institute of Universidad Central de Venezuela was used. The fresh venom was lyophilised, kept at -80 °C and protected from light until used. To obtain the hemorrhagic fraction (Uracoina-1), the method of AGUILAR *et al.* (2001)² was utilized. Briefly, the crude venom (10 mg by protein estimation) was dissolved in 0.5 mL of ammonium acetate buffer pH 6.9 and loaded on to a Waters Protein Pack SW300 (10-400 kDa) filtration column (BioRad, Biologic Work station). The column was eluted step-wise, and 0.3 mL fractions using ammonium acetate buffer pH 6.9 were collected. The fraction with hemorrhagic activity was re-chromatographed in an anionic exchange column (mono-Q2) (Bio-Rad), using Tris-HCl 25mM (pH 8.0) buffer and a gradient of 0-75% 1M NaCl. A fraction (uracoina-1) was obtained and homogeneity was monitored by SDS-PAGE and silver stain¹⁸. Its hemorrhagic activity was evaluated¹⁷. The investigation complies with the norms taken from the guide "Principles of laboratory animal care"¹⁴.

(1) Scientific Research Assistant, Immunochemistry Section, Tropical Medicine Institute, Universidad Central de Venezuela, Caracas 1041, Venezuela.

(2) Full Professor of Tropical Medicine, Tropical Medicine Institute, Universidad Central de Venezuela, Caracas 1041, Venezuela.

Correspondence to: Alexis Rodriguez-Acosta, MD PhD, Apartado 47423, Caracas 1041, Venezuela, E-mail: rodriguf@camelot.rect.ucv.ve

To detect the proteins studied, the immunoperoxidase method with monoclonal and polyclonal antibodies was employed. The technique included a phase of recovery of antigenic markers, thus overcoming the main drawback of this method. This technique has the advantages of preserving the preparations indefinitely and allowing precise localization of the structures. Cell types within renal lesions were characterized by phenotypic identification using immunohistologic analysis of marker proteins, with the following primary antibodies: mesangial cells: mouse monoclonal anti- α smooth muscle actin (Dako Corporation, Carpinteria, California); endothelial cells: mouse monoclonal anti-human Factor VIII (Von-Willebrand factor) (Dako Corporation, Carpinteria, California); cytoskeletal proteins (Intermediate Filament): mouse monoclonal anti-purified pig cristallin-vimentin (Dako Corporation, Carpinteria, California) and rabbit polyclonal anti-chicken gizzard smooth muscle desmin (Dako Corporation, Carpinteria, California); extracellular matrix and basal membranes: mouse monoclonal anti-human collagen type IV (Sigma - Aldrich, Inc, USA), mouse monoclonal anti-human breast cancer fibronectin (Sigma, Aldrich, Inc, USA) and mouse monoclonal anti-human purified laminin (Sigma, Aldrich, Inc, USA).

Two groups of six NIH Swiss albino mice were inoculated intraperitoneally with a sublethal dose of crude venom 2.6 $\mu\text{g}/20\text{ g}$ mouse weight, and Uracoina-1 with 80 $\mu\text{g}/20\text{ g}$ mouse weight, respectively. Control group inoculated with saline solution was also studied. The samples for morphological study were processed following HSU *et al.* (1981)¹⁹. All tissues (one animal per time) were obtained from the same strain of animals and processed under the same protocol. Briefly, animals were sacrificed at preset serial times, after the crude venom or Uracoina-1 injection. These times were 24, 48, 72, 96 and 120 hours in the case of crude venom and 24 hours for Uracoina-1. Samples from renal tissue were divided in pieces, fixed in Bouin's solution and embedded in paraffin (Paraplast: Monoject Scientific, Ireland) by standard procedures for light microscopy. Sections 4-6 μm were transferred to plastic Coplin jar and processed for antigenic marker recovery with citrate buffer. This recovery is carried out by means of the application of repeated cycles of heating in microwave oven. The cycles were of five min followed by a cycle of 2:30 min, then six cycles of 1:15 min each, stuffing the Coplin jar with citrate buffer whenever necessary. Once the process of recovery of antigenic markers was completed and the buffer had cooled down, the slides were washed with tap water for 10 minutes and treated with 80% methyl alcohol containing 0.6% hydrogen peroxide for 15 min to eliminate non-specific endogenous peroxidase. They were then washed with tap water for 5-10 minutes and the sections were circled with a permanent-mark pen, placed in a humid chamber, covered with primary antibody and left to incubate at room temperature for one hour. The slides were then washed in Tris-saline buffer (TSB) for five minutes. After washing in TSB the sections were treated with biotinylated secondary antibody and incubated for 20 minutes at room temperature. The slides were washed for five minutes in two changes of TSB and the sections were heated with streptavidin-peroxidase complex for 20 minutes at room temperature, washed again in TSB for five minutes, treated with chromagin (DAB) for 10 min and washed in running tap water for three minutes. They were then counter-stained with Mayer's haematoxylin for 1-3 minutes, washed in water, dipped in Scott's solution, washed in water again, dehydrated in 70-99% alcohol, cleared in xylol and mounted. Positive and negative controls for each antigen tested were included in each staining procedure.

Lethal dose 50 (LD50) was determined in NIH Swiss albino mice by the Reed and Muench method³⁰. Six groups of five mice per dose weighing 20-22 g were injected intraperitoneally with 200 μL of serially diluted hemorrhagic fraction or crude venom from two to 200 μg . The animals were accommodated in boxes and observed throughout the observation period of 48 hours.

Hemorrhagic activity was determined by the KONDO *et al.* method²³ modified by GUTIERREZ *et al.*¹⁷. Crude venom or purified toxins were tested. One hundred microlitres of Uracoina-1 or crude venom containing 5-50 μg were injected intradermally into the abdominal skin of four male NIH Swiss albino mice. The mice were sacrificed after two hr, and the inner surface was observed for hemorrhage. The minimum hemorrhagic dose (MHD) was defined as the amount of enzyme that induced a hemorrhagic area of 10 mm diameter calculated with a calliper²⁷.

RESULTS

With respect to LD50 (tested for 48 h), Uracoina-1 was not lethal to mice even when a dose of 80 $\mu\text{g}/20\text{ g}$ mouse weight was administered intraperitoneally, while crude venom had a LD50 of 3.2 $\mu\text{g}/20\text{ g}$ mouse weight. Uracoina-1 had hemorrhagic activity when tested by intradermal injections in mice. The minimum hemorrhagic dose was 4.7 μg , indicating that Uracoina-1 was more active than crude venom, which had a 12 μg MHD. All animals tested with the sublethal doses survived and were used for the present study, although all of them developed the changes described.

A summary of the results using primary antibodies is shown in Table 1. Anti- α -smooth-muscle actin (SMA) did not show any change in the experimental animals and had similar intensity in all cases observed (24, 48, 72, 96 and 120 hours of crude venom inoculation and hemorrhagic fraction).

At 24 hours of inoculation SMA was slightly positive in glomeruli in the mesangial region and strongly positive in blood vessels.

Anti-factor VIII was only detected in the positive control of the technique (lingual endothelia). It was not detected in the kidneys of either control or envenomed animals. Anti-vimentin presence was especially evident in control mice, being strongly positive in glomeruli, blood vessels and connective tissue (Fig. 1). Vimentin tended to disappear in the envenomed animals, in contrast to the control mice: it was impossible to detect after 120 h of crude venom injection (Fig. 1a) and 24 hours after inoculation with Uracoina-1 (Fig. 1b).

Anti-desmin peritubular and glomerular capillaries of control mice were positive (Fig. 2). Their presence disappeared in samples from envenomed animals (crude venom) (Fig. 2a) and 24 hours after inoculation with Uracoina-1 (Fig. 2b).

In extracellular matrix and basement membranes, anti-collagen type IV was strongly revealed in control animals (showing positive reaction in tubular and glomerular basement membranes) (Fig. 3). In contrast, in envenomed animals injected with crude venom, collagen type IV tended to disappear from 24 h to 120 h post- injection, after which it was impossible to be detected (Fig. 3a). It also totally disappeared at 24 hours after inoculation in animals injected with Uracoina-1 (Fig. 3b).

Table 1
Immunohistochemical (immunoperoxidase) staining of extracellular matrix and intermediate filament components in kidney specimens from mice intraperitoneally injected with *C. vegrandis* crude venom and hemorrhagic fraction (Uracoína-1)

Primary antibody	Positive control	Dilution	Control mice	Envenomed mice
Anti- α -smooth muscle-actin	Oesophagi	1/50	+	+
Anti-associated antigen-Factor VIII	Tongue	1/50; 1/25; 1/10	Not detected	Not detected
Anti-vimentin	Tongue	1/200	+	-
Anti-desmin	Tongue	1/200	+	-
Anti-collagen IV	Breast tumour	1/100	+	-
Anti-laminin	Kidney	1/50	+	+
Anti-fibronectin	Breast tumour	1/100	+	+

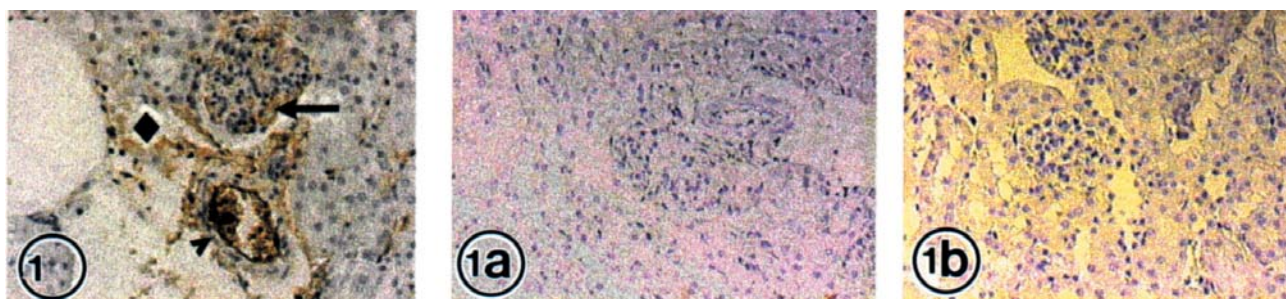


Fig. 1 - Vimentin localization was evident in control mice, mainly in glomeruli (arrows) blood vessels (arrowhead) and connective tissue (rhombus). X 20. **1a** - Vimentin localization disappears 120 h of crude venom injection. **1b** - Vimentin localization disappears 24 hours after inoculation with Uracoína-1. X 20.



Fig. 2 - Desmin in control mice peritubular (arrow) and glomerular capillaries (stars) were positive. X 20. **2a** - Desmin localization disappears 24 hours after inoculation with crude venom. X 20. **2b** - Desmin localization disappears 24 hours after inoculation with Uracoína-1. X 20.

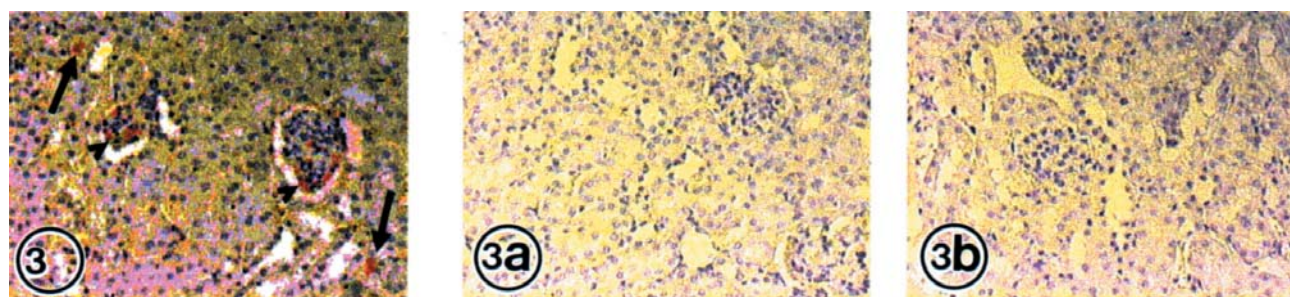


Fig. 3 - Collagen type IV control was expressed on tubular (arrows) and glomerular basal membrane (arrowhead). X 20. **3a** - Collagen type IV localization disappears at 120 h of crude venom injection. X 20. **3b** - Collagen type IV localization disappears at 24 h after Uracoína-1 injection. X 20.

Anti-laminin and anti-fibronectin had similar intensity in all experimental and control samples. For this reason these results are not shown. A positive reaction could be noticed in all the observed basement membranes, especially in tubules.

DISCUSSION

One of the motivations behind this study was six cases of *Crotalus vegrandis* envenomation attended by the Tropical Medicine Institute Consulting Department, all of which involved severe complications. Two of the five patients who were admitted more than eight hours post-bite developed acute renal failure. There was a significant association between both total lactic dehydrogenase and creatin-phospho-kinase blood enzyme levels and severity. All patients recovered and no deaths were documented (Serpentarium of the Tropical Medicine Institute Medical Archives).

Studies of structural and ultrastructural (transmission electron microscopy) damage induced by *C. vegrandis* crude venom or Uracoína-1¹⁶ and/or neurotoxic fractions involve glomerulus, proximal tubules and interstitium, producing lesions different from those previously described with *Trimeresurus flavoviridis* venom^{13,14}, *Agkistrodon acutus* venom³⁶ and *Bothrops jararaca* venom¹², among others. With light microscopy, crude venom produced a cytoplasmic edema in tubular cells, marked peritubular congestion and an interstitial edema. Uracoína-1 caused accentuated congestion of the peritubular and glomerular capillaries. It is important to emphasize that the events that take place in the genesis of the lesion seem to be regulated by factors of growth or cytokines synthesized by cells present in the lesion^{8,10,11,16,18,25}. These factors are able to stimulate or to inhibit cellular proliferation, depending on the state of the cells and of the presence of other growth factors that can regulate the synthesis of the extracellular matrix, as well as the interaction between cells and the extracellular matrix^{7,13}.

The role of the alterations of glomerular and tubular extracellular matrixes in the pathogenesis of renal lesions has been proposed by several authors. SASAKI *et al.* (1999)³⁷ have found that in acute mesangial proliferative glomerulonephritis there is an expansion of the mesangial matrix, especially laminin and collagen type IV caused by galectin-3, which is a beta-galactoside-binding protein synthesized by macrophages and other inflammatory cells. Addition of galectin-3 to primary cultures of mesangial cells prepared from normal rats induces a 1.5-fold increase in the synthesis of collagen type IV. ADHIKARY *et al.* (1999)¹ reported that anti-glomerular basement membrane (GBM) nephritis in Sprague-Dawley (SD) rats was characterized by development of marked glomerular sclerosis and tubulointerstitial fibrosis. To elucidate sequential changes of the mRNA expression of extracellular matrix (ECM) components, they were examined in the glomerulus and cortex during the course of the disease. Accumulation of fibronectin and collagen type I and type IV was noted in the interstitium in association with enhanced expression of mRNA for these ECM components.

Earlier studies utilized desmin, a cytoskeletal protein and smooth muscle cell marker¹⁵, to identify glomerular mesangial cells in normal kidneys⁵. Similarly, in our experiments we have used desmin disappearance 24 h after crude venom and hemorrhagic fraction injections as a pathological sign of mesangial cell lesion.

Vimentin, another protein of intermediate filaments which we

evaluated, had a similar performance to desmin: it completely disappears 24 h after crude venom and hemorrhagic fraction injection. This protein has a structural function, since it represents part of the mechanical support that anchors the cells to the plasmatic membranes, where they enter in contact with other cells or with the extracellular matrix. Its disappearance must necessarily cause serious cytoskeletal alterations.

Several biochemical studies have demonstrated that the hemorrhaging toxins isolated from snake venom are mainly zinc-dependent metalloproteases, which enzymatically degrade extracellular matrix and/or basal membranes, including collagen type IV, laminin, nidogen or entactin and fibronectin^{6,9,28}.

Some authors²⁶ have suggested that the degradation of vimentin filaments and desmin is caused by specific Ca⁺⁺ dependent protease intermediate filaments. This degradation is carried out in two steps: a limited proteolysis leading to the removal of a 9 kDa peptide from the end N-terminus of vimentin and desmin, followed by an additional proteolysis that results in the accumulation of peptides resistant to new degradations²⁶. There is the possibility of venom activity in the extracellular matrix, bearing in mind the proteolytic enzymatic complexity of *Crotalus vegrandis* venom³³.

As mentioned above, *C. vegrandis* venom has a strong hemorrhagic component (Uracoína-1)², which would explain the disappearance of collagen type IV in the envenomed mice. Laminin and fibronectin remain after Uracoína-1 injection, with laminin becoming even more evident in the basal membrane area of experimental animals. Collagen represents the fibrous protein of the extracellular matrix, while fibronectin, laminin and nidogen are multiadhesive proteins.

Laminin is a cross-like protein whose larger axis covers all the basal laminae thickness. It is possible that its presence is more evident in envenomed animals because crude venom and Uracoína-1 may expose the laminin. There were no indications that the laminin was degraded in any region.

In this study α -smooth muscle actin (α -SMA) was revealed in the glomerules, peritubular and glomerular blood vessels and mesangium of control mice, as well as the crude venom and Uracoína-1 envenomed animals. It seems that the venom is not acting on this protein.

Besides the hemorrhagic components, *Crotalus vegrandis* venom is rich in phospholipase A2 enzymes²¹. Crotoxin (phospholipase A), the main toxin in South American crotalid venom, causes lysis of the plasma membrane, producing rapid changes in the internal medium of the cell. The intracellular Ca⁺⁺ level is increased, which could have the following effects: mitochondria Ca⁺⁺ accumulation; Ca⁺⁺ dependent protease activation in the cytoplasm; activation of intracellular phospholipases; and the production of free fatty acids and lysophospholipids, which alter the interactions between the cytoskeletal and membranes leading to activation of lysosomal enzymes²⁶.

The disappearance of protein presence after crude venom and hemorrhagic fraction inoculation was observed in the experiments, with vimentin and desmin cytoskeletal protein completely disappearing under the influence of crude venom and Uracoína-1. This could be explained by venom metalloprotease activity with disintegrin or disintegrin-like domains

(metalloproteases are important components of most crotalid venoms and they are involved in the shedding of molecules from the cell surface)²²; or by degradation of vimentin and desmin filaments by a cytosolic specific Ca⁺⁺ dependent protease in a reaction of limited proteolysis^{20,38}.

In conclusion, perhaps the most important function of vimentin and desmin as components of cytoskeleton protein (intermediate filaments) is to provide mechanical support for plasma membrane where it comes into contact with other cells or with the extracellular matrix and seems to play a general role in maintaining the structural integrity of tissues by mechanically reinforcing the connection between cells²⁴. Vimentin networks may help keep the nucleus and other organelles in a defined place within the cell. Desmin is responsible for stabilizing sarcomeres in contracting muscles. As demonstrated in the present work, alterations induced in extracellular matrix components (collagen Type IV) and the cytoskeleton (vimentin and desmin) by *Crotalus vegrandis* crude venom toxins and Uracoína -1 can lead to a disorganization of the plasma and basal membranes and destruction of their ability to control the internal environment of the glomerular and tubular cells. Therefore, this could set off a sequence of events which results in the death of the cell.

RESUMEN

Cambios inmunohistoquímicos en proteínas de túbulo y glomérulo renal causadas por el veneno de la serpiente de cascabel (*Crotalus vegrandis*)

El daño renal es una causa importante de muerte en pacientes que sobreviven a los efectos iniciales de los severos envenenamientos crotálicos.

El objetivo de este estudio ha sido el describir como las proteínas del citoesqueleto y los componentes de membrana basal muestran alteraciones importantes en su manifestación, bajo la acción del veneno crudo de *Crotalus vegrandis* y una fracción hemorrágica (Uracoína-1) del mismo veneno ya que, la matriz extracelular del tejido renal es alterada por la actividad de estas toxinas.

Para detectar las proteínas en cuestión se utilizó el método de inmunoperoxidasa con anticuerpos mono y policlonales.

Los tipos celulares dentro de las lesiones renales fueron caracterizados por identificación fenotípica, por medio del análisis inmunohistoquímico de diferentes marcadores de proteínas utilizando anticuerpos primarios contra células mesangiales, endoteliales, proteínas de citoesqueleto (filamento intermedio), matriz extracelular y membrana basal.

Se procesaron las muestras para estudio morfológico por procedimientos de rutina (biotina-streptavidina-peroxidasa) y se observaron por microscopía de luz. Fueron incluidos los controles negativos y positivos para cada antígeno probado, en los ensayos de tinción.

Se observó también la desaparición en el citoesqueleto, de la expresión de las proteínas vimentina y desmina, luego de la inyección de veneno crudo y Uracoína-1. En la matriz extracelular y la membrana basal de los animales envenenados, la expresión del anti-colágeno Tipo IV, tiende a desaparecer después de las 24 a las 120 horas de la inyección del veneno.

ACKNOWLEDGEMENTS

The authors thank Dalila Peñaloza for her expert technical assistance. This study was supported by CONICIT (Grant: S1: 96001933).

REFERENCES

1. ADHIKARY, L.P.; YAMAMOTO, T.; ISOME, M. *et al.* - Expression profile of extracellular matrix and its regulatory proteins during the process of interstitial fibrosis after anti-glomerular basement membrane antibody-induced glomerular sclerosis in Sprague-Dawley rats. *Path. Int.*, **49**: 716-725, 1999.
2. AGUILAR, I.; GIRÓN, M.E. & RODRIGUEZ-ACOSTA, A. - Purification and characterisation of a haemorrhagic fraction from the venom of the Uracoan rattlesnake *Crotalus vegrandis*. *Biochim. biophys. Acta (Amst.)*, **1548**: 57-65, 2001.
3. ANONYMOUS - *Oficina Central de Información (OCI)*. In: *Anuario estadístico de Venezuela*. Caracas, Taller Gráfico O.C.E.I, 1999. p. 1-200.
4. ANONYMOUS - *Principles of laboratory animal care*. Maryland, National Institute of Health of United States, 1985. (Publication 85-23. p.1-126).
5. BACHMANN, S.; KRIZ, W.; KUHN, C. & FRANKE, W.W. - Differentiation of cell types in the mammalian kidney by immunofluorescence microscopy using antibodies to intermediate filament proteins and desmoplakins. *Histochemistry*, **77**: 365-394, 1983.
6. BARAMOVA, E.N.; SHANNON, J.D.; BJARNASON, J.B. & FOX, J.W. - Degradation of extracellular matrix proteins by hemorrhagic metalloproteinases. *Arch. Biochem.*, **275**: 63-71, 1989.
7. BARNES, J.L. & ABOUD, H.E. - Temporal expression of autocrine growth factors corresponds to morphological features of mesangial proliferation in Habu snake venom-induced glomerulonephritis. *Amer. J. Path.*, **143**: 1366-1376, 1993.
8. BASSOLS, A. & MASSAGUE, J. - Transforming growth factor beta regulates the expression and structure of extracellular matrix chondroitin/dermatan sulfate proteoglycans. *J. biol. Chem.*, **263**: 3039-3045, 1988.
9. BJARNASON, J.B. & FOX, J.W. - Hemorrhagic toxins from snake venoms. *J. Toxicol. Toxin. Rev.*, **7**: 121-209, 1988-1989.
10. BORDER, W.A.; OKUDA, S.; LANGUINO, L. & RUOSLAHTI, E. - Transforming growth factor- β regulates production of proteoglycans by mesangial cells. *Kidney Int.*, **37**: 689-695, 1990.
11. BORDER, W.A. & RUOSLAHTI, E. - Transforming growth factor-beta 1 induces extracellular matrix formation in glomerulonephritis. *Cell Differ. Dev.*, **32**: 425-431, 1990.
12. BURDMANN, E.A.; WORONIK, V.; PRADO, E.B.A. *et al.* - Snakebite-induced acute renal failure: an experimental model. *Amer. J. trop. Med. Hyg.*, **48**: 82-88, 1993.
13. CATTELL, V. & BRADFIELD, J.W.B. - Focal mesangial proliferative glomerulonephritis in the rat caused by Habu snake venom. A morphologic study. *Amer. J. Path.*, **87**: 511-524, 1977.
14. CATTELL, V. - Focal mesangial proliferative glomerulonephritis in the rat caused by Habu snake venom: the role of platelets. *Brit. J. exp. Path.*, **60**: 201-208, 1979.
15. DEBUS, E.; WEBER, K. & OSBORN, M. - Monoclonal antibodies to desmin, the muscle-specific intermediate filament protein. *EMBO J.*, **2**: 2305-2312, 1983.
16. GIRÓN, M.E.; PINTO, A.; FINOL, H.J.; AGUILAR, I. & RODRIGUEZ-ACOSTA, A. - Kidney structural and ultrastructural pathological changes induced by Uracoan rattlesnake (*Crotalus vegrandis* Klauber 1941) venom. *J. submicrosc. Cytol. Path.*, **34**: 447-459, 2002.

17. GUTIERREZ, J.M.; LEON, G.; ROJAS, G. *et al.* - Neutralization of local tissue damage induced by *Bothrops asper* (terciopelo) snake venom. **Toxicon**, **36**: 1529-1538, 1998.
18. HARLOW, E. & LANE, D. - **Antibodies. A laboratory manual**. New York, Cold Spring Harbor Lab., 1988. p. 471-510.
19. HSU, S.M.; RAINE, L. & FANGER, H. - Use of avidin-biotin-peroxidase complex (ABC) in immunoperoxidase techniques: a comparison between ABC and unlabeled antibody (PAP) procedures. **J. Histochem. Cytochem.**, **29**: 557-580, 1981.
20. JIA, L.G.; SHIMOKAWA, K.; BJARNASON, J.B. & FOX, J.W. - Snake venom metalloproteinases: structure, function and relationship to the ADAMs family of proteins. **Toxicon**, **34**: 1269-1276, 1996.
21. KAISER, I.I. & AIRD, S.D. - A crotoxin homolog from venom of the Uracoan rattlesnake (*Crotalus vegrandis*). **Toxicon**, **25**: 1113-1118, 1987.
22. KAMIGUTI, A.S.; ZUZEL, M. & THEAKSTON, R.D. - Snake venom metalloproteinases and disintegrins: interaction with cells. **Braz. J. med. biol. Res.**, **31**: 853-862, 1998.
23. KONDO, H.; KONDO, S.; IKEZAWA, H.; MURATA, R. & OHSAKA, A. - Studies on the quantitative method for determination of hemorrhagic activity of Habu snake venom. **Jap. J. med. Sci. Biol.**, **13**: 43-49, 1960.
24. LODISH, H.F.; BERRK, A.; ZIPURSKY, S.A. *et al.* - **Molecular cell biology**. 4. ed. New York, W.H. Freeman, 2000.
25. NAKAMURA, T.; MILLER, D.; RUOSLAHTI, E. & BORDER, W.A. - Production of extracellular matrix by glomerular epithelial cells is regulated by transforming growth factor-beta1. **Kidney Int.**, **41**: 1213-1221, 1992.
26. NELSON, W.J. & TRAUB, P. - Proteolysis of vimentin and desmin by the Ca²⁺ activated proteinase specific for these intermediate filament proteins. **Molec. cell. Biol.**, **3**: 1146-1156, 1983.
27. OMORI-SATOH, T.; SADAHIRO, D.; OSAKA, A. & MURATA, R. - Purification and characterization of an anti-hemorrhagic factor in the serum of *Trimeresurus flavoviridis*, a crotalid. **Biochim. Biophys. Acta**, **285**: 414-426, 1972.
28. OSAKA, A.; JUST, M. & HABERMANN, D. - Action of snake venom hemorrhagic principles of isolated glomerular basement membrane. **Biochem. biophys. Acta (Amst.)**, **323**: 415-428, 1973.
29. PULIDO-MENDEZ, M.; RODRIGUEZ-ACOSTA, A.; FINOL, H.J.; AGUILAR, I. & GIRÓN, M.E. - Ultrastructural pathology in skeletal muscle of mice envenomed with *Crotalus vegrandis* venom. **J. submicrosc. Cytol. Path.**, **31**: 555-561, 1999.
30. REED, L.J. & MUNCHEN, H. - A simple method for estimating fifty per cent endpoints. **Amer. J. Hyg.**, **27**: 493-497, 1938.
31. RODRÍGUEZ-ACOSTA, A.; MONDOLFI, A.; ORIHUELA, R. & AGUILAR, A. - ¿Qué hacer frente a un accidente ofídico? Caracas, Venediciones C.A., 1995.
32. RODRIGUEZ-ACOSTA, A.; AGUILAR, I. & GIRÓN, M.E. - Biochemical and hematological effects of Uracoan rattlesnake (*Crotalus vegrandis*) venom on hamsters (*Cricetus auratus*). **J. Nat. Tox.** **5**: 401-407, 1996.
33. RODRIGUEZ-ACOSTA, A.; AGUILAR, I.; GIRÓN, M.E. & RODRIGUEZ-PULIDO, V. - Notes about Uracoan rattlesnake (*Crotalus vegrandis* Klauber, 1941) venom activities. **Arch. venez. Med. trop.**, **2**: 33-36, 1998.
34. RODRIGUEZ-ACOSTA, A.; AGUILAR, I.; GIRÓN, M.E. & RODRIGUEZ-PULIDO, V. - Hemorrhagic activity of neotropical rattlesnake (*Crotalus vegrandis* Klauber, 1941) venom. **Natural Toxins.**, **6**: 1-4, 1998.
35. RODRIGUEZ-ACOSTA, A.; PULIDO-MENDEZ, M., FINOL, H., GIRÓN, M.E. & AGUILAR, I. - Liver ultrastructural pathology in mice envenomed with Uracoan (*Crotalus vegrandis*) venom. **J. submicrosc. Cytol. Path.**, **31**: 433-439, 1999.
36. SAKURAI, N.; SUGIMOTO, K.; SUGIHARA, H. *et al.* - Glomerular injury in mice induced by *Agkistrodon* venom. **Amer. J. Path.**, **122**: 240-251, 1986.
37. SASAKI, S.; BAO, Q. & HUGHES, R.C. - Galectin-3 modulates rat mesangial cell proliferation and matrix synthesis during experimental glomerulonephritis induced by anti-Thy1.1 antibodies. **J. Path.**, **187**: 481-489, 1999.
38. ZUZEL, M. - Toxicological and biological importance of snake venom metalloproteinase and disintegrins. **Toxicon**, **37**: 261, 1999.

Received: 16 October 2002

Accepted: 23 September 2003