

CASE REPORT

Cladophialophora carrionii: A RARE AGENT OF CHROMOBLASTOMYCOSIS IN RIO DE JANEIRO STATE, BRAZIL

Marcelle de F. MOUCHALOUAT, Maria Clara G. GALHARDO, Paulo Cezar Monteiro FIALHO, Janice Mery C. de Oliveira COELHO, Rosely Maria ZANCOPE-OLIVEIRA & Antonio Carlos F. do VALLE

SUMMARY

A 73 year-old male farm laborer from a rural area presented a 15 year history of extensive tumoral lesions over his left leg. Histological studies of skin biopsy showed pseudoepitheliomatous hyperplasia and granulomatous chronic inflammatory process with muriform cells, confirming chromoblastomycosis (CBM). *Cladophialophora carrionii* was isolated in culture. Treatment with itraconazole 400 mg/day for 12 months resulted in complete remission of lesions. As far we aware, this is the first case report of CBM caused by *Cladophialophora carrionii* in Rio de Janeiro State, Brazil.

KEYWORDS: Chromoblastomycosis; *Cladophialophora carrionii*; Subcutaneous mycoses; Brazil.

INTRODUCTION

Chromoblastomycosis (CBM) is a chronic disease of cutaneous and subcutaneous tissues caused by filamentous fungi of the *dematiaceae* family (with melanic-type pigment in the wall).

Most cases have been described in tropical and subtropical regions, especially in Madagascar, Brazil, Japan, Venezuela and México²⁵. Most infections are caused by *Fonsecaea pedrosoi*. *C. carrionii* is the second most common agent, presenting in dry areas with a dry climate, such as spiny desert in southern deciduous thicket ecosystem in Madagascar and Venezuela^{12,17,25}.

Pará State is the major focus of CBM in Brazil, with *F. pedrosoi*, which is the most common agent followed by *Phialophora verrucosa*. According to Medline, Lilacs and Scielo databases, *C. carrionii* has not been described as agent of this mycosis. We report the first case of CBM caused by *C. carrionii* in Rio de Janeiro State, Brazil.

CASE REPORT

A 73-year-old male, farm laborer, living in Itaboraí, a rural city 45 km far from city of Rio de Janeiro, presenting painful lesions over his left leg for 15 years was referred to the outpatient clinic of infectious dermatology (IPEC - Fiocruz). The patient denied other problems, such as diabetes and hypertensive disease but was in poor health and nutritional conditions. He has never been outside Rio de Janeiro State.

Lesions were erythematous to violaceous papules, painful, in different sizes, forming tumoral lesions with irregular bleeding on the surface, the largest one measuring 8 x 6 cm (Fig. 1). Myiasis and edema of the affected leg were present. Local lymph nodes were not involved. X-ray indicated no bone involvement.

Hematoxylin and eosin stained sections of biopsy material showed pseudoepitheliomatous hyperplasia and granulomatous chronic inflammatory process with multinucleate giant cells, epithelioid cells, histiocytes, lymphocytes and neutrophils inside microabscesses. There were muriform cells within and outside the multinucleate giant cells. Additionally special stains PAS and *Grocott* were performed.

KOH preparation was negative. Culture on Sabouraud 2% glucose agar yielded velvety olive-black colony within four weeks. Microscopic slide examination of culture material on potato glucose agar revealed acropetal conidia pale olivaceous, limoniform, arising in long branched chains, smooth-walled or slightly verrucose suggestive of *C. carrionii* (Fig. 2). Additionally the agent was identified by molecular sequence data of the ITS1-ITS2 regions of the rDNA. The sequence matched *C. carrionii* in GenBank (www.ncbi.nlm.nih.gov/genbank).

The patient was initially treated with ivermectin and cephalexin for secondary infection. Itraconazole 200 mg twice a day was administered for 12 months with good response.

No adverse effects were noted. Atrophic scars formed in healed

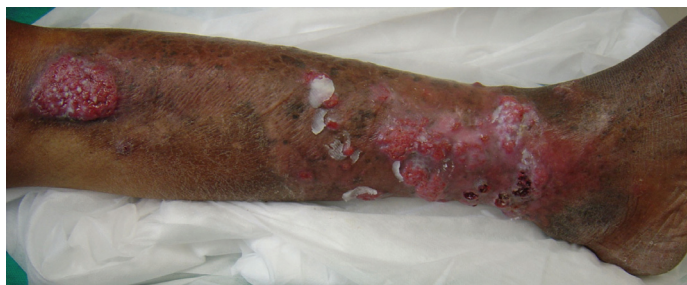

Fig 1 - Extensive tumoral lesions.

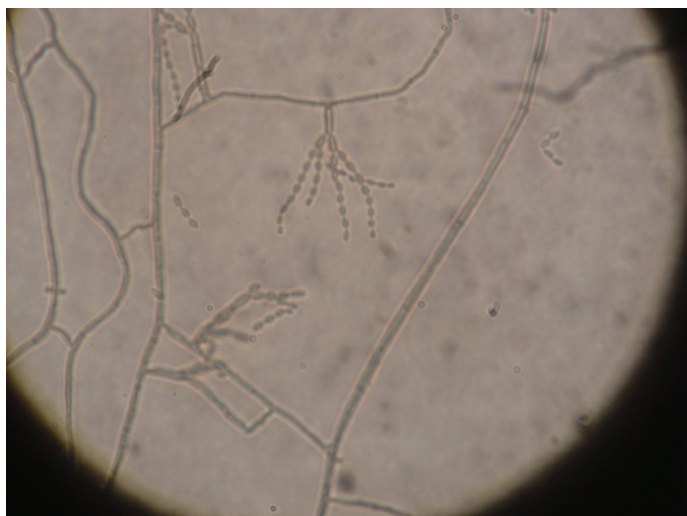


Fig. 2 - *C. carrionii*: long, flexuous, branching chains of conidia that are regular in size (slide culture).

areas. Mycological examination was negative and histopathology showed inflammatory process with lymphocytes and cicatricial fibrosis. Relapse was not reported in two years of follow-up after cure.

DISCUSSION

In Brazil, there is scant information concerning the incidence of CBM, as it is not a reportable condition. This mycosis has been reported in states of Pará²³, Rio Grande do Sul¹¹, Paraná¹⁸, Maranhão²², Rio de Janeiro¹⁵, Pernambuco¹⁰, Mato Grosso²¹, Rondônia¹, Ceará¹⁴. These studies show that in CBM predominate sex male, farm laborer, presenting verrucous form located in lower limb with long course of disease (more than ten years). As a whole, *F. pedrosoi* and *P. verrucosa* are the most common agents²³. Other identified CBM agents are *F. compacta*, *Exophiala jeanselmei*, *E. castellanii*, and *Rhinochadiella aquaspersa*^{11,13,18,24}.

C. carrionii is ubiquitous in the semi-arid area, where xerophytes are found, predominantly *Cactaceae*, possibly a natural reservoir of the fungus⁷. The name *Cladophialophora* is used instead of *Cladosporium* because of its ability to produce phialides⁶. Surprisingly, the patient was living in Itaboraí, a place of tropical climate, temperature range 12 - 33 °C (average 18 °C) and annual rainfall 1,000-1,500 mm/year, differing considerably from areas where *C. carrionii* is found and never went to another place. There are only two cases of CBM caused by *C. carrionii* in Brazil, in states of Pernambuco and Pará^{10,16}. In Pernambuco State,

from nine cases of CBM, only one patient had a disease caused by *C. carrionii*, presenting desquamative plaques in lower limbs with ten years of evolution. In Pará, a case of CBM was reported, caused by this agent and lobomycosis with the same lesions as the farm laborer who presented verrucous and nodular forms in lower limb with 18 years of course of disease.

The present patient was an agricultural worker as it is typically found for CBM²³. Median incubation period for CBM is not known; however, most cases progress slowly, e.g. 15 years like this case, over many years and sometimes decades.

The patient presented tumoral lesions, but the clinical aspect of the lesions is diverse; verrucous is the most frequently reported lesion, and most lesions are present on the lower limbs^{11,12,23}.

In this study, rRNA gene ITS region was amplified and sequenced. Identification based on molecular sequence with high sensitivity provide an additional way to characterize and identify molecularly the etiologic agents of CBM⁵.

In CBM, the clinical aspect is not related to the agent. However different therapeutic reactions can be obtained according to the agent. Itraconazole, is the drug of choice for CBM and seems to be the best therapy for *C. carrionii*, that presents better response to antifungal agents than *F. pedrosoi*^{2,20}. Our patient showed good response, with cure in 12 months of treatment, in spite of the severe form of the disease¹⁹. Treatment should be continued until clinical resolution; which usually occurs after several months of therapy³. Relapse is common, however, especially in the most extensive lesions¹². Terbinafine, cryotherapy and surgery are other options of treatment^{4,9,26}. Recently, terbinafine and itraconazole were used with good results⁹.

RESUMO

Cladophialophora carrionii: agente raro de cromoblastomicose no estado do Rio de Janeiro, Brasil.

Lavrador, com 73 anos, residente em área rural apresentava há 15 anos lesões tumorais disseminadas na perna esquerda. Exame histopatológico de biópsia de pele mostrou hiperplasia pseudo-epiteliomatosa e processo inflamatório crônico granulomatoso com células muriformes, confirmando o diagnóstico de cromoblastomicose (CBM). *Cladophialophora carrionii* foi isolado na cultura. Tratamento com itraconazol 400 mg/dia durante 12 meses resultou na completa remissão das lesões. Este é o primeiro relato de CBM causado por *C. carrionii* no estado do Rio de Janeiro, Brasil.

ACKNOWLEDGEMENTS

We acknowledge Patrícia Morais Silva Tavares for her collaboration in molecular identification of species.

REFERENCES

1. ALVES, M.A. & CAMARGO, L.M.A. - Caracterização clínica e epidemiológica dos pacientes portadores de cromoblastomicose na Região de Monte Negro - Rondônia. In: CONGRESSO DA SOCIEDADE BRASILEIRA DE MEDICINA TROPICAL, 43., Campos do Jordão, 2007. *Resumos*, p. 101. *Rev. Soc. bras. Med. trop.*, 40 (supl. 1): 101, 2007.

2. BONIFAZ, A.; MARTINEZ-SOTO, E.; CARRASCO-GERARD, E. & PENICHE J. - Treatment of chromoblastomycosis with itraconazole, cryosurgery, and a combination of both. **Int. J. Derm.**, 36: 542-557, 1997.
3. BONIFAZ, A.; CARRASCO-GERARD, E. & SAUL, A. - Chromoblastomycosis: clinical and mycologic experience of 51 cases. **Mycoses**, 44(1-2): 1-7, 2001.
4. CASTRO, L.G.M.; PIMENTEL, E.R.A. & LACAZ, C.S. - Treatment of chromomycosis by cryosurgery with liquid nitrogen: 15 years' experience. **Int. J. Derm.**, 42: 408-412, 2003.
5. DE ANDRADE, T.S.; CURY, A.E.; CASTRO, L.G.; HIRATA, M.H. & HIRATA, R.D. - Rapid identification of *Fonsecaea* by duplex polymerase chain reaction in isolates from patients with chromoblastomycosis. **Diagn. Microbiol. infect. Dis.**, 57: 267-272, 2007.
6. DE HOOG, G.S.; GUÉHO E.; MASCLAUX, F. *et al.* - Nutritional physiology and taxonomy of human-pathogenic Cladosporium - Xylohypha species. **J. med. vet. Mycol.**, 33: 339-347, 1995.
7. DE HOOG, G.S.; QUEIROZ-TELLES, F.; HAASE, G. *et al.* - Black fungi: clinical and pathogenic approaches. **Med. Mycol.**, 38(suppl. 1): 243-250, 2000.
8. ESTERRE, P.; ANDRIANTSIMAHAVANDY, A.; RAMARCEL, E.R. & PECARRERE, J.L. - Forty years of chromoblastomycosis in Madagascar: a review. **Amer. J. trop. Med. Hyg.**, 55: 45-47, 1996.
9. GUPTA, A.K.; TABORDA, P.R. & SANZOVO, A.D. - Alternate week and combination itraconazole and terbinafine therapy for chromoblastomycosis caused by *Fonsecaea pedrosoi* in Brazil. **Med. Mycol.**, 40: 529-534, 2002.
10. LACERDA, A.M. - Cromoblastomicose em Pernambuco. In: SIMPÓSIO NACIONAL DE MICOLOGIA MÉDICA: CROMOBLASTOMICOSE, LOBOMICOSE, PARACOCCIDIOIDOMICOSE, CRIPTOCOCOSE, Belém, 2005. p. 31-33.
11. LONDERO, A.T. & RAMOS, C.D. - Cromoblastomicose no interior do Estado do Rio Grande do Sul. **An. bras. Derm.**, 64: 155-158, 1989.
12. LOPEZ-MARTINEZ, R. & MENDEZ-TOVAR, L.J. - Chromoblastomycosis. **Clin. Derm.**, 25: 188-194, 2007.
13. MARQUES, S.G.; PEDROZO SILVA, C.M.; RESENDE, M.A.; ANDREATA, L.S. & COSTA, J.M.L.G. - Chromoblastomycosis caused by *Rhinocladiella aquaspersa*. **Med. Mycol.**, 42: 261-265, 2004.
14. MAPURUNGA, A.C.P.; GONÇALVES, H.M.G.; SILVA, J.B.; CABRAL, S.E.S.X. & DIÓGENES, M.J.N. - Micose profundas no Ceará: estudo dos casos diagnosticados no Hospital das Clínicas da Universidade Federal do Ceará (1983 a 1988). **An. bras. Derm.**, 65: 117-118, 1990.
15. MAPURUNGA, A.C.P.; TEIXEIRA, F.L.L.; BARGIONA, S.P. *et al.* - Micose profundas diagnosticadas no Hospital Universitário Gaffrée e Guinle (HUGG) no período de 1978 a 1989. **An. bras. Derm.**, 66: 243-250, 1991.
16. MESQUITA DA COSTA, M.; MARQUES DA SILVA, S.H.; ALMEIDA, H.J.R.; QUARESMA, J.S.A. & RAMOS, F.L.P. - Associação de cromoblastomicose e doença de jorge lobo em mesmo paciente: relato de caso. In: SIMPÓSIO NACIONAL DE MICOLOGIA MÉDICA: CROMOBLASTOMICOSE, LOBOMICOSE, PARACOCCIDIOIDOMICOSE, CRIPTOCOCOSE; Belém, 2005. p. 88.
17. PEREZ-BLANCO, M.; HERNANDEZ-VALLES, R.; GARCIA-LUMBRIA, L. & YEGRES, F. - Chromoblastomycosis in children and adolescents in the endemic area of the Falcon State, Venezuela. **Med. Mycol.**, 44: 467-471, 2006.
18. QUEIROZ-TELLES FILHO, F. - Chromoblastomycosis in the State of Paraná: etiology, epidemiology, clinic and treatment with itraconazole. **Rev. Soc. bras. Med. trop.**, 30: 345-346, 1997.
19. QUEIROZ-TELLES, F.; McGINNIS, M.R.; SALKIN, I. & GRAYBILL, J.R. - Subcutaneous mycoses. **Infect. Dis. Clin. N. Amer.**, 17: 59-85, 2003.
20. RESTREPO, A. - Treatment of tropical mycoses. **J. Amer. Acad. Derm.**, 31(3 Pt. 2): S91-S102, 1994.
21. REZENDE, S.B.; TADANO, M.; HAHN, R.C. & FONTES, C.J. - Cromomicose em Mato Grosso: descrição clínico-epidemiológica de série de casos. In: CONGRESSO DA SOCIEDADE BRASILEIRA DE MEDICINA TROPICAL, 43., Campos do Jordão, 2007. **Resumos**. p. 94. **Rev. Soc. bras. Med. trop.**, 40(supl. 1): 94, 2007.
22. SILVA, C.M.P.; SANTOS D.W.C.L.; COSTA J.M.L. *et al.* - Cromoblastomicose no Estado do Maranhão: estudo epidemiológico de 94 casos autóctones. **Rev. Soc. bras. Med. trop.**, 37(supl. 1): 57-58, 2004.
23. SILVA, J.P.; SOUZA, W. & ROZENTAL, S. - Chromoblastomycosis: a retrospective study of 325 cases on Amazonic Region (Brazil). **Mycopathologia**, 143: 171-175, 1999.
24. SILVA, A.C.C.M.; NETO, S.A.; GALVÃO, C.E.S. *et al.* - Cromoblastomicose produzida por *Fonsecaea pedrosoi* no estado do Maranhão. I. Aspectos clínicos, epidemiológicos e evolutivos. **Rev. Soc. bras. Med. trop.**, 25: 37-44, 1992.
25. TYRING, S.; LUPI, O. & HENGGE, U. - Chromoblastomycosis. In: CARDOSO DE BRITO, A. **Tropical dermatology**. São Paulo, Elsevier, 2005. p. 203
26. VIJAYA, D. & KUMAR, B.H. - Chromoblastomycosis. **Mycoses**, 48: 82-84, 2005.

Received: 11 February 2008
Accepted: 29 September 2008