

BRIEF COMMUNICATION

AN OUTBREAK OF SCALP WHITE PIEDRA IN A BRAZILIAN CHILDREN DAY CARE

Ana Maria ROSELINO(1), Ana Beatriz SEIXAS(1), José A. THOMAZINI(2) & Claudia M.L. MAFFEI(3)

SUMMARY

White piedra is a superficial mycosis caused by *Trichosporon* spp. that affects the hair shaft of any part of the body. It is presented an outbreak of scalp white piedra seen in 5.8% of the children frequenting a day care in Northeastern of São Paulo State, Brazil. Mycological exam and culture identified *T. cutaneum* in all five cases, and scanning electron microscopy of nodules around hair shaft infected by *Trichosporon* spp. is demonstrated comparing them with those of black piedra and with nits of *Pediculous capitis*.

KEYWORDS: White piedra; Epidemiology; Outbreak; *Trichosporon* spp.; *T. cutaneum*; *T. beigelli*.

INTRODUCTION

White piedra is a superficial mycosis characterized by nodules of *Trichosporon* spp. that encircle the hair shaft of any part of the body. It occurs mainly in South America. More recently, molecular studies have shown that the taxon *Trichosporon beigelli* was replaced by the following six human pathogens: *T. cutaneum*, *T. asahii*, *T. asteroides*, *T. mucoides*, *T. inkin* and *T. ovoides*^{3,6}. The main reports in the literature show compromising of the hair on genital region^{2,5,10,16,18}. Isolated cases and laboratorial results from mycological exams have been related^{1,13}. There are some recent reports of scalp white piedra seen in children in Brazil^{4,8,9,15}, Mexico¹⁷ and in North America¹¹. This is the first report of an outbreak of scalp white piedra in children from Ribeirão Preto city, Northeastern of São Paulo State, Brazil.

PATIENTS AND METHODS

The first case of scalp white piedra was a 5 year-old female child, assisted at the University Hospital of Faculty of Medicine of Ribeirão Preto (São Paulo State, Brazil), in February of 1997, who had been frequenting a public children day care. In the end of 1997, the children of that day care and 10 workers were examined. Hair samples of suspicious cases of white piedra were collected for mycological exam, culture in Sabouraud's agar, and scanning electron microscopy. For the fungi identification, biochemical methods were accomplished.

RESULTS

Eighty-six children were examined (83.5%) from the total of 103, with age between one and five years, 44 female, with prevalence of the white

race (69.8%). Included the first case, scalp white piedra was diagnosed in five children among those examined (5.8%), all female, with long curly brown hair, good hygiene and without any other lesions in their scalp (Table 1). On scanning electron microscopy, multiple nodules composed by arthrospores were surrounding the hair shaft, without compromising the cortex or the marrow hair (Fig. 1). In the culture colonies presented as paraffin-like aspect, which microscopy exam evidenced arthroconidia as well as blastoconidia (Fig. 2). The identification of *T. cutaneum* was confirmed by biochemical methods.

Several other pediatric dermatoses were diagnosed, such as pediculosis in 18.6% and chickenpox in 15.1%. Among the examined professionals white piedra was not diagnosed.

Table 1
Children's data with scalp white piedra who frequented a Brazilian children day care

Initials	Age	Sex	Color	Period in the children day care
K*	5y	F	W	1994 to February 1997
K	4y 3mo	F	W	Since October 1994
M‡	4y 5mo	F	M	Since February 1997
J	2y 8mo	F	M	Since February 1997
E+	4y 1mo	F	W	Since August 1997

*: first case diagnosed, her brother frequented the day care and did not present white piedra; ‡natural from Ilhéus (Bahia State, Brazil); +diagnosis of pediculosis too; F: female; W: white; M: mulatto

(1) Division of Dermatology, Department of Internal Medicine. Faculdade de Medicina de Ribeirão Preto/USP, Ribeirão Preto, SP, Brazil.

(2) Department of Surgery and Anatomy. Faculdade de Medicina de Ribeirão Preto/USP, Ribeirão Preto, SP, Brazil.

(3) Department of Cellular and Molecular Biology and Pathogenic Bio-Agents, University of São Paulo, Faculty of Medicine of Ribeirão Preto, São Paulo State, Brazil.

Correspondence to: Ana Maria F. Roselino, Departamento de Clínica Médica, Faculdade de Medicina de Ribeirão Preto/USP, Av. Bandeirantes 3900, 14049-900 Ribeirão Preto, SP, Brasil.
Fax: 55-16-3633.6695. E-mail: amfrosel@fmrp.usp.br.

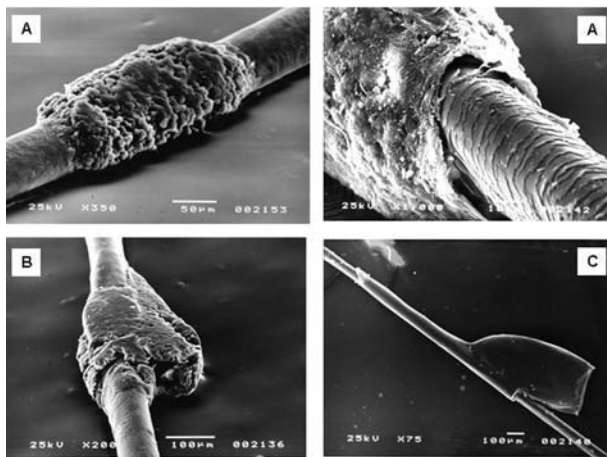


Fig. 1 - A:- Multiple nodules composed by arthrospores, hyphae and cementant substance of *Trichosporon* spp. encircling a hair shaft, without compromising the cortex or the marrow hair (scanning electron microscopy, x350; in detail x1,000). For comparison, **1B:** nodules of *Piedra hortai* (black piedra) (scanning electron microscopy, x200, and **1C:** nits of *Pediculus capitis* do not completely encircle the hair shaft (scanning electron microscopy, x75).

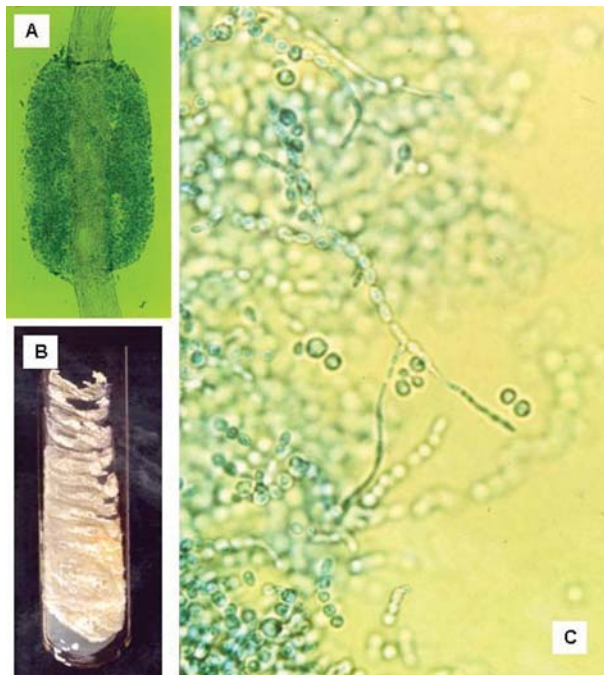


Fig. 2 - A: Direct microscopic exam of a *Trichosporon* spp. nodule surrounding a hair shaft (x100). **B:** Culture characteristics: colonies presented as paraffin-like aspect, without pigment on the reverse side. **C:** Microscopic examination shows hyaline, septate hyphae with fragment into oval or rectangular arthroconidia (2 to 4 x 3 to 9 µm).

DISCUSSION

Trichosporon spp. (old denomination *T. beigeli*) is commonly found in nature (soil, water and vegetal matter) and it has been isolated from monkeys, horses and dogs^{3,6}. The diagnosis of *Trichosporon* infection has become more important in the last few years, as it has been described as eczematous form mimicking dermatophytosis, as generalized papules and

nodules in immunocompromised patients representing a trichosporonosis form, or as systemic infection in patient submitted to peritoneal dialysis or parenteral nutrition^{12,14}.

White piedra can be clinically indistinguishable from pediculosis or trichobacteriosis, and association of white piedra with bacteria and nits has been observed^{7,15,16,19}. In our casuistic, in one case there was association with pediculosis but we didn't observe association with bacteria by culture or scanning electron microscopy.

Most of the reports of scalp white piedra has demonstrated that it occurred predominantly among female children (2-6 years old at preschool age)^{4,8,11,15,17}, according with our finding.

The first child diagnosed in this study had frequented the day care from 1994 to February 1997. As this fungal dermatosis is not common in Ribeirão Preto, Northeastern of São Paulo State, it was considered the possibility of one of the children, who was coming from Ilhéus (Bahia State, Brazil) being the contaminating source. However, this child had arrived in the city recently, and she started frequenting the day care after February 1997. Moreover, the parents of this child were examined and did not have their scalp or genital hair compromised.

The mode of transmission in human is not so far clear being more associated with high temperature and humidity^{11,15,16}, and we didn't observe any relation with socioeconomic level like other reports^{4,8,9,11,15,17}. Despite the fact that it was not possible to determine the focal source of contamination, the first cases of white piedra configuring an interpersonal contagion in an outbreak seen in the northeastern region of São Paulo State were registered.

RESUMO

Surto de pedra branca afetando os cabelos do couro cabeludo de crianças em creche brasileira

Piedra branca caracteriza-se por ser micose superficial, causada por *Trichosporon* spp., que compromete a haste dos pelos de qualquer região do corpo. Um surto de pedra branca, afetando os cabelos do couro cabeludo, foi registrado em 5,8% das crianças que freqüentavam uma creche na região nordeste do estado de São Paulo. Exame micológico direto e cultura identificaram *T. cutaneum* nas cinco crianças afetadas. Enfatiza-se a utilização da microscopia eletrônica de varredura, que mostrou nódulos circundando a haste dos cabelos infectada por *Trichosporon* spp., comparando-os com nódulos de *Piedra nigra* e com lêndeas de *Pediculus capitis*.

REFERENCES

- ALMEIDA Jr., H.L.; RIVITTI, E.A. & JAEGER, R.G. - White piedra: ultrastructure and the new micro-ecological aspect. *Mycoses*, 33: 491-497, 1990.
- CARNEIRO, J.A.; ASSIS, F.A.; TRINDADE FILHO, J. & CARVALHO, C.A.Q. - Piedra branca genital: 40 casos. *An. bras. Derm.*, 46: 265-269, 1971.
- CHAGAS-NETO, T.C.; CHAVES, G.M. & COLOMBO A.L. - Update on the Genus *Trichosporon*. *Mycopathologia*, 166: 121-132, 2008.
- DINIZ, L.M. & SOUZA FILHO, J.B. - Estudo de 15 casos de pedra branca observados na grande Vitória (Espírito Santo-Brasil) durante cinco anos. *An. bras. Derm.*, 80: 49-52, 2005.

5. FISCHMAN, O.; CAMARGO, Z.P. & MEIRELLES, M.C.A. - Genital white piedra: an emerging fungal disease? In: INTERNATIONAL CONFERENCE ON MYCOSES 5., PAHO, 1989. p. 70-76. (PAHO Scientific Publication 396).
6. GHÉHO, E.; SMITH, M.T.; DE HOOG, G.S. *et al.* - Contributions to a revision of the genus *Trichosporon*. **Antonie Van Leeuwenhoek**, 61: 289-316, 1992.
7. GHORPADE, A. - Surrogate nits impregnated with white piedra: a case report. **J. Europ. Acad. Derm. Vener.**, 18: 474-476, 2004.
8. GONÇALVES, H.G.; MARUPUNGA, A.C.P.; MONTEIRO, C.M.; LOWY, G. & LIMA, A.A.B. - Piedra branca: revisão de literatura a respeito de três casos. **Rev. bras. Med.**, 48: 541-542, 1991.
9. JUANG, J.M.; MARQUES, E.R.M.C.; COUTO, L.W.M.; METELMANN, U. & SILVA, E.H. - Piedra branca no couro cabeludo. **An. bras. Derm.**, 75(supl. 2): 25, 2000.
10. KALTER, D.C.; TSCHEN, J.A.; CERNOCH, P.L. *et al.* - Genital white piedra: epidemiology, microbiology and therapy. **J. Amer. Acad. Derm.**, 14: 982-993, 1986.
11. KIKEN, D.A.; SEKARAN, A.; ANTAYA, R.J. *et al.* - White piedra in children. **J. Amer. Acad. Derm.**, 55: 956-961, 2006.
12. LASCAUX, A.S.; BOUSCARAT, F.; DESCAMPS, V. *et al.* - Manifestations cutanées au cours d'une trichosporonose disséminée chez un malade sidéen. **Ann. Derm. Vénér.**, 125: 111-113, 1998.
13. LASSUS, A.; KANERVA, L.; STUBB, S. & SALONEN, A. - White piedra: report of a case evaluated by scanning electron microscopy. **Arch. Derm.**, 118: 208-211, 1982.
14. LOPES, J.O.; ALVES, S.H.; BENEVENGA, J.P.; ROSA, A.C. & GÓMEZ, V.C. - *Trichosporon beigeli* peritonitis associated with continuous ambulatory peritoneal dialysis. **Rev. Inst. Med. trop. S. Paulo**, 36: 121-123, 1994.
15. PONTES, Z.B.V.S.; RAMOS, A.L.; LIMA, E.O. *et al.* - Clinical and mycological study of scalp white piedra in the State of Paraíba, Brazil. **Mem. Inst. Oswaldo Cruz**, 97: 747-750, 2002.
16. THÉRIZOL-FERLY, M.; KOMBILA, M.; GOMEZ DE DIAZ, M. *et al.* - White piedra and *Trichosporon* species in equatorial Africa. II. Clinical and mycological associations: an analysis of 449 superficial inguinal specimens. **Mycoses**, 37: 255-260, 1994.
17. VASQUEZ-TSJI, O.; GARCIA, C.G.; CAMPOS, T.R. *et al.* - Piedra blanca de localización inusual en un paciente pediátrico. **Rev. méx. Pat. clin.**, 47: 146-149, 2000.
18. WALZMAN, M. & LEEMING, J.G. - White piedra and *Trichosporon beigeli*: the incidence in patients attending a clinic in genitourinary medicine. **Genit. Med.**, 65: 331-334, 1989.
19. YOUKER, S.R.; ANDREOZZI, R.J.; APPELBAUM, P.C.; CREDITO, K. & MILLER, J.J. - White piedra: further evidence of a synergistic infection. **J. Amer. Acad. Derm.**, 49: 746-749, 2003.

Received: 27 November 2007

Accepted: 11 September 2008