

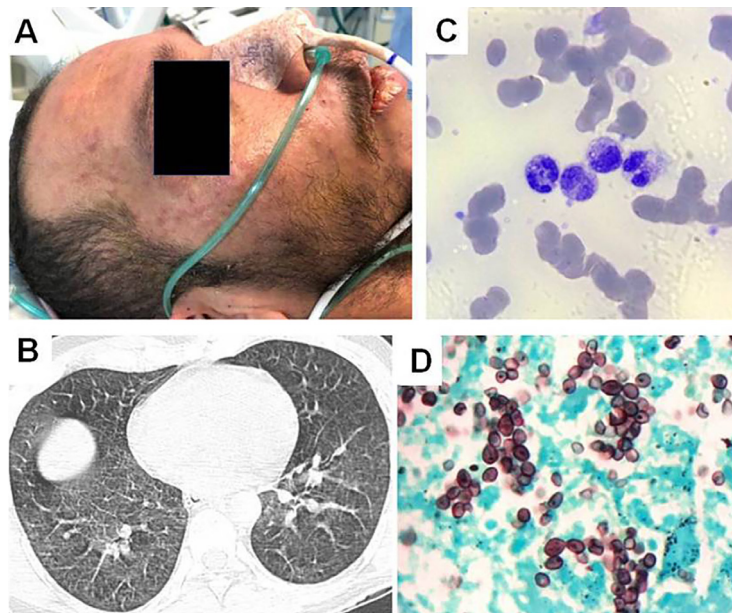
Septic shock, hyperferritinemic syndrome, and multiple organ dysfunction without respiratory failure in a patient with disseminated histoplasmosis and advanced HIV disease

Rev Inst Med Trop Sao Paulo. 2023;65:e28

<http://doi.org/10.1590/S1678-9946202365028>

On page 2, Figure 1:

Where it reads:



Should be read:

