

RETRACTION:

- Pereira CM, Monteiro MC, Meneghini AJ, Silva GBL, Lelis JL, Botelho TL.
Burkitt's lymphoma: clinic progression and prognosis. Two different cases reports in young patients.
Rev. odonto ciênc. 2010; 25(4):417-421.
DOI: 10.1590/S1980-65232010000400018.
<http://revistaseletronicas.pucrs.br/ojs/index.php/fo/article/view/6377/5993>

Major content (verbatim text and figures) of this article was firstly published in:

- Pereira CM, Lopes AP, Meneghini AJ, Silva GB, Monteiro MC, Botelho T de L.
Burkitt's lymphoma in a young Brazilian boy.
Malays J Pathol. 2010 Jun; 32(1):59-64.
http://www.mjpath.org.my/2010.1/Burkitts_lymphoma.pdf

This article is therefore considered a duplicate publication demanding editorial action according to the code of conduct and guidelines of the Committee on Publication Ethics (COPE):

<http://publicationethics.org/>

After contacting the authors and careful consideration, in agreement with the editor-in-chief of the Malaysian Journal of Pathology, this article has been retracted in whole by Revista Odonto Ciência (Journal of Dental Science).

Burkitt's lymphoma: clinic progression and prognosis. Two different cases reports in young patients

Linfoma de Burkitt: evolução clínica e prognóstico. Relato de dois casos diferentes em pacientes jovens

Abstract

Purpose: Burkitt's lymphoma is one of the fastest growing malignancies in the pediatric population. It is a high-grade B-cell non-Hodgkin's lymphoma with endemic, sporadic and human immunodeficiency-associated subtypes. The African, or endemic, variant usually involves the maxilla and other facial bones, while head and neck manifestations in sporadic Burkitt's lymphoma are rare.

Case description: Two cases of oral manifestations of Burkitt's lymphoma are described on the right jaw in young patients, which had different clinical evolution and prognosis.

Key words: Burkitt's lymphoma; B-cell Non-Hodgkin's lymphoma; cancer

Resumo

Objetivo: O linfoma de Burkitt é uma das mais importantes neoplasias de crescimento rápido na população pediátrica. É um linfoma Não-Hodgkin primário de células B subdividido em endêmico, esporádico ou associada a imunodeficiência humana. O tipo africano (endêmico), quando em cabeça e pescoço, envolve geralmente os maxilares e outros ossos faciais, enquanto que o envolvimento facial da forma esporádica é bem raro.

Descrição do caso: São descritos dois casos clínicos de linfomas de Burkitt envolvendo maxila direita em pacientes jovens, os quais apresentaram evolução clínica e prognósticos diferentes.

Palavras-chave: Linfoma de Burkitt; linfoma não-Hodgkin de células B; câncer

Cláudio M. Maranhão Pereira^a
Mariana C. Monteiro^b
Alexandre J. Meneghini^c
Geisa B. L. Silva^c
José Luis Leles^d
Teresa de L. Botelho^d

^a Discipline of Oral Pathology, School of Dentistry, Paulista University, Goiânia, GO and Brasília, DF, Brazil

^b Private practice, Goiânia, GO, Brazil

^c Staff of Clinical Oncology, Araújo Jorge Hospital, Goiânia, GO, Brazil

^d Departments of Oral Pathology and Oral Surgery, School of Dentistry, Paulista University, Goiânia, GO, Brazil

Correspondence:

Cláudio Maranhão Pereira
Faculdade de Odontologia da
Universidade Paulista, campus Brasília
Coordenação de Odontologia
Patologia Oral - Diagnóstico Oral
SGAS Quadra 913, s/nº - Conjunto B - Asa Sul
Brasília, DF - Brasil
70390-130
E-mail: claudiomaranhao@hotmail.com;
odontologiabrasilia@unip.br

Received: January 4, 2010
Accepted: September 20, 2010

Conflict of Interest Statement: The authors state that there are no financial and personal conflicts of interest that could have inappropriately influenced their work.

Copyright: © 2010 Pereira et al.; licensee EDIPUCRS. This is an Open Access article distributed under the terms of the Creative Commons Attribution-Noncommercial-No Derivative Works 3.0 Unported License.

Introduction

Burkitt's lymphoma was first characterized by Denis Burkitt in 1958 while he was a surgeon for the Colonial Medical Service in Uganda. It is an aggressive form of non-Hodgkin's B-cell lymphoma, usually diagnosed in children and young adults, but also seen rarely in middle-aged adults (1-3). It is now accepted that there are three subtypes: the endemic (African) type, with incidence between 5 and 7 years old and involvement of the jaw in more than 50% of the cases; the sporadic (American) type, which has a mean peak age of 11 years old and usually has abdominal mass as clinical presentation; and the type associated with acquired immunodeficiency status (4).

The clinical presentation of Burkitt's lymphoma is characterized by rapid progression of symptoms with frequent multifocal extranodal involvement. Within the oral cavity, this tumor can progress very fast and appears as a facial swelling or exophytic mass involving the jaws (5).

This paper describes two cases of oral Burkitt's lymphoma in two young boys, which had different clinical evolution and prognosis.

Description of the Case 1

A male, 4 year old subject from Morrinhos, GO, Brazil, was referred to the Oral Diagnosis Service of Paulista University in April 2007 by the oral surgeon from the Urgency Hospital of Goiania, for evaluation of a jaw injury. The responsible person for the patient reported that the child had reported a sharp tooth pain for a month and had an extraction procedure. After this, a fast-growing enlargement in the right jaw was observed. In the physical examination severe facial asymmetry on the right side was seen, the patient had normal skin color, he was eupneic and no symptoms of systemic alterations were found (Fig. 1a). He did not complain of pain; however, the injury in the jaw caused some difficulties

in his stomatognathic function. In the intraoral examination, a single lesion in the right jaw with vegetative appearance, diffuse limits, irregular edges, measuring 12x11 cm was viewed (Fig. 1b).

Radiographically, the lesion was single, radiolucent and with imprecise limits, causing teeth displacement and resorption of cortical bone (Fig. 2). Under general anesthesia, incisional biopsy of the lesion was performed, and it presented a framework compatible with malignancy neoplasia. The histopathological picture showed small round cells with scarce cytoplasm and multiple small nuclei interspersed by macrophages in the process of phagocytosis, consistent with diagnosis of Burkitt's lymphoma (Fig. 3a). Immunohistochemical examination showed diffusely positive for CD 20 and CD10, weakly positive for CD 3, negative for CD 5 and positive in more than 90% for Ki-67, confirming the diagnosis of Burkitt's lymphoma (Fig. 3b).

The patient was referred to the Oncoepidiatric Department of the Araújo Jorge Hospital, in Goiania. Myelogram was performed and the possibility of marrow involvement by lymphoma was ruled out. The patient started chemotherapy treatment in May 2007. After three cycles of chemotherapy, there was massive reduction in the tumor and general health improvement. The patient had continued in chemotherapy treatment, and the only worth-while clinical complication was the development of herpetic stomatitis during the sixth cycle of chemotherapy, with fever and leucopenia.

Then, therapy with MaxCef® and Acyclovir® had begun and significant improvement was achieved following five days of treatment. The patient completed the sixth cycle of chemotherapy and progressed well, no fever or major complications, ending the treatment in August 2007. The patient has presented remission of the disease for 11 months and he has been in regular control sessions in the Oncoepidiatric Department of Araújo Jorge Hospital (Fig. 4a, 4b and 4c).

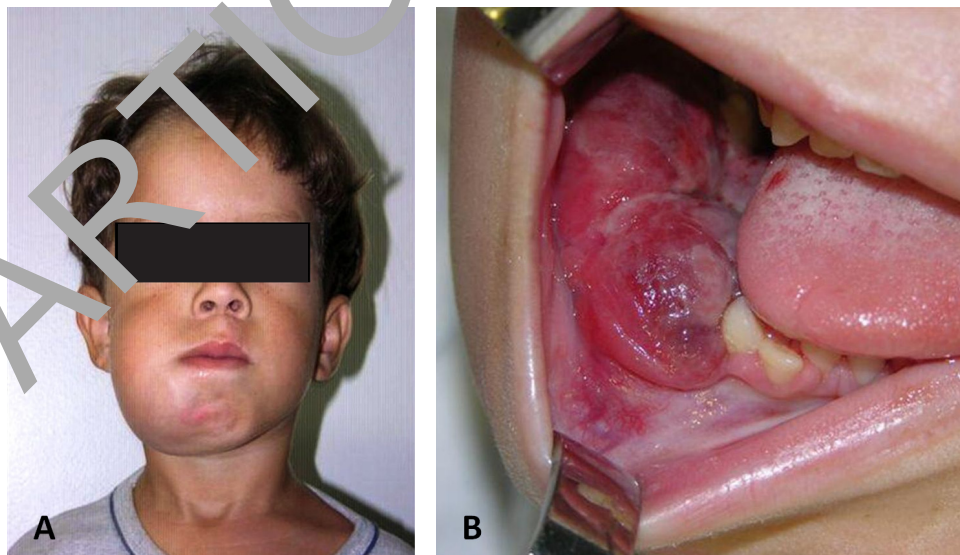


Fig. 1. (A) Severe facial asymmetry on the right side. **(B)** Oral lesion in right jaw with vegetative appearance, diffuse limits, irregular edges, measuring 12x11 cm.

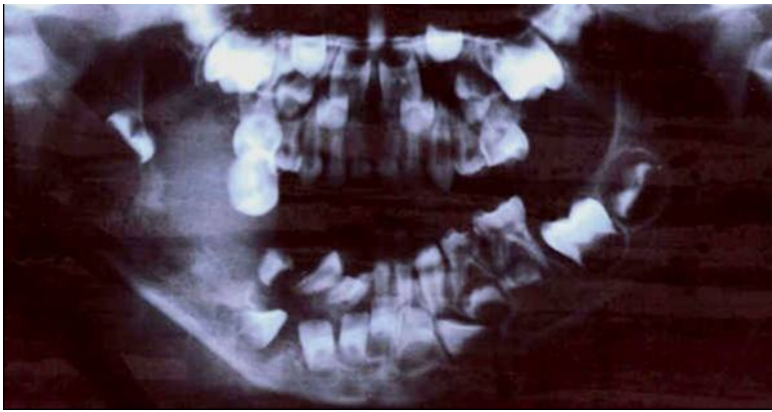


Fig. 2. Radiographically, the lesion was single, radiolucent and with imprecise limits, causing teeth displacement and resorption of cortical bone.

Fig. 3. (A) The histopathological picture showed small round cells with scarce cytoplasm and multiple small nuclei interspersed by macrophages in the process of phagocytosis, consistent with diagnosis of Burkitt lymphoma. **(B)** Immunohistochemical exam demonstrated diffusely positive for CD 20.

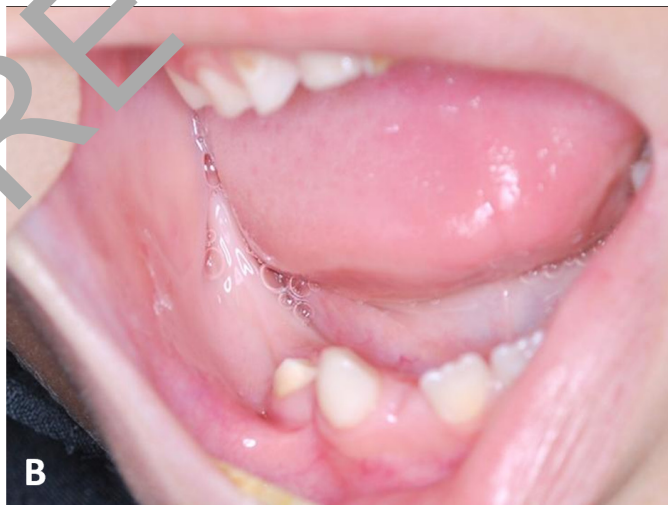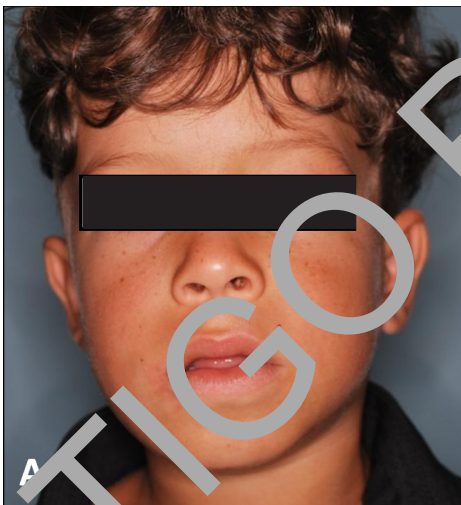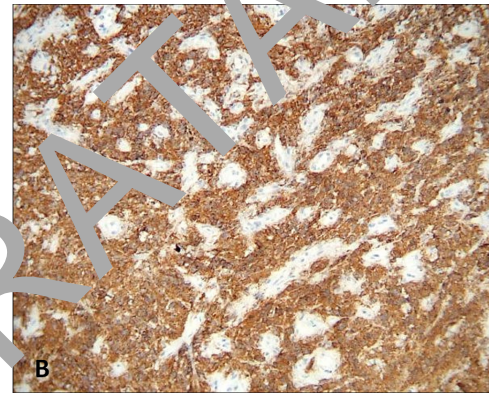
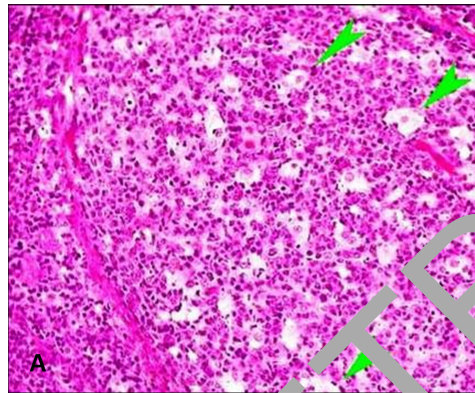


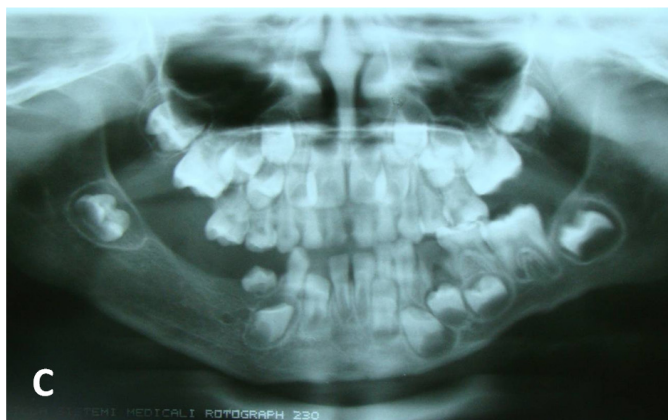Fig. 4. (A) The patient presented remission of the disease after 11 months of chemotherapy. **(B)** The intraoral aspect after remission of the lesion. **(C)** The radiographic aspect after remission of the lesion.



Description of the Case 2

A 24-year-old man was referred to the Oral Diagnosis Section at the School of Dentistry of Goiânia, Paulista University –UNIP/GO, Goiânia, GO, Brazil, with a complaint of a rapidly growing painful mass on the right mandibular gingiva for three months. In the anamnesis, the patient did not declare similar cases in his family. Personal and family histories, and laboratory tests were uneventful. Clinical examination showed facial asymmetry on the right face and submandibular and submental lymphadenomegaly. Intraorally, there was an expansive mass in the right maxillary and mandibular regions and ulcerated exophytic lesion in the hard palate (Fig. 5). Because of the impossibility of opening the mouth due to severe trismus, the patient was referred to the Department of Head and Neck to assess the palatal lesion. Computed tomography scan of sinuses of the face showed an expansive

formation in the right parapharyngeal space extending to the base of the skull. A biopsy of right parapharyngeal and palatal region histopathologically evidenced the presence of small hyperchromatic cells with pleomorphism in shape and size, suggesting a histopathological pattern of “starry sky”. Then, an immunohistochemical analysis showed a positive reaction for CD-20, but not for Pancytokeratin, CD-138, CD-56, establishing the diagnosis of diffuse B-cell non-Hodgkin's lymphoma.

The patient has undergone chemotherapy with CHOP regime. After five rounds of chemotherapy, the patient received a course of radiotherapy as a concomitant treatment. The patient's condition gradually deteriorated over 15 months, and he had severe pain, trismus and weight loss (Fig. 6). The tumor progressed to IVB stage, with evidence of involvement of inguinal ganglion and was non-responsive to treatment.

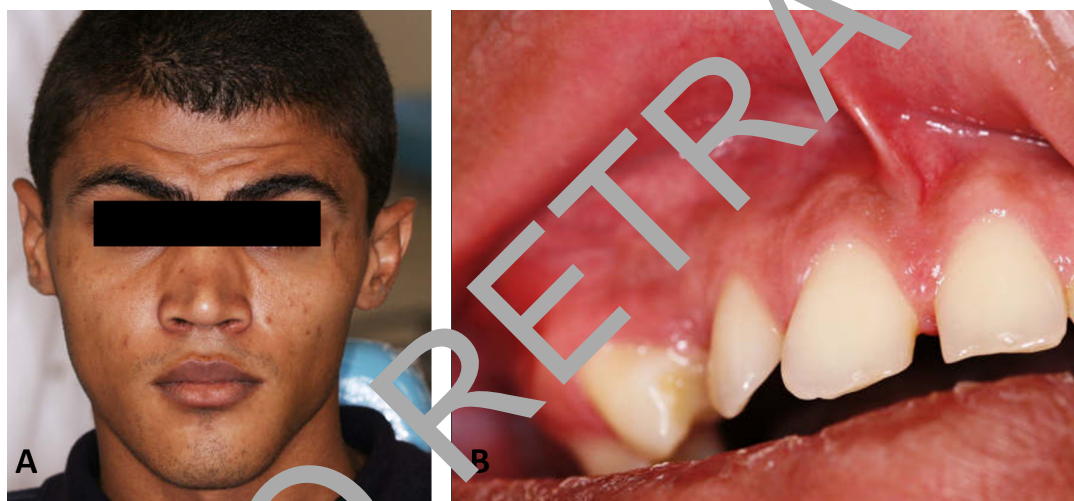

Fig. 5. Facial asymmetry on the right side. Clinic exam demonstrated the expansive mass in the right maxillary region.

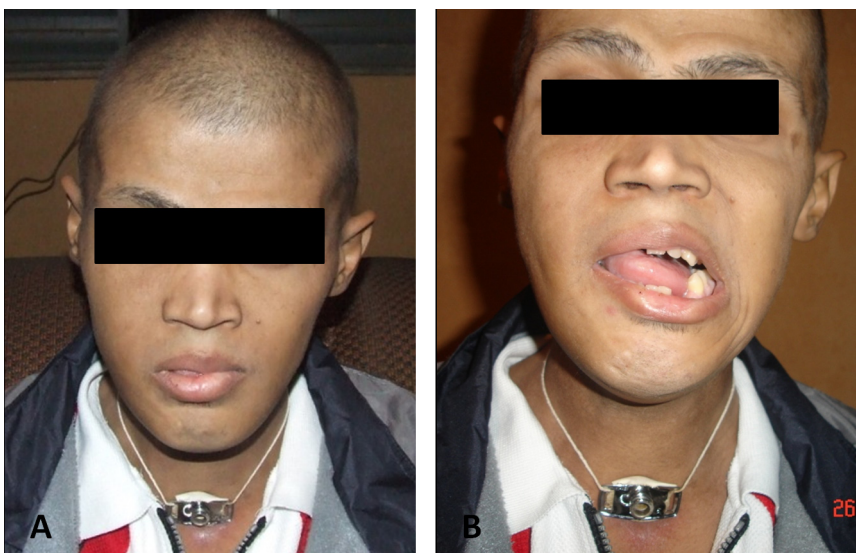

Fig. 6. After 15 months, the patient had pain, limited opening mouth and seizures.

Discussion

Lymphomas account for about 10% of all malignant diseases in children fewer than 15 years of age. Sixty percent of the lymphomas occurring in children are non-Hodgkin's lymphomas (NHL). Burkitt's lymphoma (BL) is a subgroup of NHL with distinct epidemiological, clinical, pathological, immunological and molecular cytogenetic characteristics. The tumor consists of high grade, diffuse, small non-cleaved B-cell lymphocytes (6). The Burkitt's lymphoma, a CD 19, CD 20, CD 21 and surface immunoglobulin positive B cell lymphoma with the histological appearance of a "starry sky", is classified in three types, endemic, sporadic and immunodeficiency associated (7).

Head and neck involvement in Burkitt's lymphoma includes the facial bones, jaws and other extra nodal sites. The jaws are involved in 7-29% of the cases in studies of non-endemic BL and in 55% of the cases in Africa. The main clinical signs and features of the jaws in the diagnosis of BL are: loosening and extrusion of the molar teeth (primary and permanent), premature shedding of primary molars and premature eruption of permanent molars, swelling of alveolar regions and jaws, and gingival enlargement (6).

The frequency of the correlation between Epstein-Barr virus (EBV) infection and BL varies greatly in different parts of the world (6). At last 90% of endemic Burkitt's lymphoma cases are thought to be EBV-associated, with evidences

including the presence of EBV-DNA clonally integrated into the tumor tissue and serum-epidemiological associations with EBV antibodies (8).

The variable EBV association in the three variants has suggested the possibility of the virus being a passenger in the neoplastic process and not the initiating factor. In all variants, irrespective of the EBV status, constitutive activation of the *c-myc* oncogene through its translocation into one of the immunoglobulin loci is clearly the key factor in the oncogenesis of Burkitt's lymphoma (9).

Burkitt's lymphoma is one of the first human malignancies shown to be curable by chemotherapy alone. The combination of cyclophosphamide, doxorubicin, vincristine and predinison is one example of drug therapy recommended for this case. Radiotherapy is used for central nervous system disease that is resistant to chemotherapy, it has been reported to be useful in certain emergency cases, such as airway obstruction. Bone marrow transplantation may be necessary after completion of chemotherapy cycles. The surgical management of Burkitt's lymphoma is limited to biopsy (10).

The prognosis of Burkitt's lymphoma depends on the extent of the disease, the patient's age and the timing of diagnosis (10). The prognosis is excellent for the early stages of the disease (I,II) with event-free survival rates of 85-100%, in advanced stages (III,IV) the survival rate is 75-85% (6). Herein we described one case of Burkitt lymphoma with good prognosis and one case with bad prognosis.

References

1. Yustein JT, Dang CV. Biology and treatment of Burkitt's lymphoma. *Curr Opin Hematol* 2007;14:375-81.
2. Ferry JA. Burkitt's lymphoma: clinicopathologic features and differential diagnosis. *Oncologist* 2006;11:375-8.
3. Burkitt D. A sarcoma involving the jaws of African children. *Br J Surg* 1958;46:218-23.
4. Lund DJ, Rodd H, Craig GT. Burkitt's lymphoma presenting with jaw lesions in a Young White girl. *J Oral Maxillofac Surg* 1997;35:438-41.
5. Ardekian L, Rabinmial A, Rosen D, Abu-El-Naaj I, Peled M, Laufer D. Burkitt's lymphoma of the oral cavity in Israel. *J Cranio-Maxillofac Surg* 1999;27:294-297.
6. Shapira J, Peylanhamu N. Burkitt's Lymphoma. *Oral Oncol* 1998;3:15-23.
7. Tsuchiya S. Diagnosis of Epstein-Barr virus-associated diseases. *Crit Rev Oncol Hematol* 2002;44:227-38.
8. Mutalima N, Molyneux E, Jaffe H, Kamiza S, Borgstein E et al. Associations between Burkitt lymphoma among children in Malawi and infection with HIV, EBV and malaria: Results from a case-control study. *PLoS One* 2008;3:1-7.
9. Rezk AS, Weiss LM. Epstein-Barr virus-associated lymphoproliferative disorders. *Human Pathol* 2007;38:1293-304.
10. Jan A, Vora K, Sándor GKB. Sporadic Burkitt's lymphoma of the jaws: the Essentials of prompt life-saving referral and management. *J Can Dent Assoc* 2005;71:165-8.