

# Influence of water pH in oral changes caused by cadmium poisoning: an experimental study in rats

*Influência do pH da água nas alterações bucais causadas pela intoxicação por cádmio: um estudo experimental em ratos*

Bianca Keller Lima MARTELLI<sup>a</sup>, Diogo Milani de MELO<sup>a</sup>, Gisele Alborghetti NAI<sup>a</sup>,  
José Luiz Santos PARIZI<sup>a</sup>

<sup>a</sup>Faculdade de Odontologia de Presidente Prudente, UNOESTE – Universidade do Oeste Paulista,  
Presidente Prudente, SP, Brasil

## Resumo

**Objetivo:** Avaliar o efeito do pH da água de beber nas alterações bucais provocadas pela intoxicação por cádmio. **Material e método:** Foram utilizados 90 ratos Wistar, adultos, machos, divididos em 6 grupos: A – 15 ratos que receberam solução de cloreto de cádmio (400 mg/L) na água de beber com pH neutro (pH 7,0); B – 15 ratos que receberam solução de cloreto de cádmio (400 mg/L) na água com pH ácido (pH 5,0); C – 15 ratos, os quais receberam solução de cloreto de cádmio (400mg/L) na água com pH básico (pH 8,0). D – 15 ratos que receberam água com pH ácido (pH 5,0); E – 15 ratos que receberam água com pH básico (pH 8,0); F – 15 ratos que receberam água com pH neutro (pH 7,0). Todos os animais foram eutanasiados 6 meses após o início do experimento. Foram retirados fragmentos da mucosa jugal, língua e glândula salivar de cada animal para análise microscópica. **Resultado:** Não foram observadas alterações na mucosa jugal, mucosa da língua ou nas glândulas salivares em nenhum dos grupos avaliados. **Conclusão:** Mesmo em alta concentração o cádmio adicionado à água de beber não mostrou causar dano a mucosa bucal ou às glândulas salivares, independente do pH da água.

**Descritores:** Cádmio; acidificação; neoplasias bucais; glândulas salivares; exposição ambiental.

## Abstract

**Objective:** This study aims to evaluate the effect of the pH of drinking water in the oral changes caused by cadmium poisoning. **Material and method:** Ninety male Wistar rats were divided into the following six groups: A - 15 rats were given cadmium chloride solution (400 mg/L) in drinking water with a neutral pH (pH 7.0); B - 15 rats received cadmium chloride solution (400 mg/L) in drinking water with an acidic pH (pH 5.0); C - 15 rats were treated with a cadmium chloride solution (400 mg/L) in drinking water with a basic pH (pH 8.0); D - 15 rats received drinking water with an acidic pH (pH 5.0); E - 15 rats were given drinking water with a basic pH (pH 8.0); F - 15 rats received water with a neutral pH (pH 7.0). All animals were sacrificed six months after the beginning of the experiment. A biopsy of the buccal mucosa, tongue and salivary gland of each animal was taken for microscopic analysis. **Result:** No changes were observed in the buccal mucosa, tongue mucosa or salivary glands in any of the groups. **Conclusion:** Drinking water that contains a high concentration of cadmium with differing pH levels demonstrated no damage to the oral mucosa and salivary glands of male Wistar rats.

**Descriptors:** Cadmium; acidification; mouth neoplasms; salivary glands; environmental exposure.

## INTRODUCTION

Cadmium (Cd) is a heavy metal with an atomic number of 48 and molecular weight of 112.411 that was discovered around 1815 in ores containing carbonate and zinc. Cadmium is one of the most abundant non-essential elements found in the environment and is widely used in industrial applications<sup>1</sup>. The main routes of contamination by cadmium for humans are inhalation or ingestion. The lungs take in approximately 10 to 40% of inhaled cadmium, whereas cadmium ingested from food

and water is poorly absorbed in the gastrointestinal tract (5-7%) with the majority of it being eliminated through feces<sup>2</sup>.

The components of cadmium are used as product stabilizers, such as polymers of vinyl chloride (PVC), pigments, and often in nickel cadmium batteries and rechargeable batteries. Cadmium is widely used as an anticorrosion agent and is present as a contaminant in phosphate-based fertilizers<sup>3</sup>, which can promote environmental contamination. Moreover, cadmium is

a component of cigarette smoke and, therefore, can contaminate populations that are in contact with this smoke<sup>1</sup>.

According to the International Register of Potentially Toxic Chemicals of the United Nations Environment Program, the silver alloys used in orthodontics release by-products, such as cadmium, copper and zinc, which can be absorbed by the richly vascularized oral tissues after installing the brace<sup>4</sup>. Concentration analysis of metals after the placement of the appliance showed that copper remains in the mouth longer (24 hours) than cadmium (10 minutes)<sup>5</sup>. In addition, cadmium is found in the formulation of alginate (irreversible hydrocolloid) with the aim of improving its physical, chemical and mechanical properties. The alginates contact the oral mucosa during the molding process, which enables its harmful substances to be absorbed by the adjacent oral tissues. In addition to patients undergoing molding, the dentists and auxiliary staff, are prone to inhalation of dust during handling of the material<sup>6-8</sup>.

Most foods contain cadmium. Two-thirds of the daily cadmium intake comes from products of plant origin and a third from products of animal origin, mainly fish, mollusks and crustaceans<sup>3</sup>. One of the main factors that affect the availability of heavy metals to plants is the soils pH, which has, in general, been inversely related to the availability of these elements<sup>9</sup>. However, to date no studies have evaluated how differing concentrations of pH could influence the uptake and toxicity of cadmium in animals.

In addition to occupational exposure, cadmium contaminates many foods and is found in dental products and cigarette smoke, thus, can affect humans. A better understanding of the changes caused by cadmium in the body and possible ways to block these changes are important for preventing diseases related to this element. There are few studies in the literature that evaluate changes caused by cadmium in the oral mucosa and salivary glands<sup>10,11</sup>.

The aim of this study was to evaluate the effect of pH on possible oral abnormalities caused by cadmium poisoning.

## MATERIAL AND METHOD

### 1. Approval by the Ethics Committee on Animal Use

The Ethics Committee on Animal Use of the Universidade do Oeste Paulista (CEUA-UNOESTE; Protocol 1161) approved this study.

### 2. Animal Protocol

For the current study, 90 adult male Wistar rats (*Rattus norvegicus albinus*) weighing between 200-250 g were utilized. The rats were separated and grouped by fours in large rectangular boxes that measured 49 × 34 × 16 cm, which could house up to five adult rats. The rats were kept in air-conditioned animal houses under controlled humidity, temperature and photoperiod (12 hours of light and dark).

Cadmium exposure was through the administration of cadmium chloride (CdCl<sub>2</sub>; Sigma Chemical Company, St. Louis, MO, USA) using the following specifications: hydration of at least 98% and water content of approximately 2.5 mol/mol. The cadmium chloride solution (400 mg/L; adapted to Motta et al.<sup>10</sup>) was administered to animals in the drinking water daily for six months<sup>10</sup>. The drinking water was refreshed three times a week to avoid pH change. The wastewater solutions containing cadmium were sent to a residue center of the Universidade do Oeste Paulista and neutralized for later disposal. Residual water in the troughs was measured at each change of solution to record the mean intake of each animal.

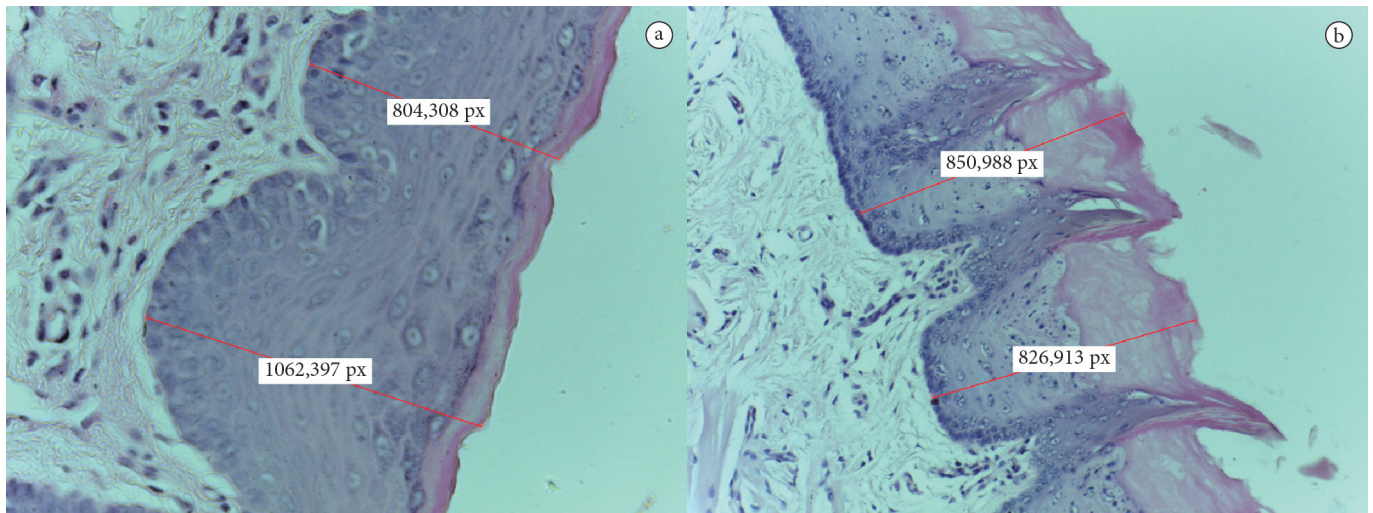
The animals were divided into the following 6 groups: A - 15 rats that received a solution of cadmium chloride in drinking water at neutral pH (pH 7.0); B - 15 rats that received a solution of cadmium chloride in drinking water with a pH acid (pH 5.0); C - 15 rats that received a solution of cadmium chloride in water with basic pH (pH 8.0); D - 15 rats that received drinking water with acid pH (pH 5.0); E - 15 rats that received drinking water with basic pH (pH 8.0); and F - 15 rats that received drinking water with a neutral pH (pH 7.0) (control group).

All of the animals were euthanised six months after the beginning of the experiment. Euthanasia was performed using thiopental (Syntec, USA) at a dose of 100 mg/kg administered into the peritoneal cavity. The absence of breathing movements or heart rate and loss of reflex was indicative of death<sup>12</sup>. Fragments from the buccal mucosa, tongue and salivary glands (parotid, submandibular and sublingual) were taken from each rat for microscopic analysis.

### 3. Pathological Analysis

Removed fragments were fixed in 10% formalin (Chemical Kinetics, São Paulo, Brazil) for 24 hours, subjected to standard histological processing, and paraffin embedded (Dynamic Analytical Reagents, São Paulo, Brazil). Sections of 5 µm thick were obtained and stained with hematoxylin-eosin (HE; Dolles, São Paulo, Brazil).

Histopathological analysis was performed to determine the type of lesion found in the buccal mucosa, tongue and salivary glands, including precancerous or dysplastic lesions (0 = absent, 1 = mild, 2 = moderate, 3 = severe), benign and malignant neoplasias. Additionally, the following parameters with their scores were evaluated as follows: congestion (0 = absent, 1 = mild, 2 = moderate, 3 = severe); presence of hyperkeratosis (0 = absent, 1 = mild, 2 = moderate, 3 = severe); presence of parakeratosis (0 = absent, 1 = focal, 2 = diffuse), the presence of inflammatory infiltrate intensity (0 = absent, 1 = mild, 2 = moderate, 3 = severe), inflammatory cell type present (polymorphonuclear and/or mononuclear cells) and presence of individual cell necrosis (0 = absent, 1 = present). Thickness of the buccal mucosa and tongue measurements were taken from two areas in each fragment using the image analysis system Leica Application Suite 4.2.0 LAS (Leica Microsystems, Switzerland; Figures 1a and 1b). The thickness of the tongue mucosa was performed in the dorsal portion. The analysis of the slides was blinded and performed by a single experienced observer (GAN).



**Figure 1.** An animal from Group A. a) Photomicroscopy of the buccal mucosa showing the pattern for measuring the thickness of the epithelium. b) Photomicroscopy of the tongue mucosa showing the pattern for measuring the thickness of the epithelium on the dorsal face (Hematoxylin-eosin; 200x magnification). px: pixel.

#### 4. Characterization of Dysplastic Lesions

The diagnosis of epithelial dysplasia is established when at least two architectural changes and two cytological are present in the epithelium. The architectural changes include: irregular epithelial stratification, loss of polarity of basal cells, epidermal ridges “drop in”, increased number of mitotic figures, abnormal mitosis on the surface, corneal dyskeratosis and pearls. Cytological abnormalities (or cytological atypia) include: abnormal variation in the size of nuclei and cells, cellular pleomorphism, increased nuclear-cytoplasmic ratio, atypical mitotic figures, increased number and size of nucleoli and nuclear hyperchromasia<sup>13</sup>. Dysplasia is a spectrum, divided into mild, moderate and severe, depending on the thickness of the epithelium compromised by the alterations<sup>14</sup>. Mild dysplasia is an architectural change that is limited to the lower third of the epithelium. In moderate dysplasia, amendment extends to the middle third. Severe dysplasia undertakes more than two thirds of the epithelium and has a higher degree of atypia<sup>14</sup>.

#### 5. Statistical Analysis

Variables were not normally distributed according to the Kolmogorov-Smirnov ( $p = 0.001$ ) test and showed no homogeneity of variances ( $p = 0.001$ ) by Levene's test; therefore, we chose to use the nonparametric Kruskal-Wallis test followed by multiple comparisons via the post-hoc Dunn test. Statistical tests were performed at a significance level of 5%.

### RESULT

Five animals died during the course of the study (one in Group A, one in Group C, one in Group D and two in group E). The cause of death was acute pulmonary edema in groups A and C, which is a complication associated with cadmium exposure<sup>3</sup>. In groups D and E, we were not able to establish the cause of death after the autopsy.

The average water intake per animal per day in Group A was 55 ml, 57 ml in Group B, 52 ml in Group C, 60 ml in Group D, 70 ml in Group E and 73 ml in Group F, with no significant differences between the groups ( $p > 0.05$ ).

No congestion, hyperkeratosis, parakeratosis, and necrosis of individual cells, dysplasia, benign or malignant tumors in the buccal mucosa, tongue or salivary glands in any of the studied groups were observed.

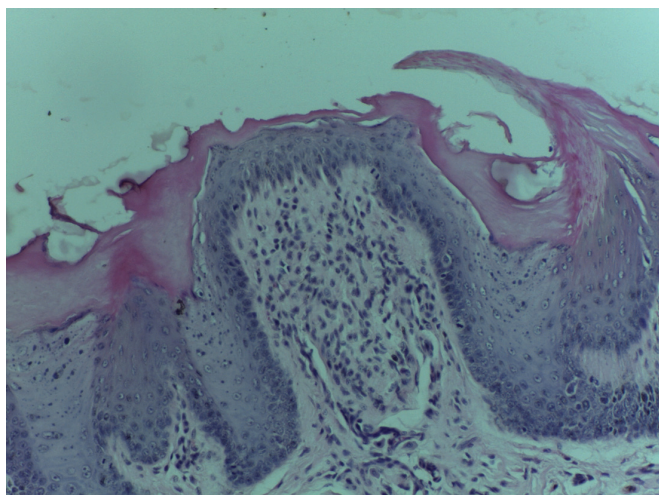
Inflammatory infiltrate was observed in the tongues of 50% of the group D animals, which received drinking water with acidic pH (pH 5.0;  $p < 0.05$ ), with mild intensity and predominance of lymphocytes (Figure 2).

Histomorphometric analysis of the thickness of the buccal mucosa showed no significant differences between groups ( $p = 1.000$ ), as well as the tongue mucosa ( $p = 1.000$ ) (Table 1).

### DISCUSSION

It is estimated that approximately 30,000 tons of cadmium is released into the environment annually, which contains 4,000-13,000 tons from anthropogenic origin, including smoke, dust and debris from ore smelters, incineration of products made from cadmium and burning of fossil fuels. Fertilizers and their agricultural sludge, tobacco, municipal waste water and sewage discharges are other important sources of cadmium<sup>15</sup>, besides vegetables, fish, mollusks and crustaceans<sup>3</sup>. According to the World Health Organization, the maximum daily intake of cadmium should be 1 mg/kg of body weight<sup>1</sup>. In the current study, animals were exposed to 400 mg of cadmium/liter of water ingested, a value well above the permissible daily intake, therefore, simulating cases of environmental contamination on a large scale.

Although *in vitro* studies have demonstrated the genotoxic potential of cadmium<sup>16</sup>, it does not seem to demonstrate a carcinogenic action on the oral mucosa during chronic exposure, shown by the current study among other previously published studies<sup>10,11</sup> who found a lack of dysplastic or neoplastic lesions



**Figure 2.** Photomicroscopy of the tongue mucosa showing mild inflammatory infiltrate in the submucosa (animal from Group D; Hematoxylin-eosin; 200x magnification).

**Table 1.** Median thickness of the buccal mucosa and tongue mucosa in each group studied

	Buccal mucosa (px <sup>*</sup> )	Tongue mucosa (px <sup>*</sup> )
Group A	650,52 <sup>a</sup>	775,45 <sup>a</sup>
Group B	736,39 <sup>a</sup>	765,60 <sup>a</sup>
Group C	706,71 <sup>a</sup>	723,13 <sup>a</sup>
Group D	601,93 <sup>a</sup>	765,90 <sup>a</sup>
Group E	554,10 <sup>a</sup>	739,11 <sup>a</sup>
Group F	573,21 <sup>a</sup>	882,81 <sup>a</sup>

Lowercase letters compare groups at the same time. Different lowercase letters:  $p < 0.05$ . \*px: pixel.

(benign and malignant) in the oral epithelium. The cells of the keratinized epithelium and salivary glands undergo reduction and variation in nuclear shape by chronic exposure to cadmium<sup>10</sup>. Among the buccal cell changes presented in offspring of rats given cadmium during lactation, there was a reduction of cytoplasmic volume and an increase in the number of cells per mm<sup>3</sup>, as well as thinning of the keratinous layer<sup>11</sup>. A previous study has shown significant changes in general measurements of the nucleus from cells in the floor of the mouth, such as perimeter, area and volume. Nevertheless, the nucleus' eccentricity, contour and shape showed no significant changes<sup>11</sup>.

Although some studies on the effects of cadmium have shown alteration of the oral epithelium and salivary glands by chronic cadmium exposure<sup>10,11</sup> as described above, in this study, despite exposure to cadmium having been greater than in anterior

study<sup>10</sup>, which used 300 mg/L, we observed no change in the buccal mucosa, tongue or salivary glands.

The previous studies were conducted using younger animals (puppies<sup>11</sup> and adolescents<sup>10</sup>), whereas the present study was conducted with adult animals, which may have been a factor that influenced the absence of alterations in the buccal epithelium, tongue and salivary glands. In puppies, epithelia are more immature and, thus, more subject to the action of external agents. Another factor that may have influenced these results is the prolonged exposure time (a situation that occurs in dietary exposure) of cadmium because it accumulates mainly in the kidneys<sup>1</sup>.

The only change observed in this study was mild inflammation in the tongue of animals exposed to water at acidic pH, but not with cadmium (group D). Therefore, the acidity of the water may cause irritation of mucous membranes. The inflammatory infiltrate is predominantly lymphocytic and may be due to the chronic aggression of the tongue mucosa. Therefore, ordinance no. 2,914 on December 12, 2011 of the Brazilian Ministry of Health that aims to determine parameters for drinking water for human consumption determined that the ideal pH is from 6.0 to 9.5<sup>17</sup>. The specific irritation of the tongue may be because animals use their tongue to aid in water uptake.

It is important to remember that there is a difference between the ability of an agent to cause damage and the possibility that this agent is harmful. The intrinsic potential of a toxic agent to harm health can only be achieved if it reaches a critical organ and causes damage<sup>18</sup>. Therefore, our results suggest that the oral mucosa and salivary glands are not target organs of cadmium toxicity, although they are in direct contact with this heavy metal.

Studies that evaluate the animal's internal dose of cadmium may help understand the dose-response effect on the oral mucosa. The assessment of different exposure times (acute, subacute, subchronic and chronic greater than six months) and the use of animals in different stages of life (puppies, adolescents and adults) will be important to determine the time it takes to develop a buccal lesion related to cadmium exposure as well as the most affected age.

## CONCLUSION

We conclude that high concentrations and chronic exposures (six months) of cadmium in drinking water did not cause damage to the buccal mucosa, tongue mucosa or salivary glands in adult animals, independent of the water pH.

## ACKNOWLEDGMENTS

The Edvaldo Mamede dos Santos for preparing the solutions.

## REFERENCES

---

1. World Health Organization. Environmental Health Criteria, cadmium. Geneva: World Health Organization; 1992. v. 134.
2. Souza MCB, Mancebo ACA, Santos HCN, Costa ALR, Taitson PF, Moreira MFR. Fatores ambientais e reprodução: metais (chumbo e cádmio). Fundamentação da pesquisa. JBRA Assist Reprod. 2010;14(4):38-42.
3. Järup L. Hazards of heavy metal contamination - impact of environmental pollution on health: balanced risk. Br Med Bull. 2003;68:167-82. PMID:14757716. <http://dx.doi.org/10.1093/bmb/ldg032>
4. Menezes LM, Freitas MPM, Gonçalves TS. Biocompatibilidade dos materiais em Ortodontia: mito ou realidade? Rev Dental Press Ortodon Ortop Facial. 2009;14(2):144-7. <http://dx.doi.org/10.1590/S1415-54192009000200016>
5. Mikulewicz M, Chojnacka K, Wołowiec P. Release of metal ions from fixed orthodontic appliance. Angle Orthod. 2013. DOI: 10.2319/113012-911.1 <http://dx.doi.org/10.2319/113012-911.1>
6. Braga AS, Braga SRS, Catirse ABCEB, Vaz LG, Spadaro ACC. Potencial tóxico dos alginatos para uso odontológico. Rev Ciênc Farm Básica Apl. 2007; 28(2):153-8.
7. Pithon MM, Santos RL, Martins FO, Romanos MTV, Araujo MTS. Avaliação da citotoxicidade de quatro alginatos utilizados na Odontologia. Rev Bras Odontol. 2009;66(2):207-10.
8. Pithon MM, Santos RL, Martins FO, Romanos MTV. Efeito citotóxico de Alginatos Odontológicos sobre células fibroblastóides. ROBRAC: Rev Odontol Bras Central. 2010;18(48):22-5.
9. Cunha KPV, Nascimento CWA, Pimentel RMM, Accioly AMA, Silva AJ. Disponibilidade, acúmulo e toxidez de cádmio e zinco em milho cultivado em solo contaminado. Rev Bras Ci Solo. 2008;32:1319-28. <http://dx.doi.org/10.1590/S0100-06832008000300039>
10. Motta ACF, Migliari DA, Gioso MA, Komesu MC, Sala MA, Lopes RA. The carcinogenic potential of cadmium in the palatal and gingival epithelium of rats. A morphologic and morphometric analysis. Braz J Vet Res Anim Science. 2004;41:183-8. <http://dx.doi.org/10.1590/S1413-95962004000300006>
11. Picoli LC, Watanabe IS, Lopes RA, Sala MA, Picoli F. Effect of cadmium on the floor of the mouth on rats during lactation. Braz Oral Res. 2004;18(2):105-9. PMID:15311311. <http://dx.doi.org/10.1590/S1806-83242004000200003>
12. Paiva FP, Mafilli VV, Santos ACS. Curso de manipulação de animais de laboratório. Fundação Osvaldo Cruz. Centro de Pesquisas Gonçalo Muniz. 2005 [citado em 2013 Set 3]. Disponível em: [http://www.bioteriocentral.ufc.br/arquivos/apostilha\\_manipulacao.pdf](http://www.bioteriocentral.ufc.br/arquivos/apostilha_manipulacao.pdf)
13. Hildebrand L, Carrard V, Lauxen I, Quadros O, Chaves A, SantAna-Filho M. Evaluation of cell proliferation rate in non-dysplastic leukoplakias. Med Oral Patol Oral Cir Bucal. 2010;15(2):e328-34. PMID:19767704. <http://dx.doi.org/10.4317/medoral.15.e328>
14. Barnes L, Eveson JW, Reichart P, Sindransky D, editors. World Health Organization Classification of Tumours. Pathology and Genetics of Head and Neck Tumours. IARC Press: Lyon; 2005.
15. Castro-González M., Méndez-Armenta M. Heavy metals: Implications associated to fish consumption. Environ Toxicol Pharmacol. 2008;26:263-71. PMID:21791373. <http://dx.doi.org/10.1016/j.etap.2008.06.001>
16. Waalkes MP. Cadmium carcinogenesis. Mutat Res. 2003;533:107-20. PMID:14643415. <http://dx.doi.org/10.1016/j.mrfmmm.2003.07.011>
17. Brasil. Ministério da Saúde. Portaria nº 2914, de 12 de Dezembro de 2011. Dispõe sobre os procedimentos de controle e de vigilância da qualidade da água para o consumo humano e seu padrão de potabilidade. Diário Oficial da União. 14 dez; Seção 1. p. 39-46. 2011.
18. Organização Pan-americana da Saúde (OPAS) no Brasil. Doenças relacionadas ao trabalho: manual de procedimentos para os serviços de saúde. Brasília: Ministério da Saúde, 2001 [citado em 2013 Set 3]. Disponível em: [www.opas.org.br](http://www.opas.org.br)

## CONFLICTS OF INTERESTS

---

The authors declare no conflicts of interest.

## CORRESPONDING AUTHOR

---

Gisele Alborghetti Nai

Departamento de Patologia, UNOESTE – Universidade do Oeste Paulista, Rua José Bongiovani, 700, 19050-680 Presidente Prudente - SP, Brasil

e-mail: [patologia@unoeste.br](mailto:patologia@unoeste.br)

Received: October 4, 2013

Accepted: March 3, 2014