

Diagnosis of the nasolabial cyst: case report

Diagnóstico do cisto nasolabial: relato de caso

Ana Rafaela Motta MOITINHO^a, Cristiano Leal REZENDE^a, Sarah Mascarenhas SOUZA^a, Arlei CERQUEIRA^a, Bruno Andrade Cantharino de CARVALHO^a, Márcio Campos OLIVEIRA^a

^aUEFS – Universidade Estadual de Feira de Santana, Feira de Santana, BA, Brasil

Resumo

Introdução: O cisto nasolabial está classificado no grupo dos cistos epiteliais de desenvolvimento, não odontogênicos. De ocorrência rara, situa-se sob o sulco nasolabial próximo à inserção da asa do nariz externamente ao tecido ósseo maxilar. Caracteriza-se por uma tumoração flutuante, geralmente assintomática que promove a elevação da asa do nariz. **Objetivo:** Relatar um caso clínico de cisto nasolabial abordando aspectos clínicos, histopatológicos e radiográficos, de modo a alertar o profissional quanto à sua responsabilidade no diagnóstico. **Material e método:** Paciente do sexo feminino com um aumento de volume na região de lábio superior e asa do nariz. Após exame clínico, exame radiográfico e realização da punção aspirativa, realizou-se a enucleação cirúrgica total do cisto e encaminhamento do material coletado para análise histopatológica. **Conclusão:** O cirurgião-dentista deve estar atento quanto ao diagnóstico precoce, pois, a inobservância da lesão nos estágios iniciais pelo paciente não é incomum.

Descritores: Cistos; diagnóstico; estomatologia.

Abstract

Introduction: The nasolabial cyst is classified in the group of non-odontogenic epithelial developmental cysts. Their occurrence is rare, however, they are located in the nasolabial sulcus, close to the alar insertion in the nose, external to the maxillary bone tissue. It is characterized as a floating tumor, generally asymptomatic, which promotes elevation on the nasal ala. **Objective:** To report a case of nasolabial cyst addressing clinical, histopathological and radiological aspects, in order to alert professionals as regards their responsibility in diagnosis. **Material and method:** Female patient with a swelling in the region of the upper lip and nasal ala. After clinical examination, radiographic examination, puncture and aspiration, total surgical enucleation of the cyst was performed and the material collected was sent for histopathologic analysis. **Conclusion:** the dentist must be alert in order to make an early diagnosis, because it is not uncommon to overlook the lesion in the early stages.

Descriptors: Cysts; diagnosis; oral medicine.

INTRODUCTION

The nasolabial cyst, also known as the nasoalveolar cyst, is a rare non odontogenic cyst, of origin specifically in the maxillary soft tissues, and is situated in the region of the upper lip right below the ala of the nose¹. It was described for the first time by Zuckerkandl in 1882, and since then many theories have been proposed with respect to its etiopathogenesis, however, two main theories have been recorded. The first considers the nasolabial cyst to be “fissural”, originating from epithelial remnants retained along the line of fusion of the lateral, median and maxillary nasal processes². The second, more plausible and currently accepted theory suggests a possible embryonic origin from embryonic remainders of the inferior and anterior portion of the nasolacrimal duct³.

Its most relevant clinical characteristic is a tumefaction in the superior region of the labial sulcus, lateral to the median line,

close to the base of the nostril, which promotes elevation of the ala nasi and deformation of the top lip, with obliteration of the nasolabial sulcus. Difficulty in breathing through the nose and disturbances in the adaptation of maxillary dental prostheses are rarer symptoms, and unless infected, exhibit no painful symptomatology. In the majority of episodes, the nasolabial cyst is unilateral, and may be bilateral in 10% of cases⁴. It is slow growing and on palpation, is shown to be flaccid and floating¹. Puncture is a fundamental maneuver for preparing the diagnosis.

This lesion has a strong predilection for women⁵, in a ratio of approximately 3:1³, with a mean age between the fourth and fifth decades of life, and higher incidence in individuals of the black race⁴.

Because it is a lesion that occurs in soft tissues, in the majority of cases there is no radiographic image, unless

radiographic contrast is injected into the hollow passage of the cyst to facilitate its visualization. However, its growth may determine compression of palatine structures, especially in the lateral inferior limits of the nasal fossae, allowing observation of deviation of the line demarcating the floor of the nasal fossa in the occlusal radiographic exam⁶. In addition to this, the pressure exerted by the nasolabial cyst may produce superficial erosion of the external surface of the maxilla^{7,8}.

Histologically, the nasolabial cyst is characteristically limited by pseudostratified columnar-type epithelium with caliciform and ciliated cells. Areas of cuboidal epithelium and squamous metaplasia are not uncommon. The cyst capsule is composed of fibrous conjunctive tissue with adjacent muscle tissue^{3,9}.

With regard to the form of treatment, the literature is unanimous in indicating complete surgical excision of the cyst^{3,6,8,9}, with simple enucleation being preformed through intraoral access, with an incision in the gingival labial sulcus and rhombic dissection of the lesion. As the cyst walls are intimately related to the mucosa of the nasal vestibule floor, in the majority of cases, the surgical maneuver may result in laceration of this mucosa. In this case, suturing must be performed with absorbable thread in order to prevent the development of an oronasal fistula. Recurrence is rare, and the prognosis excellent. Nevertheless, one must be careful in order to avoid perforation and collapse of the lesion¹⁰.

CASE REPORT

The patient, a 38-year-old woman, melanoderma, presented to the reference center for oral lesions, having been referred for evaluation with reference to an increase in volume in the region of the top lip and ala nasi on the right side, after a routine dental consultation at a municipal health clinic in the suburb where she lived.

On extraoral physical exam, asymptomatic elevation of the ala nasi and obliteration of the right nasolabial sulcus was observed (Figure 1). The patient related absence of trauma or infection in

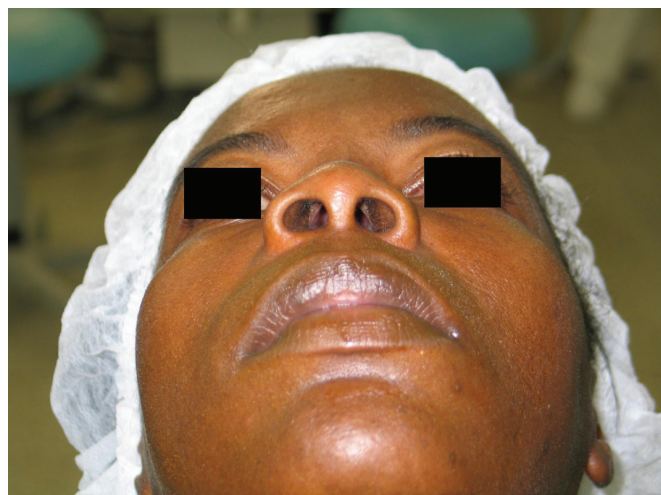

Figure 1. Extraoral aspect of lesion in which elevation of right ala nasi and disappearance of nasolabial sulcus on same side is observed.

the region, and that the swelling was perceived approximately six months previously, an progressively increased in size.

During the intraoral exam, a single, mobile, soft, floating mass was detected, which extended from the superior vestibule fornix in the direction towards the nose, with a pink coloring (similar to that of the mucosa) measuring approximately 2.5 cm. No relevant data were found during the occlusal radiographic evaluation. However, in the panoramic radiograph a radiolucent area was identified in the region referred to (Figure 2), and puncture and aspiration was shown to be positive for viscous yellow liquid. The patient demonstrated no systemic alterations, or base diseases that would contra-indicate the proposed treatment; in this case surgical excision of the lesion via an intraoral approach.

The surgical procedure was performed with extra- and intraoral antisepsis, under infiltrative administration of local anesthetic agents injected into infraorbital and perilesional areas. The incision was made in the gingival labial sulcus between the right maxillary central incisor and the maxillary first molar on the same side. The lesion was individualized by means of rhombic dissection. Nevertheless, although the lesion was individualized, the capsule and nasal mucosa were ruptured due to its intimate relationship with the nasal mucosa (Figure 3).

The material that was collected and sent for histopathological exam consisted of a fragment of soft tissue measuring 1.7x1.5x0.4 cm.

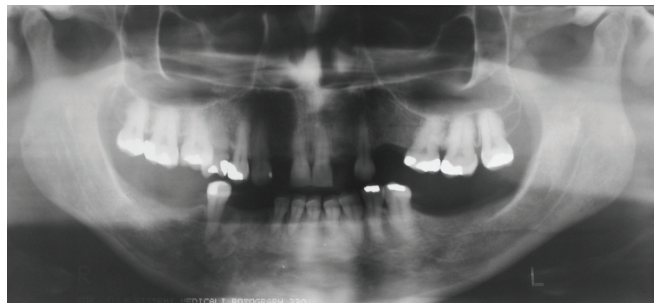

Figure 2. Panoramic radiograph identifying bone rarefaction suggestive of lesion in maxillary right canine region.

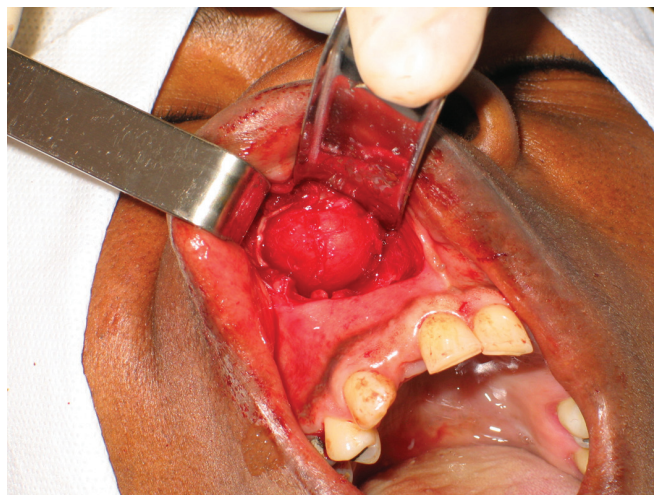


Figure 3. Transoperative aspect: Tissue separation and exposure of lesion, demonstrating defined margins and encapsulation.

Histological exam revealed the presence of fibrous cystic wall lined with pseudostratified cylindrical ciliated epithelium, at times with a few layers of cells and at others with a prickle cell layer without atypical cells, exhibiting calciform cell and mucosal cells, with a final diagnosis of nasolabial cyst (Figure 4).

During follow-up, good healing without phlogiston signs were verified in the post-operative period of seven days, with the suture being maintained and having a good aspect. At the clinical follow-up consultation six months after surgical treatment, there was absence of facial asymmetry and no recurrence of the lesion was observed.

DISCUSSION

Nasolabial cysts are usually unilateral, and may be bilateral in only 10% of cases. They have predilection for the female sex^{3,11,12}, and their occurrence in women is three times higher^{4,5}. They frequently occur during middle age, with a possible prevalence in persons of the black race⁴. Although we have related only once case, the patient revealed the same characteristics as those present in the literature, viz: female sex, middle age, black race, and an asymptomatic lesion.

Clinically the findings of nasolabial cysts are typical, and are characterized by the presence of tumefaction, slow growth at the bottom of the superior vestibular fornix, causing obliteration of the nasolabial sulcus, protrusion of the top lip and elevation of the ala nasi, facts that leave the patient with a certain deformity and facial asymmetry, in addition to discomfort with the use of maxillary dental prosthesis and nasal obstruction^{1,3,11}. These findings are in agreement with the manifestations found in the case here related. This emphasizes the importance of a well performed clinical exam, and the dentist's role at this stage is to prevent the lesion from developing too far, by making an adequate diagnosis.

Diagnosis of the nasolabial cyst is fundamentally clinical⁹. By means of intraoral bidigital palpation, it presents as a floating

tumefaction of soft consistency which, associated with puncture and aspiration, helps to confirm the diagnosis; this fact was also observed in the present study.

As this is a soft tissue lesion, the nasolabial cyst is only detected radiographically if deformation of the lateral and anterior limit of the nasal fossa, with convexity in the posterior direction is detected in the occlusal radiograph¹⁰ or if it causes important bone erosion in the maxillary bone⁷. In this study, a radiolucent area to the right of the anterior nasal spine could be observed in the panoramic radiograph, indicating bone erosion of the maxillary bone.

As stomatological conduct in the treatment of cysts, it is recommended that fragments of the cystic membrane should be sent for histopathological exam, which normally reveals a fibrous cystic wall limited by pseudostratified columnar epithelium with calciform and ciliated cells, which may have areas of cuboid epithelium and squamous metaplasia. These findings were revealed during the histopathological exam in the case referred to in this study.

The treatment indicated included complete surgical enucleation of the cyst by means of intraoral access^{11,12}, because these lesions rarely reach large proportions. It is not rare for the need for removal of part of the nasal mucosa to occur, in order to achieve complete removal of the lesion¹, which in fact occurred in the present case. Its prognosis is favorable and its recurrence is rare^{8,9,11,12}.

In the present case, the oral and nasal structures involved presented excellent healing, without any report of complications or recurrence of the lesion. The correction of facial asymmetry with consequent esthetic restoration was also observed. Nevertheless, we point out that nasal hemorrhage is a relatively common finding in the immediate post-operative period, as a result of rupture of the nasal mucosa, because it is sometimes necessary to remove part of it during the surgical procedure, fundamental for performing adequate therapy in such cases.

FINAL CONSIDERATIONS

Nasolabial cysts are frequently underdiagnosed in their initial stages, and end up leading to progressive facial asymmetry with subsequent esthetic-emotional imbalance. It is fundamental for the dentist to be alert with regard to early diagnosis, because it is not uncommon for the patient to fail to observe the lesion in the initial stages, as may be observed in the present case. Adequate diagnostic conduct and the correct establishment of the possible differential diagnoses allow the adoption of suitable therapeutic measures for each case. The treatment of choice is complete surgical removal of the lesion. The objectives of this strategy is related to the prevention of infection, establishment of histopathological diagnosis and the correction of possible esthetic deformations.

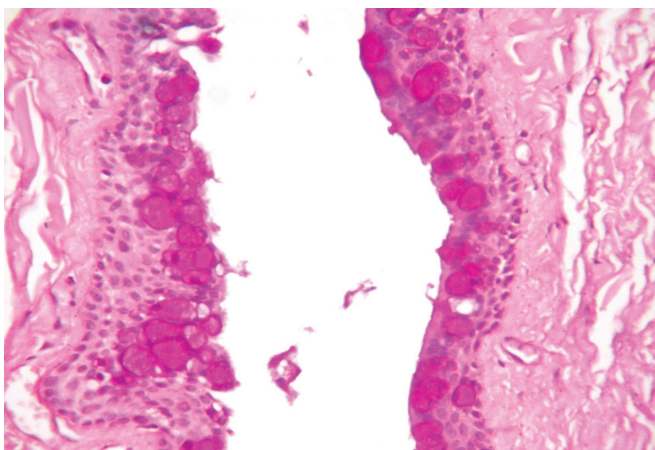


Figure 4. Histopathological aspect exhibiting epithelium undergoing squamous metaplasia with calciform (stained with PAS) and ciliated cells, in addition to thick fibrous capsule (PAS, 200X).

REFERENCES

1. Pereira Filho VA, Silva AC, Moraes M, Moreira RWF, Villalba H. Nasolabial cyst: case report. *Braz Dent J.* 2002; 13(3): 212-4. <http://dx.doi.org/10.1590/S0103-64402002000300015>
2. Aikawa T, Iida S, Fukuda Y, Nakano Y, Ota Y, Takao K, et al. Nasolabial cyst in a patient with cleft lip and palate. *Int J Oral Maxillofac Surg.* 2008; 37: 874-6. <http://dx.doi.org/10.1016/j.ijom.2008.04.016>
3. Nixdorf DR, Peters E, Lung KE. Clinical presentation and differential diagnosis of nasolabial cyst. *J Can Dent Assoc.* 2003; 69 (3): 146-9.
4. El-Hamd KEAA. Nasolabial cyst: a report of eight cases and a review of the literature. *J Laryngol Otol.* 1999; 113: 747-9.
5. Ben Slama L, Zaghbani A, Hidaya S. Nasolabial cyst. *Rev Stomatol Chir Maxillofac.* 2009; 110: 338-9. <http://dx.doi.org/10.1016/j.stomax.2009.09.004>
6. Castro AL. *Estomatologia.* 2ª ed. São Paulo: Santos; 1995.
7. Choi JH, Cho JH, Kang HJ, Chae SW, Lee SH, Hwang SJ, et al. Nasolabial cyst: a retrospective analysis of 18 cases. *Ear Nose Throat J.* 2002; 81: 94-6.
8. Enoki, AM, Pizarro GU, Morais MS, Fernandes DPP, Oliveira PRG. Cisto nasolabial bilateral como causa de obstrução nasal: Relato de caso e revisão de literatura. *Arq Int Otorrinolaringol.* 2012; 16 (1): 121-5. <http://dx.doi.org/10.7162/S1809-48722012000100018>
9. Felix JAP, Ferreira PJE, Correa R, Cantini R, Neto RM, Felix F. Cisto nasolabial bilateral: relato de dois casos e revisão da literatura. *Rev Bras Otorrinolaringol.* 2003; 69 (2): 279-82. <http://dx.doi.org/10.1590/S0034-72992003000200021>
10. Cantisano, MH, Soubhia AMP, Tucci R, Zambon RLD. Cisto nasolabial: revisão de literatura e relato de um caso clínico. *Rev Ciênc Odontol.* 1998; 1(1): 27-30.
11. Soldatelli MV, Maschmann RA; Wobido FB, Pinto JGS, Isolan TMP, Hernandez PAG, Silva Júnior ANN, Santos MA. Cisto nasolabial unilateral: relato de caso clínico. *Rev Ciênc Méd Biol.* 2008; 7(1): 90-5.
12. Tiago RSL, Maia MS, Nascimento GMS, Correa JP, Salgado DC. Cisto nasolabial: aspectos diagnósticos e terapêuticos. *Rev Bras Otorrinolaringol.* 2008; 74(1): 39-43. <http://dx.doi.org/10.1590/S0034-72992008000100007>

CONFLICTS OF INTERESTS

The authors declare no conflicts of interest.

CORRESPONDING AUTHOR

Márcio Campos Oliveira

Departamento de Saúde, UEFS – Universidade Estadual de Feira de Santana, 44036-900 Feira de Santana - BA, Brasil

e-mail: marciopatologiaoral@gmail.com

Received: November 10, 2012

Accepted: March 10, 2013