

## 3D stereophotogrammetry facial analysis of Angle I subjects: gender comparison

*Análise facial de sujeitos Classe I de Angle por meio da estereofotogrametria 3D: comparação entre gêneros*

Ana Maria Bettoni Rodrigues da SILVA<sup>a\*</sup>, Laís Valencise MAGRI<sup>a</sup>,  
Álvaro Augusto JUNQUEIRA JÚNIOR<sup>a</sup>, Marco Antônio Moreira Rodrigues da SILVA<sup>a</sup>

<sup>a</sup>Faculdade de Odontologia, USP - Universidade de São Paulo, Ribeirão Preto, SP, Brasil

### Resumo

**Objetivo:** O objetivo deste estudo foi estabelecer parâmetros de referência para análise facial de tecido mole de sujeitos Classe I de Angle por meio da técnica de estereofotogrametria 3D, comparando-se homens e mulheres. **Material e método:** A amostra foi composta por 26 voluntários (11 mulheres e 15 homens), com idade entre 18 e 30 anos (22±5), em oclusão de Classe I. Estes sujeitos foram submetidos a um exame odontológico para verificação do tipo de oclusão. Foram então demarcados pontos de referência na face e realizada uma tomada fotográfica por meio do aparelho Vectra (M3-Canfield®) para a obtenção de imagens tridimensionais da face. Nas imagens 3D foram mensuradas as seguintes variáveis: ângulos naso-labial (C-Sn-Ls); (N-Prn-Pg); (N-Sn-Pg); mentolabial (Li-Sl-Pg); de crescimento (T-Go-Pg), área das bochechas (T, Zy, Chk, Ch, Gn, Go), hemifaces (T, Zy, Ft, Tr, N, Prn, C, Sn, Ls, Sto, Li, Sl, Gn, Go) e dos lábios bilateralmente (Ls, Cph, Ch, Li, Sto), além de medidas lineares dos lábios e da mandíbula. **Resultado e conclusão:** Os dados foram comparados entre gêneros (T-student), sendo que não foram encontradas diferenças estatisticamente significantes entre-grupos ( $p>0,05$ ). Considerando-se as limitações deste estudo, é possível concluir que como não houve diferenças entre homens e mulheres para as variáveis estudadas (angulares, lineares e de área), sugere-se a utilização dos dados da amostra total (Classe I) como parâmetros de referência para estudos futuros. A estereofotogrametria 3D se mostrou uma nova possibilidade de análise do tecido mole facial, que poderá ser empregada em diversas áreas da Odontologia.

**Descritores:** Fotogrametria; imagem tridimensional; oclusão dentária.

### Abstract

**Objective:** The aim of this study was to establish reference parameters for facial analysis in subjects with Angle's Class I occlusion by means of stereophotogrammetry, comparing men and women. **Material and method:** Twenty-six healthy young adults with Angle's Class I occlusion volunteered to participate in the study, 15 males and 11 females, ages between 18 and 30 years old (22 years ± 5). These subjects were clinically examined to verify their type of occlusion. Twenty-five landmarks were performed in soft tissue, and those subjects underwent image capturing by the stereophotogrammetry technique, using the apparatus Vectra (M3-Canfield®). The following variables were measured in those images: naso-labial angle (C-Sn-Ls); (N-Prn-Pg); (N-Sn-Pg); mentolabial (Li-Ps-Pg); growth angle (T-Go-Pg), cheek area (T, Zy, Chk, Ch, Gn, Go), hemifaces' areas (T, Zy, Ft, Tr, N, Prn, C, Sn, Ls, Sto, Li Ps, Gn, Go), lip area, bilaterally (Ls, Cph, Ch, Li, Sto), and linear measurements of the lips and jaw. **Result and conclusion:** The data were compared between genders (Student's t-test), and no statistically significant differences between groups ( $p>0.05$ ) were found. Despite the limitations of this study, it is possible to conclude that, as there were no differences between men and women for the studied variables (angular, linear, and area), the data of the total sample (Class I) should be used as reference parameters in future studies. Additionally, the 3D stereophotogrammetry technique has proven to be a new possibility for facial analysis, which might be employed in several areas of dentistry.

**Descriptors:** Photogrammetry; imaging three-dimensional; dental occlusion.

### INTRODUCTION

Facial analysis is essential for the diagnosis and treatment planning of different dental procedures, such as for example, orthognathic surgery and visualization of craniofacial

malformations. The development of techniques that seek to ensure this type of analysis has been proposed, among them the one that stands out the most is the 3D stereophotogrammetry<sup>1</sup>. This

technique consists of a rapid method for acquisition of images in a non-invasive and safe manner, reducing the need for exposure to radiation. Image acquisition is performed by cameras positioned at different angles, and a software produces a three-dimensional digital image of the individual's face. These images precisely represent the soft tissues of the face, since it is not necessary that there is contact with the skin's surface. This technique can be widely used both in the dental area, as well as in the medical field for the diagnosis, planning and comparison of the results obtained<sup>2,3</sup>.

The 3D image acquisition system and facial sculptor Vectra M3 (Canfield Scientific, Fairfield, NJ) consists of two capsules including three cameras (one color and two black and white) and a projector in each capsule. The system captures images in two dimensions of the individual's face and reconstructs them three-dimensionally. These 3D images can be processed, analyzed, manipulated and measures<sup>4,5</sup>. The possibility of handling the 3D image in different directions (front, side, inferior-superior, superior-inferior) allows several types of analysis of soft tissue are performed, among them we can highlight the measurement of linear distances, angles and areas. Furthermore, it is possible to superimpose these images before and after treatment, for example, orthognathic surgery, which also allows the patient to view these results<sup>5</sup>.

Knowledge of the occlusion is of paramount importance for many areas in Dentistry, among which stand out the oral rehabilitation, restorative dentistry, orthodontics and functional orthopedics of the jaws. The majority of the analyses that are carried out for plans dental interventions are based on images of hard tissues (x-rays, computed tomography, cephalometries). However, it is important to point out also the importance of evaluating the soft tissue, because this represents the facial appearance of each individual.

Therefore, the objective of this study was to establish reference parameters for the analysis of facial soft tissue of subjects Class I Angle by means of the 3D stereophotogrammetry technique (Vectra M3 - Liphook, United Kingdom<sup>®</sup>), comparing men and women.

## MATERIAL AND METHOD

### Study Design

This was a cross-sectional observational study.

### Research Participants

A group of 26 healthy volunteers (11 women and 15 men, were recruited for this study. Their ages ranged between 18 and 30 years (22 years  $\pm$  5). Inclusion criteria were: occlusion in Angle Class I and presence of at least 26 teeth in the mouth. We excluded individuals who had missing teeth, patients with central or peripheral neurological disorders, or who have suffered tumors, trauma in the region of head / neck and orthognathic or plastic surgery. Patients were also excluded who were undergoing orthodontic treatment, users of partial or full dentures, and subjects

with presence of accentuated horizontal and/or vertical overlaps and maxilla-mandibular discrepancies.

All participants were informed about the ethical aspects related to this research and were asked to sign the Informed Consent. This study was approved by the Research Ethics Committee of School of Dentistry of Ribeirão Preto (FORP/USP), according the protocol 08874612.3.0000.5419.

### Procedures Performed

The research participants were submitted to clinical dental care performed by a dental surgeon trained and calibrated, with the objective to evaluate the occlusal conditions and the verification of the existence of the Class I Angle. Initially, a band was positioned on the participant's head with the purpose to secure their hair and ensure better visualization of the face. The skin was cleaned with sterile gauze soaked in 70% alcohol, in order to remove any impurities, oiliness and makeup. Reference Points were marked on the facial surface of the participants using black eyeliner (Boticário<sup>®</sup>), previously established by Ferrario et al.<sup>6</sup> and Sforza et al.<sup>1</sup>.

- Reference Points of the middle line: Tr, Trichion; N, Nasion; Prn, Pronasale; C, Columela; Sn, Subnasale; Ls, Labiale Superius; Sto, Stomion; Li, Labiale Inferius; Sl, Sublabiale; Gn, Gnation; Pg, Pogonion (Figure 1).
- Bilateral reference points (right and left): Ft<sub>r</sub> and Ft<sub>p</sub>, Frontotemporale; Cph<sub>r</sub> and Cph<sub>p</sub>, Crista Philtri; Ch<sub>r</sub> and Ch<sub>p</sub>, Cheilion; T<sub>r</sub> and T<sub>p</sub>, Tragus; Go<sub>r</sub> and Go<sub>p</sub>, Gonion; Zy<sub>r</sub> and Zy<sub>p</sub>, Zygion; Chk<sub>r</sub> and Chk<sub>p</sub>, Cheek (Figure 1).

In the 3D image the cheek areas were measured bilaterally in cm<sup>2</sup>, between the points T, Zy, Chk, Ch, Ng, Go. The lip areas bilaterally (Ls, Cph, Ch, Li Sto), three distances above the lip (Ls-Cph and Cph-Ch); sum between these two distances), distance of lower lip (Li-Ch), distance from the lip midline (Ls-Li). The right and left areas between the points T, Zy, Ft, Tr, N, Prn, C, Sn, Ls, Sto, Li Sl, Gn, Go. In addition to two linear measurements of the mandible bilaterally (Go-T and Gn-Go). The following angles were also verified: naso-labial (C-Sb-Ls), angle of convexity of the facial soft tissue profile with nose (N-Prn-Pg), convexity angle of facial soft tissue profile without nose (N-Sn-Pg), mentolabial angle (Li-Ps-Pg), growth angle (T-Go-Pg) (Figure 2).

The data obtained were analyzed by means of descriptive statistics, in order to establish average and standard deviation of linear distances, angles and areas, the Students T Test was also employed for comparison between genders, after checking the normality of the data, in which a 5% level of significance (Bioestat 5.0).

## RESULT

The values of the mean and standard deviation for each variable evaluated are distributed in Tables 1, 2, 3 and 4, and Table 1 shows the angles T-Go-Pg, C-sn, N-Prn-Pg, N-Sn-Pg and Li-Sl-Pg, Table 2 shows the values of the areas of the cheeks, facial hemispheres and lips, in Table 3 the values for the lips (upper and lower distances and distance from the lip midline) and in Table 4

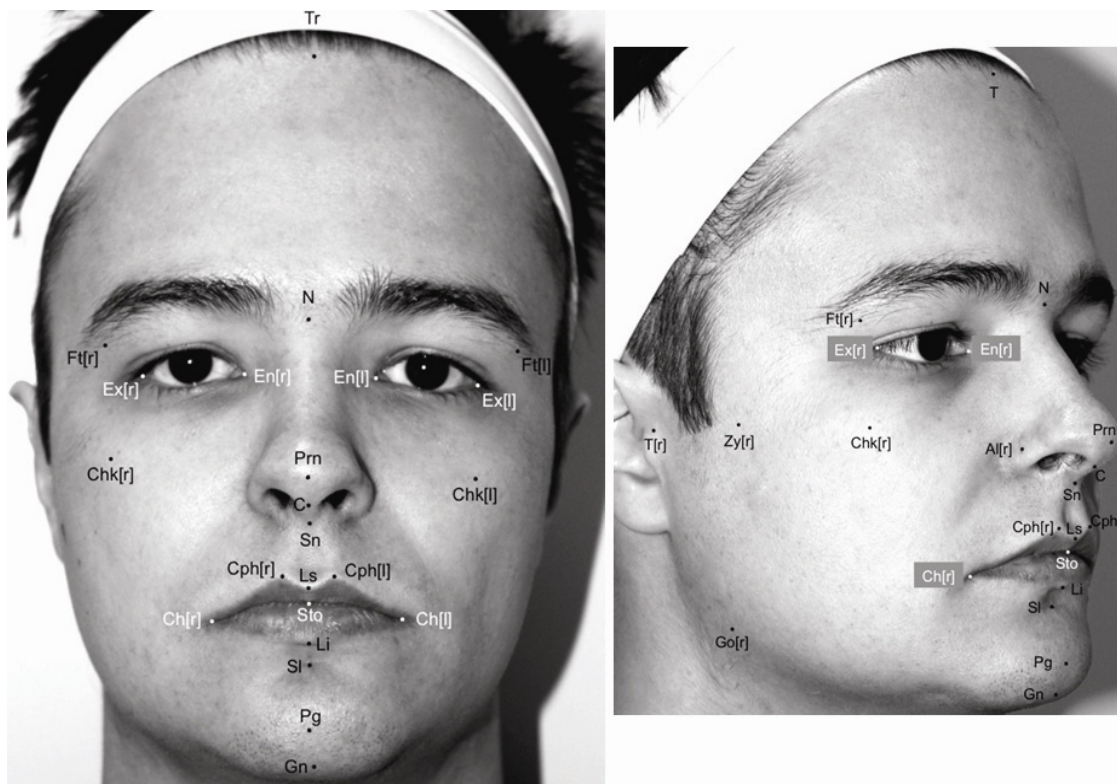


Figure 1. Reference Points marked facial in the midline and bilaterally in the face prior to the acquisition of three-dimensional images.

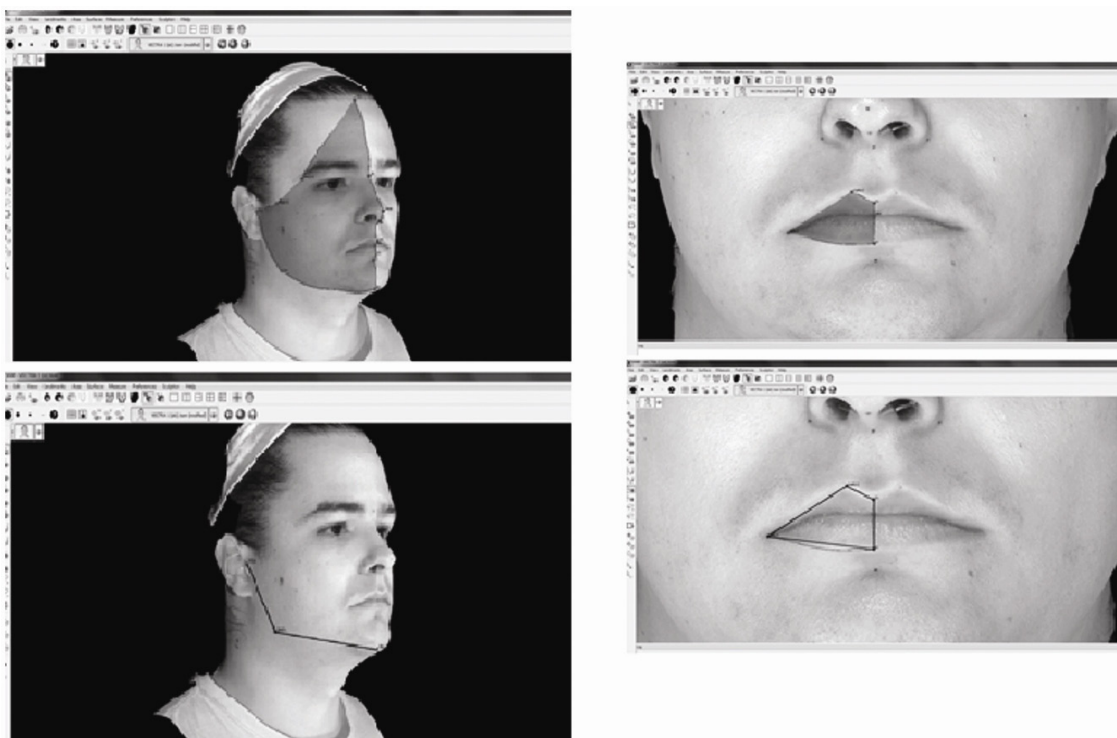


Figure 2. Marking of the hemiface area, growth angle T-Go-Pg, the lip area and linear distances of the lips for viewing of the Vectra®- 3D dimensional image processing software.

the values of linear measurements of the mandible. It is important to point out that for all variables were considered each gender and the total sample (Class I).

Regarding the analyzed angles, the biggest difference observed between the mean values in the comparison between genders was for the convexity angle of facial soft tissue profile without the nose (N-Sn-Pg), for which men achieved an average of 161.9 (± 3.8)

and 166 women (± 4.0), although not statistically significant. For the other values of angles was found great proximity between men and women, being that no statistically significant differences were obtained in the comparison between genders for any variable (p>0.05) (Table 1).

Considering Table 2, it is possible to check that there was no statistically significant difference between men and women in the

**Table 1.** Mean and standard deviation of angles T- Go-Pg (growth), C- Sb-Ls (nasolabial), N- Prn-Pg (convexity of soft profile facial with nose), N- Sn-Pg (convexity of soft profile face without nose) and Li-SI -Pg (mentolabial) for both genders and total sample (Class I)

	T-Go-Pg	C-Sn-Ls	N-Prn-Pg	N-Sn-Pg	Li-SI-Pg
Men	121.6 (±5.5)	117.5 (±5.1)	129.1 (±3.8)	161.9 (±3.8)	131.5 (±9.7)
Women	122 (±5.2)	116.5 (±7.5)	134.0 (±5.1)	166 (±4.0)	128.3 (±9.9)
Class I	121.8 (±5.3)	117 (±6.3)	131.5 (±4.4)	163.9 (±3.9)	129.9 (±9.8)
*p	0.92	0.78	0.54	0.23	0.36

\* T-Student test, comparison between genres, adopting a 5% significance level.

**Table 2.** Mean and standard deviation of the areas of the cheeks, lips and hemifaces for both sides of the face (D for right and E for the left), considering men, women and total sample (Class I), measured in cm<sup>3</sup>

	Cheek D	Cheek E	Hemiface D	Hemiface E	Lip D	Lip E
Men	74.75 (± 8.1)	72.4 (± 7.3)	171.5 (± 13.2)	168.75 (± 11.6)	3.8 (±0.95)	3.75 (±1.1)
Women	64.45 (±8.1)	61.18 (± 4.1)	153.09 (± 9.3)	150.27 (± 7.8)	2.9 (±0.7)	3 (±0.7)
Class I	69.6 (± 8.1)	66.79 (± 6.2)	165 (± 10,2)	159,30 (± 8,3)	3.4 (±0.8)	3.3 (±0.8)
*p	0.09	0.08	0.98	0.65	0.31	0.19

\* Students T Test, comparison between genders, adopting a 5% significance level.

**Table 3.** Mean and standard deviation of the variables related to his lips: upper right distance, distance upper left, lower right distance, left smaller distance and distance from the lip midline (LML), considering both genders and the total sample (Class I)

	Superior D			Superior E			Inferior D	Inferior E	LML
	Ls-Cph	Cph-Ch	Sum	Ls-Cph	Cph-Ch	Sum	Ch-Li	Ch-Li	Ls-Li
Men	6.7(±1.2)	28.35(±2.4)	35.8(±3)	6.6(±1.1)	28.2(±2.1)	35.4(±2.5)	30.55(±2.9)	30.4(±2.8)	17.3(±3.3)
Women	5.45(±0.9)	27.36(±1.9)	33(±2)	5.45(±0.8)	26.9(±1.9)	32.89(±2)	29.1(±1.8)	28.81(±1.4)	16.27(±2.9)
Class I	6(±1)	27.85(±2.1)	34.4(±2.4)	6.02(±0.9)	27.55(±2)	34.14(±2.2)	29.82(±2.4)	29.60(±2.2)	16.7(±3.1)

**Table 4.** Mean and standard deviation of the variables concerning the linear distances of the mandible: Go-Gn, Go-T and the sum of Go-Gn and Go-T (D for right-hand side and E for the left-hand side), considering both genders and the total sample

	Go-Gn (D)	Go-T (D)	Sum	Go-Gn (E)	Go-T (E)	Sum
Men	100.9 (± 5.7)	66.22 (± 5.4)	167.89 (± 7.7)	99.85 (± 5.5)	66 (± 4.8)	166.74 (± 6.9)
Women	97 (± 5.1)	53.45 (± 5)	150.81 (±6.8)	94.9 (± 3.4)	54.18 (± 4.7)	149.54 (± 5.3)
Class I	98.95 (± 5.4)	60.33 (± 5.2)	159.35 (± 7.3)	97.37 (± 4.6)	60.9 (± 4.7)	158.14 (± 6.3)

areas of cheek and facial hemispheres. For the right hemiface, the p value was 0.98 and for the left hemiface was 0.65. While for the right cheek area of the p value was 0.09 and the left cheek was 0.08. As for the lip area, the p value for the right side was 0.31 and 0.19 for the left side.

Tables 3 and 4 contain data concerning the descriptive statistical analysis of the data of lips and linear measurements of the mandible (mean and standard deviation) for men, women, and total sample (Class I). The measures relating to the lips were considered: distance top right, distance top left, distance bottom right, distance bottom left and away from the lip midline and measures concerning the linear distances of the mandible are Go-Gn, Go-T and sum of Go-Gn and Go-T.

## DISCUSSION

The scientific and technological advances, techniques such as laser scanning, MRI, ultrasound, scan for contact and stereophotogrammetry offer significant changes in the diagnostic process, because they are considered non-invasive methods of facial analysis<sup>5,7,8</sup>.

The data previously analog have gone digital, and opened up the possibility of fast acquisition, accurate and without radiation, with its information while being archived for future analyzes, moreover can be shared easily with patients and other professionals<sup>2,5,9-11</sup>. Stereophotogrammetry is a conservative method for individuals submitted to imaging, not to issue any type of radiation<sup>12</sup>. Doctors

and dental surgeons must consider the risks and benefits to the patient in obtaining craniofacial images, current research is attempting to reduce unnecessary x-ray exposure, especially in children<sup>13</sup>.

In several clinical applications, virtual reproductions of morphology can help professionals during the diagnosis and planning of medical procedures and treatments<sup>12</sup>. The system used in this study enables the overlay of images captured from the individual with the image obtained by means of computed tomography and, thus increasing the accuracy of images and measurements. Naudi et al.<sup>14</sup> and Schendel et al.<sup>15</sup> verified this hypothesis and confirmed the great applicability of 3D imaging, as well as their superposition. This new method is promising, in that it can assist with more accuracy the planning of surgical treatments.

Metzler et al.<sup>16</sup> e Tzou et al.<sup>17</sup> compared the validity of three-dimensional stereophotogrammetry with other imaging systems, which proved to be an effective reliable and fast method. The software allows for tissue modifications to promote the planning and visualization of the possible post-operative. The same can be found in this study, being that this method does not provide any changes in soft tissues of the face, since the device does not come in contact with the face of the individual to perform the image capture, which would result in changes to the measurements. It also allows the measurement of linear distances, area, and volume and it is possible view the images from different angles.

The apparatus for facial analysis in 3D (Vectra M3) have a high cost and need for a suitable location, with space reserved specially for their installation without temporary changes. Thus, the facial analysis in 3D is still limited to laboratories of universities and research centers<sup>8,18</sup>.

The images obtained from individuals are standardized and can be saved for later evaluation of cases and form a database for future comparisons. These images allow modifications that facilitate preoperative planning, and a "vision" of post-operative patients. Thus, it allows great applicability, especially in Dentistry as in cases of orthognathic surgery<sup>14,15,19-23</sup>.

According to Brons et al.<sup>24</sup> and Metzler et al.<sup>16</sup> the speed in the pictures capture speed significantly reduces possible distortions due to the individual drive, which facilitates work done with children. There is no need for contact with the facial surface, thus prevents changes in soft tissues, which could cause errors in direct measurement<sup>2,7</sup>.

In this sense, the 3D stereophotogrammetry brings a new possibility of soft facial tissue analysis, which may be employed in the most diverse situations, thus the establishment of parameters of measures, be they angular, linear or area for subjects with normal occlusion (Class I) is important, because it will serve as a reference for other studies that use the same technology, but with different samples.

## CONCLUSION

Considering the limitations of this study, it is possible to conclude that there were no gender differences for the variables studied (angular, linear and area), it is suggested to use the data of the total sample (Class I) as benchmarks for future studies. The 3D stereophotogrammetry proved to be a new possibility of analysis of soft facial tissue, which can be used in many different areas of dentistry.

## REFERENCES

1. Sforza C, Elamin F, Tommasi DG, Dolci C, Ferrario VF. Morphometry of the soft tissues of the orbital region in Northern Sudanese persons. *Forensic Sci Int*. 2013 May;228(1-3):180.e1-11. <http://dx.doi.org/10.1016/j.forsciint.2013.02.003>. PMID:23453642
2. Wong JY, Oh AK, Ohta E, Hunt AT, Rogers GF, Mulliken JB, et al. Validity and reliability of craniofacial anthropometric measurement of 3D digital photogrammetric images. *Cleft Palate Craniofac J*. 2008 May;45(3):232-9. <http://dx.doi.org/10.1597/06-175>. PMID:18452351
3. Menezes M, Rosati R, Allievi C, Sforza C. A photographic system for the three-dimensional study of facial morphology. *Angle Orthod*. 2009 November;79(6):1070-7. <http://dx.doi.org/10.2319/111008-570>. PMID:19852596
4. Khambay B, Nairn N, Bell A, Miller J, Bowman A, Ayoub AF. Validation and reproducibility of a high-resolution three-dimensional facial imaging system. *Br J Oral Maxillofac Surg*. 2008 January;46(1):27-32. <http://dx.doi.org/10.1016/j.bjoms.2007.04.017>. PMID:17561318
5. Menezes M, Rosati R, Ferrario VF, Sforza C. Accuracy and reproducibility of a 3-dimensional stereophotogrammetric imaging system. *J Oral Maxillofac Surg*. 2010 September;68(9):2129-35. <http://dx.doi.org/10.1016/j.joms.2009.09.036>. PMID:20646812
6. Ferrario VF, Sforza C, Poggio CE, Cova M, Tartaglia G. Preliminary evaluation of an electromagnetic three-dimensional digitizer in facial anthropometry. *Cleft Palate Craniofac J*. 1998 January;35(1):9-15. [http://dx.doi.org/10.1597/1545-1569\(1998\)035<0009:PEOAE>2.3.CO;2](http://dx.doi.org/10.1597/1545-1569(1998)035<0009:PEOAE>2.3.CO;2). PMID:9482218
7. Weinberg SM, Naidoo S, Govier DP, Martin RA, Kane AA, Marazita ML. Anthropometric precision and accuracy of digital three-dimensional photogrammetry: comparing the Genex and 3dMD imaging systems with one another and with direct anthropometry. *J Craniofac Surg*. 2006 May;17(3):477-83. <http://dx.doi.org/10.1097/00001665-200605000-00015>. PMID:16770184
8. Sforza C, Laino A, D'Alessio R, Dellavia C, Grandi G, Ferrario VF. Three-dimensional facial morphometry of attractive children and normal children in the deciduous and early mixed dentition. *Angle Orthod*. 2007 November;77(6):1025-33. <http://dx.doi.org/10.2319/100206-400.1>. PMID:18004919
9. Ferrario VF, Sforza C, Miani A, Tartaglia G. Craniofacial morphometry by photographic evaluations. *Am J Orthod Dentofacial Orthop*. 1993 April;103(4):327-37. [http://dx.doi.org/10.1016/0889-5406\(93\)70013-E](http://dx.doi.org/10.1016/0889-5406(93)70013-E). PMID:8480698

10. Germec-Cakan D, Canter HI, Nur B, Arun T. Comparison of facial soft tissue measurements on three-dimensional images and models obtained with different methods. *J Craniofac Surg.* 2010 September;21(5):1393-9. <http://dx.doi.org/10.1097/SCS.0b013e3181ec6976>. PMID:20856027
11. Gor T, Kau CH, English JD, Lee RP, Borbely P. Three-dimensional comparison of facial morphology in white populations in Budapest, Hungary, and Houston, Texas. *Am J Orthod Dentofacial Orthop.* 2010 March;137(3):424-32. <http://dx.doi.org/10.1016/j.ajodo.2008.12.022>. PMID:20197183
12. Rosati R, Menezes M, Rossetti A, Sforza C, Ferrario VF. Digital dental cast placement in 3-dimensional, full-face reconstruction: a technical evaluation. *Am J Orthod Dentofacial Orthop.* 2010 July;138(1):84-8. <http://dx.doi.org/10.1016/j.ajodo.2009.10.035>. PMID:20620838
13. Sforza C, Peretta R, Grandi G, Ferronato G, Ferrario VF. Soft tissue facial planes and masticatory muscle function in skeletal Class III patients before and after orthognathic surgery treatment. *J Oral Maxillofac Surg.* 2008 April;66(4):691-8. <http://dx.doi.org/10.1016/j.joms.2007.06.645>. PMID:18355592
14. Naudi KB, Benramadan R, Brocklebank L, Ju X, Khambay B, Ayoub A. The virtual human face: superimposing the simultaneously captured 3D photorealistic skin surface of the face on the untextured skin image of the CBCT scan. *Int J Oral Maxillofac Surg.* 2013 March;42(3):393-400. <http://dx.doi.org/10.1016/j.ijom.2012.10.032>. PMID:23228692
15. Schendel SA, Jacobson R, Khalessi S. 3-dimensional facial simulation in orthognathic surgery: is it accurate? *J Oral Maxillofac Surg.* 2013 August;71(8):1406-14. <http://dx.doi.org/10.1016/j.joms.2013.02.010>. PMID:23642546
16. Metzler P, Sun Y, Zemann W, Bartella A, Lehner M, Obwegeser JA, et al. Validity of the 3D VECTRA photogrammetric surface imaging system for cranio-maxillofacial anthropometric measurements. *Oral Maxillofac Surg.* 2014 September;18(3):297-304. <http://dx.doi.org/10.1007/s10006-013-0404-7>. PMID:23559195
17. Tzou CH, Artner NM, Pona I, Hold A, Placheta E, Kropatsch WG, et al. Comparison of three-dimensional surface-imaging systems. *J Plast Reconstr Aesthet Surg.* 2014 April;67(4):489-97. <http://dx.doi.org/10.1016/j.bjps.2014.01.003>. PMID:24529695
18. Tollefson TT, Sykes JM. Computer imaging software for profile photograph analysis. *Arch Facial Plast Surg.* 2007 March-April;9(2):113-9. <http://dx.doi.org/10.1055/s-2007-979280>. PMID:17372065
19. Maal TJ, van Loon B, Plooi JM, Rangel F, Ettema AM, Borstlap WA, et al. Registration of 3-dimensional facial photographs for clinical use. *J Oral Maxillofac Surg.* 2010 October;68(10):2391-401. <http://dx.doi.org/10.1016/j.joms.2009.10.017>. PMID:20708318
20. Spanholtz TA, Leitsch S, Holzbach T, Volkmer E, Engelhardt T, Giunta RE. [3-dimensional imaging systems: first experience in planning and documentation of plastic surgery procedures]. *Handchir Mikrochir Plast Chir.* 2012 August;44(4):234-9. <http://dx.doi.org/10.1055/s-0032-1316379>. PMID:22932855.
21. Othman SA, Ahmad R, Mericant AF, Jamaludin M. Reproducibility of facial soft tissue landmarks on facial images captured on a 3D camera. *Aust Orthod J.* 2013 May;29(1):58-65. PMID:23785939.
22. Verhoeven TJ, Coppens C, Barkhuysen R, Bronkhorst EM, Merckx MA, Bergé SJ, et al. Three dimensional evaluation of facial asymmetry after mandibular reconstruction: validation of a new method using stereophotogrammetry. *Int J Oral Maxillofac Surg.* 2013 January;42(1):19-25. <http://dx.doi.org/10.1016/j.ijom.2012.05.036>. PMID:22939875
23. Frejman MW, Vargas IA, Rösing CK, Closs LQ. Dentofacial deformities are associated with lower degrees of self-esteem and higher impact on oral health-related quality of life: results from an observational study involving adults. *J Oral Maxillofac Surg.* 2013 April;71(4):763-7. <http://dx.doi.org/10.1016/j.joms.2012.08.011>. PMID:22995696
24. Brons S, van Beusichem ME, Bronkhorst EM, Draaisma J, Bergé SJ, Maal TJ, et al. Methods to quantify soft-tissue based facial growth and treatment outcomes in children: a systematic review. *PLoS ONE.* 2012; 7(8):e41898. <http://dx.doi.org/10.1371/journal.pone.0041898>. PMID:22879898

## CONFLICT OF INTEREST

---

The authors declare no conflicts of interest.

## \*CORRESPONDING AUTHOR

---

Ana Maria Bettoni Rodrigues da Silva, Departamento de Odontologia Restauradora, Faculdade de Odontologia, USP - Universidade de São Paulo, Av. do Café, s/n, Bairro Monte Alegre, 14040-904 Ribeirão Preto - SP, Brasil, e-mail: bettoniana@yahoo.com.br

Received: October 29, 2014  
Accepted: December 2, 2014