

Efficacy of passive ultrasonic irrigation in removing root filling material during endodontic retreatment

Eficácia da irrigação ultrassônica passiva na remoção de material obturador durante o retratamento endodôntico

Carina MICHELON^{a*}, Marina FRIGHETTO^a, Pauline Mastella LANG^a, Mariana De Carlo BELLO^a, Rafael PILLAR^a, Geraldo Fagundes SERPA^a, Carlos Alexandre Souza BIER^a

^aUFMS – Universidade Federal de Santa Maria, Santa Maria, RS, Brazil

Resumo

Introdução: O retratamento endodôntico requer a remoção de todos os materiais obturadores para a limpeza, o preparo e a obturação subsequentes do canal radicular. **Objetivo:** Avaliar a eficácia da Irrigação Ultrassônica Passiva (IUP) na remoção de material obturador residual após a desobturação com sistema rotatório de níquel-titânio. **Material e método:** Dezoito raízes mesiais de molar inferior com istmos foram preparadas e obturadas. A obturação foi removida com o sistema rotatório ProTaper Retratamento e limas manuais tipo K. Os espécimes foram randomizados em dois grupos ($n = 9$), ambos irrigados com NaOCl a 2,5% e EDTA a 17%. No grupo Convencional, a seringa de irrigação foi utilizada. No grupo da IUP, a técnica da IUP foi usada. As raízes foram seccionadas longitudinalmente e avaliadas em estereomicroscópio. O teste *t* de Student foi usado para comparar os grupos e o modelo linear geral foi usado para comparar os terços cervical, médio e apical dentro de cada grupo, no que diz respeito a porcentagem de material obturador residual. **Resultado:** Não houve diferença estatisticamente significativa entre os grupos, independentemente do terço do canal radicular analisado ($P > 0.05$). No grupo da IUP, o terço apical mostrou uma porcentagem significativamente mais alta de material obturador residual quando comparado aos terços cervical ($P = 0.038$) e médio ($P = 0.029$). **Conclusão:** A IUP não foi mais eficaz do que a técnica convencional na remoção de material obturador remanescente durante o retratamento endodôntico em canais radiculares com anatomia complexa.

Descritores: Irrigação; retratamento; canal radicular; ultrassom.

Abstract

Introduction: The aim of endodontic retreatment is to remove the previous root filling materials completely to allow for the subsequent steps of cleaning, canal shaping and filling replacement. **Objective:** To evaluate the efficacy of passive ultrasonic irrigation (PUI) in the removal of residual root filling material after removing the bulk of the root filling with nickel-titanium rotary instruments. **Material and method:** Eighteen mesial isthmus-containing roots of human mandibular molars were prepared and filled. The root canal filling was removed with the ProTaper Retreatment system and K-files. The specimens were randomized into 2 groups ($n = 9$), both irrigated with 2.5% NaOCl and 17% EDTA. In the conventional group, an irrigation syringe was used. In the PUI group, the PUI technique was used. The roots were sectioned longitudinally and evaluated under stereomicroscopy. Student's *t* test was used to compare groups and the general linear model was used to compare the apical, cervical, and middle root thirds within each group, in regard to the percentages of remaining residual filling material. **Result:** There was no statistically significant intergroup difference, irrespective of which root third was evaluated ($P > 0.05$). In the PUI group, the apical third showed a significantly higher percentage of residual filling material, in comparison with the cervical ($P = 0.038$) and middle ($P = 0.029$) thirds. **Conclusion:** The PUI technique was not more effective than the conventional irrigation technique in removing residual root filling material during endodontic retreatment in root canals with a complex anatomy.

Descriptors: Irrigation; retreatment; dental pulp cavity; ultrasonics.

INTRODUCTION

Endodontic post-treatment disease can occur due to the persistence of bacteria in the root canal system¹. When nonsurgical retreatment is necessary, effective removal of the filling material and

residual bacteria from the root canal system are essential to ensure a favorable outcome². However, the cleaning and disinfecting of the root canal system may be hampered by its anatomical complexity.

Irregular spaces in the canal walls, accessory canals, oval extensions, isthmuses, and apical deltas may harbor dentinal debris, necrotic tissue, or microorganisms and their by-products^{3,4}.

The anatomical complexity of the root canal system and the limitations of the techniques employed for the removal of filling material renders endodontic retreatment challenging. Several techniques have been used to remove sealer and gutta-percha, including heat-bearing instruments, stainless steel hand files, nickel-titanium (Ni-Ti) rotary instruments and ultrasonic tips, with or without the combined use of solvents⁵⁻⁸. Nevertheless, studies have shown that none of these retreatment procedures can completely clean the root canal walls⁹⁻¹¹, particularly in the apical third¹².

The literature has documented the use of ultrasound as an auxiliary tool to clean root canals through passive ultrasonic irrigation (PUI). PUI has the potential to remove dentinal debris, organic tissue, and calcium hydroxide from inaccessible root canal areas¹³⁻¹⁵. Recently, Grischke et al.¹⁶ evaluated the use of ultrasound in the removal of a root canal sealer both from the surface and from simulated irregularities of root canals. The authors found that the ultrasonic irrigation protocol was superior to the other techniques investigated in the removal of sealer from the root canal surface during endodontic retreatment. Nevertheless, few studies in the literature have reported on the efficacy of PUI in removing remaining filling material during endodontic retreatment in teeth with a complex root anatomy.

The aim of this study was to evaluate the efficacy of PUI in the removal of residual root filling material after removing the bulk of the root filling with Ni-Ti rotary instruments during endodontic retreatment in extracted human mandibular molars with curved root canals and an isthmus area.

MATERIAL AND METHOD

Tooth Selection

This study was reviewed and approved by the Ethical Committee of the Santa Maria Federal University (reference number ETIC, CAAE - 0275.0.243.000-10). Eighteen mesial roots from human mandibular molars with two canals and an isthmus, similar lengths, complete root formation, and moderate to severe curvature verified according to the Schneider method¹⁷ were selected. The presence of an isthmus was verified by cone-beam computed tomography using a PaX-Uni 3D (VATECH; Yongin, Republic of Korea) machine. The voxel size was 0.125 mm, the slice thickness was 1.5 mm, and the field of view was 8 × 5 cm. Mesial roots with intracanal obstructions, evidence of previous endodontic treatment or calcified canals were excluded.

Cleaning, Shaping and Root Canal Filling

Access was performed with 1014 and 4138 diamond burs (KG Sorensen, Cotia, SP, Brazil) under water cooling. The crowns were left intact to allow a greater amount of irrigating solution to remain in contact with the canal walls. A size 10 K-file (Dentsply Maillefer, Ballaigues, Switzerland) was inserted into the root canal until it was visible at the apical foramen. The working length (WL) was determined 1 mm short of this measurement. Canal patency was established with a size 15 K-file.

The root canals were prepared using the ProTaper Universal System (Dentsply Maillefer, Ballaigues, Switzerland) according to the manufacturer's instructions. Initially, the cervical and middle portions of the roots were prepared using the S1, SX, and S2 instruments. Afterwards, S1, S2, F1, F2, and F3 files were used, in this order, up to the WL. The instruments were driven by an electric motor (X-Smart; Dentsply Maillefer, Ballaigues, Switzerland) at a torque of 2 N.cm and a constant speed of 300 rpm. A size 30 K-file was inserted up to the WL, to ensure that the apical diameter was uniform after each preparation. The canals were irrigated with 2 mL of a 2.5% sodium hypochlorite (NaOCl) solution between each instrument change, using a syringe with a NaviTip irrigation needle (Ultradent; Munich, Germany). Then, all the root canals were irrigated by PUI with 2.5% NaOCl and 17% ethylenediaminetetraacetic acid (EDTA), and were subsequently rinsed with 2 mL of distilled water. The canals were aspirated with Capillary Tips (Ultradent; Munich, Germany), and dried using size 30 paper points (Dentsply Maillefer, Ballaigues, Switzerland). Next, the canals were filled with gutta-percha and Sealer 26 (Dentsply Maillefer, Ballaigues, Switzerland) using a cold lateral compaction technique. The coronal access cavities were sealed with a temporary filling material (Cavit; DeTrey Dentsply, Konstanz, Germany). All the teeth were stored at 100% humidity and 37 °C for a period of 30 days to allow the sealer to set completely.

Endodontic Retreatment

The filling material was removed using the ProTaper Universal Ni-Ti rotary retreatment system (Dentsply Maillefer, Ballaigues, Switzerland) according to the manufacturer's instructions. The instruments were operated with an electric motor at a torque of 4 N.cm and a constant speed of 500 rpm. D1, D2, and D3 instruments were used on the coronal, middle, and apical thirds of the canals, respectively, to remove the filling material. The D3 instrument was introduced up to the WL. No solvent was used. Retreatment was considered complete when no gutta-percha/sealer was visible on the surface of the instruments. Root canal refinement was accomplished using size 20, 25, 30, and 35 K-files to the WL. The canals were irrigated with 2 mL of 2.5% NaOCl at each instrument change.

Thereafter, the specimens were stratified by amount of remaining filling material observed in the isthmus through radiographic examination, and randomly allocated (Random Allocation Software, Microsoft, Seattle, WA, USA) into 2 groups ($n = 9$), according to the final irrigation protocol.

Conventional Group

Final irrigation was performed with 2 mL of 2.5% NaOCl using a syringe with a NaviTip irrigation needle (Ultradent; Munich, Germany) and with 17% EDTA for 3 min. Finally, each canal was irrigated with 2 mL of 2.5% NaOCl to neutralize the action of the EDTA.

PUI Group

Final irrigation was performed using PUI with a piezoelectric unit (Ultrasound Ultra Sonic, Gnatus, São Paulo, SP, Brazil) and a size 15, taper 0.02 K-file, at high power¹⁸. The file was inserted into the root canal 1 mm short of the WL¹⁴, and oscillated towards the

isthmus area¹⁹. First, 3 activations with 2.5% NaOCl were performed. Each activation was performed for 20 s, totaling 1 min per canal. The solution was replenished between activations. Then, the 17% EDTA solution was activated with ultrasound for 1 min. Finally, each canal was irrigated with 2 mL of 2.5% NaOCl to neutralize the action of the EDTA.

Analysis of Remaining Filling Material

The teeth were grooved longitudinally on the buccal and lingual surfaces with a 3216 diamond bur (KG Sorensen, Cotia, SP, Brazil), under water cooling, to facilitate vertical separation of the roots with a chisel. Each root half having the largest amount of remaining filling material was observed under a stereomicroscope (Zeiss, Gottingen, Germany). Pictures were taken with a camera under 7.5 x magnification. The areas of the canal and of the remaining filling material in the cervical, middle and apical thirds of the root canal were measured in mm², with Axiovision software (Zeiss, Gottingen, Germany). The amount of remaining filling material was expressed as a percentage of the total area of each third of the root canal. The measurements were evaluated by a single observer who was blinded to the group.

Statistical Analysis

A normal distribution of data was verified with the Kolmogorov-Smirnov test. Student's *t* test was used to compare groups in regard to the percentage of remaining filling material observed for each third. The general linear model was used to compare root canal thirds in regard to the amount of remaining filling material

within each group. The Bonferroni test was performed as the *post hoc* multiple comparison method. The level of significance was set at $\alpha = 0.05$. Statistical analysis was performed with SPSS Statistics 18 software (SPSS Inc., Chicago, IL, USA).

RESULT

All roots showed remaining filling material inside the canals and isthmus. The mean amount of remaining gutta-percha/sealer in each group is shown for each third in Table 1. The stereomicroscopic analyses demonstrated no statistically significant differences ($P > 0.05$) between the conventional group and the PUI group, irrespective of the root canal area investigated (Figure 1). In the PUI group, the apical third showed a significantly higher percentage of residual filling material, as compared with the cervical ($P = 0.038$) and middle ($P = 0.029$) thirds, whereas in the conventional group, no significant difference was found among root thirds ($P > 0.05$).

Table 1. Percentage of the remaining filling material (mean \pm SD) after the removal procedure in mesial roots of mandibular molars

	PUI Group	Conventional Group
Cervical	14.2 (\pm 19.8) ^{Aa}	17.64 (\pm 9.22) ^{Aa}
Middle	25.4824 (\pm 16.4) ^{Aa}	34.7244 (\pm 25.3) ^{Aa}
Apical	47.0711 (\pm 23.5) ^{Ab}	35.7204 (\pm 28.9) ^{Aa}

Capital letter: comparison between groups. Lowercase letters: comparison among thirds within the same group. Different letters indicate a statistically significant difference ($P < 0.05$).

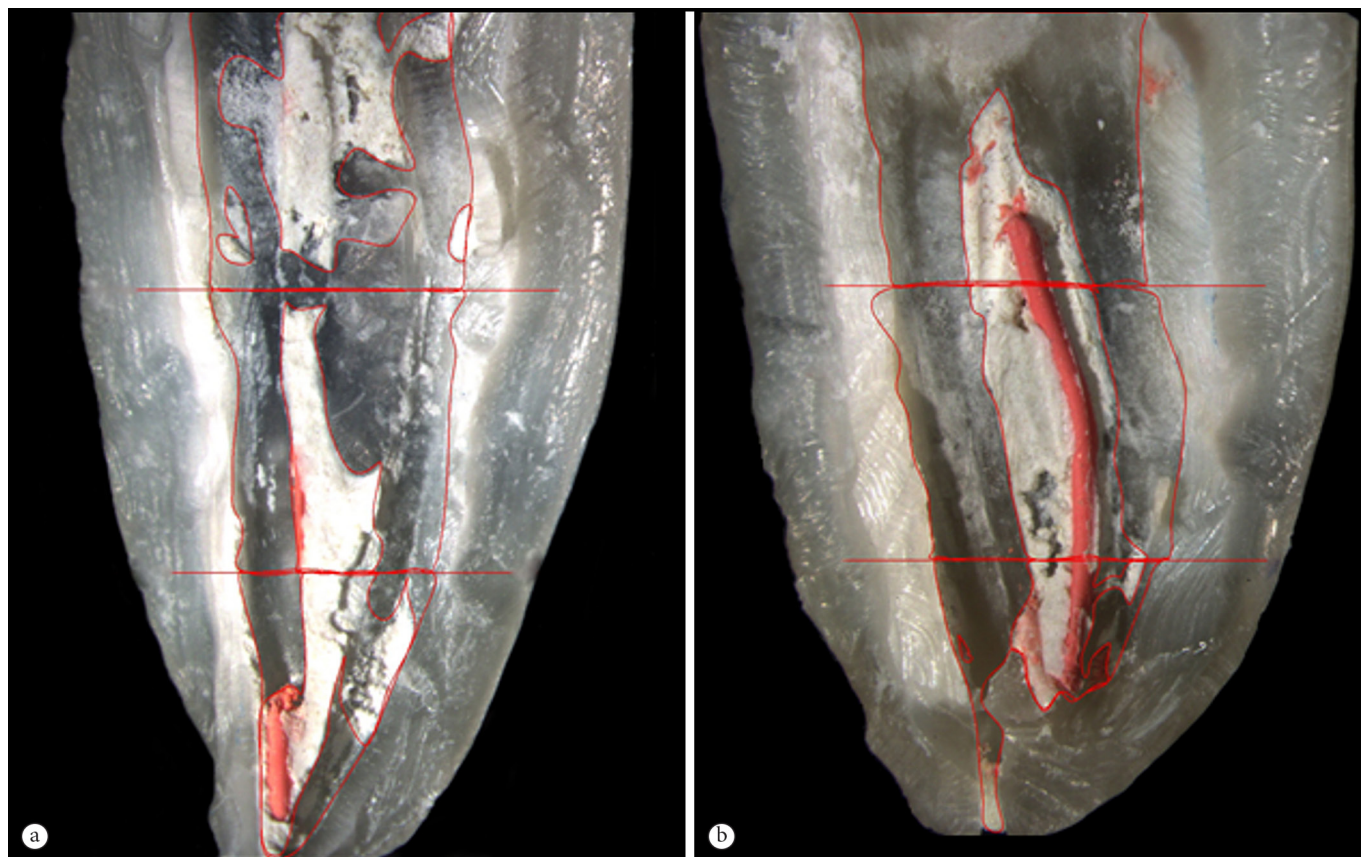


Figure 1. The images show the presence of remaining filling material in all thirds of the root canal (7.5 \times). (a) Conventional group. (b) PUI group.

DISCUSSION

Persistent periapical inflammation occurs due to the presence of residual necrotic tissues and/or bacteria within the root canal system. Therefore, the aim of non-surgical root canal retreatment is to remove pre-existing filling material from canals to allow further cleaning, bacterial elimination and root canal filling replacement¹⁵.

Several techniques have been proposed for removing root filling material, but none have shown the ability to remove gutta-percha and sealer completely from canal walls^{8,9,11}. The removal of gutta-percha by using hand instruments is a slow and difficult process, especially when the filling material is well compacted. Thus, Ni-Ti rotary instruments are recommended for reducing clinical time and facilitate removal^{9,11}. However, in this study, we observed that even after using Ni-Ti rotary instruments specifically developed for retreatment, the filling material was not completely removed from the root canal walls, corroborating the findings of other studies^{7,9-11}.

The present study tested the ability of PUI to reduce the amount of remaining filling material following root canal retreatment. It was based on the assumption that PUI is able to remove pulp tissue and dentin debris from areas of the root canal system that are untouched by endodontic instruments^{13,15}. However, according to the results, this ability of PUI did not allow a greater amount of gutta-percha and sealer to be removed, as compared with the control group. This result differs from that found by Grischke et al.¹⁶. These authors noted that the cleansing effect of PUI with NaOCl was superior to all the other irrigation techniques in removing root canal sealer. Nevertheless, the cleansing results achieved by the PUI were still not satisfactory, because, even though the root canal walls were free of sealer, the artificial grooves were still filled with sealer remnants.

Solvents can be used during retreatment to aid in the removal of gutta-percha and sealer²⁰. However, no solvent was used in the procedures employed in this study. The irrigating solution used during PUI was NaOCl, which is totally unable to dissolve gutta-percha²¹. Furthermore, recent studies have shown that solutions used to dissolve or soften the root filling material have failed to improve the effectiveness of PUI during retreatment**.

In the present study, the apical third presented the greatest amount of filling material remnants, although no significant differences were noted among thirds within the conventional group ($P > 0.05$). The combination of hand and rotary instruments with PUI was unable to improve apical cleaning ($P > 0.05$). The action of the PUI may have been reduced in the apical third because the

curvature in the root canals limited apical enlargement. During the PUI procedure, it is essential that the file move freely within the root canal, so that the solution can penetrate more easily into the root canal system, thus yielding a more powerful cleaning effect²².

Most experimental studies comparing the efficacy of different techniques for retreatment were conducted using single straight root canals^{5,8,10,11}, to simplify the standardization of specimens. Although teeth with complex anatomy represent a common clinical situation²³, investigations of non-surgical retreatment techniques for teeth with 2 curved canals and an isthmus are rare. Irregularities, isthmuses and recesses⁴ hamper filling material removal, cleaning and preparation of the root canal, by providing a refuge for microorganisms³, and thus compromising the success of endodontic retreatment. In the present study, the selection of curved mesial roots of mandibular molars with isthmuses may explain the large amount of remaining filling material, as compared with other studies in the literature¹⁰. Most remaining filling material was found in the isthmus, in canal wall irregularities and in the apical third.

Different methodologies have been used to evaluate the amount of filling material remaining after retreatment^{5,9}. In the present study, the specimens were longitudinally split, and the percentage of residual filling was calculated from images obtained under stereomicroscopy. The teeth were evaluated in the apical, middle and coronal thirds. This method has been reported as effective in determining the amount of filling residue, and in minimizing the subjectivity involved in a scale-based scoring method⁸. In addition, this method is more reliable than evaluation by radiography, because radiographic analysis provides only a 2-dimensional view, and has proven less effective than the cleavage method⁷. Recently, micro-computed tomography (micro-CT) has been used to evaluate the efficacy of different retreatment techniques²⁴. This methodology allows analysis of the root canal and remaining filling material in three dimensions without destroying the specimen. However, access to the equipment needed for this kind of evaluation is limited. Studies using micro-CT have shown that no technique used in endodontic retreatment is able to completely remove filling material from the root canal system²⁴, corroborating our findings.

The results of this study confirm the difficulty to remove residual filling material for adequate cleaning of root canals. Our findings reinforce the need for further studies to increase the success rates of endodontic retreatment.

CONCLUSION

According to the results of this study, we can conclude that none of the irrigation protocols were able to completely remove the residual root canal filling material from curved canals with an isthmus area.

**Barreto MS, Rosa RA, Santini MF, Cavenago BC, Duarte MA, Bier CA, et al. Efficacy of ultrasonic activation of NaOCl and orange oil in removing filling material from mesial canals of mandibular molars with and without isthmus. *J Appl Oral Sci.* 2015. In press. <http://dx.doi.org/10.1590/1678-775720150090>. PMID:26200525.

REFERENCES

1. Nair PN. On the causes of persistent apical periodontitis: a review. *Int Endod J.* 2006 Apr;39(4):249-81. <http://dx.doi.org/10.1111/j.1365-2591.2006.01099.x>. PMID:16584489.
2. Mounce R. Endodontic retreatment possibilities: evaluation, limitations and considerations. *Compend Contin Educ Dent.* 2004 May;25(5):364-6, 368. PMID:15181777.
3. Nair PN, Henry S, Cano V, Vera J. Microbial status of apical root canal system of human mandibular first molars with primary apical periodontitis after one visit endodontic treatment. *Oral Surg Oral Med Oral Pathol Oral Radiol Endod.* 2005 Feb;99(2):231-52. <http://dx.doi.org/10.1016/j.tripleo.2004.10.005>. PMID:15660098.
4. Ricucci D, Bergenholtz G. Bacterial status in root-filled teeth exposed to the oral environment by loss of restoration and fracture or caries: a histobacteriological study of treated cases. *Int Endod J.* 2003 Nov;36(11):787-802. <http://dx.doi.org/10.1046/j.1365-2591.2003.00721.x>. PMID:14641443.
5. Kfir A, Tsesis I, Yakirevich E, Matalon S, Abramovitz I. The efficacy of five techniques for removing root filling material: microscopic versus radiographic evaluation. *Int Endod J.* 2012 Jan;45(1):35-41. <http://dx.doi.org/10.1111/j.1365-2591.2011.01944.x>. PMID:21899565.
6. Pirani C, Pelliccioni GA, Marchionni S, Montebugnoli L, Piana G, Prati C. Effectiveness of three different retreatment techniques in canals filled with compacted gutta-percha or Thermafil: a scanning electron microscope study. *J Endod.* 2009 Oct;35(10):1433-40. <http://dx.doi.org/10.1016/j.joen.2009.06.002>. PMID:19801246.
7. Takahashi CM, Cunha RS, Martin AS, Fontana CE, Silveira CFM, Bueno CES. In vitro evaluation of the effectiveness of ProTaper Universal Rotary Retreatment System for gutta-percha removal with or without a solvent. *J Endod.* 2009 Nov;35(11):1580-3. <http://dx.doi.org/10.1016/j.joen.2009.07.015>. PMID:19840652.
8. Saad AY, Al-Hadlaq SM, Al-Katheeri NH. Efficacy of two rotary NiTi instruments in the removal of gutta-percha during root canal retreatment. *J Endod.* 2007 Jan;33(1):38-41. <http://dx.doi.org/10.1016/j.joen.2006.08.012>. PMID:17185127.
9. Giuliani V, Cocchetti R, Pagavino G. Efficacy of ProTaper Universal retreatment files in removing filling materials during root canal retreatment. *J Endod.* 2008 Nov;34(11):1381-4. <http://dx.doi.org/10.1016/j.joen.2008.08.002>. PMID:18928852.
10. Mollo A, Botti G, Principi Goldoni N, Randellini E, Paragliola R, Chazine M, et al. Efficacy of two Ni-Ti systems and hand files for removing gutta-percha from root canals. *Int Endod J.* 2012 Jan;45(1):1-6. <http://dx.doi.org/10.1111/j.1365-2591.2011.01932.x>. PMID:21848894.
11. Marfisi K, Mercade M, Plotino G, Duran-Sindreu F, Bueno R, Roig M. Efficacy of three different rotary files to remove gutta-percha and Resilon from root canals. *Int Endod J.* 2010 Nov;43(11):1022-8. <http://dx.doi.org/10.1111/j.1365-2591.2010.01758.x>. PMID:20726911.
12. Ersev H, Yilmaz B, Dinçol ME, Dağlaroğlu R. The efficacy of ProTaper Universal rotary retreatment instrumentation to remove single gutta-percha cones cemented with several endodontic sealers. *Int Endod J.* 2012 Aug;45(8):756-62. <http://dx.doi.org/10.1111/j.1365-2591.2012.02032.x>. PMID:22432937.
13. Weller RN, Brady JM, Bernier WE. Efficacy of ultrasonic cleaning. *J Endod.* 1980 Sep;6(9):740-3. [http://dx.doi.org/10.1016/S0099-2399\(80\)80185-3](http://dx.doi.org/10.1016/S0099-2399(80)80185-3). PMID:6935384.
14. Van der Sluis LW, Wu MK, Wesselink PR. The efficacy of ultrasonic irrigation to remove artificially placed dentine debris from human root canals prepared using instruments of varying taper. *Int Endod J.* 2005 Oct;38(10):764-8. <http://dx.doi.org/10.1111/j.1365-2591.2005.01018.x>. PMID:16164691.
15. Van der Sluis LW, Wu MK, Wesselink PR. A comparison between a smooth wire and a K file in removing artificially placed dentine debris from root canals in resin blocks during ultrasonic irrigation. *Int Endod J.* 2005 Sep;38(9):593-6. <http://dx.doi.org/10.1111/j.1365-2591.2005.00921.x>. PMID:16104971.
16. Grischke J, Müller-Heine A, Hülsmann M. The effect of four different irrigation systems in the removal of a root canal sealer. *Clin Oral Investig.* 2014 Sep;18(7):1845-51. <http://dx.doi.org/10.1007/s00784-013-1161-6>. PMID:24317958.
17. Schneider SW. A comparison of canal preparations in straight and curved root canals. *Oral Surg Oral Med Oral Pathol.* 1971 Aug;32(2):271-5. [http://dx.doi.org/10.1016/0030-4220\(71\)90230-1](http://dx.doi.org/10.1016/0030-4220(71)90230-1). PMID:5284110.
18. Jiang LM, Verhaagen B, Versluis M, Langedijk J, Wesselink P, van der Sluis LW. The influence of the ultrasonic intensity on the cleaning efficacy of passive ultrasonic irrigation. *J Endod.* 2011 May;37(5):688-92. <http://dx.doi.org/10.1016/j.joen.2011.02.004>. PMID:21496672.
19. Schirrmeister JF, Hermanns P, Meyer KM, Goetz F, Hellwig E. Detectability of residual Epiphany and gutta-percha after root canal retreatment using a dental operating microscope and radiographs: an ex vivo study. *Int Endod J.* 2006 Jul;39(7):558-65. <http://dx.doi.org/10.1111/j.1365-2591.2006.01126.x>. PMID:16776760.
20. Magalhães BS, Johann JE, Lund RG, Martos J, Del Pino FA. Dissolving efficacy of some organic solvents on gutta-percha. *Braz Oral Res.* 2007 Oct-Dec;21(4):303-7. <http://dx.doi.org/10.1590/S1806-83242007000400004>. PMID:18060255.
21. Topuz Ö, Sağlam BC, Sen F, Sen S, Gökağaç G, Görgül G. Effects of sodium hypochlorite on gutta-percha and Resilon cones: an atomic force microscopy and scanning electron microscopy study. *Oral Surg Oral Med Oral Pathol Oral Radiol Endod.* 2011 Oct;112(4):e21-6. <http://dx.doi.org/10.1016/j.tripleo.2011.03.002>. PMID:21856193.
22. Merino A, Estevez R, de Gregorio C, Cohenca N. The effect of different taper preparations on the ability of sonic and passive ultrasonic irrigation to reach the working length in curved canals. *Int Endod J.* 2013 May;46(5):427-33. <http://dx.doi.org/10.1111/iej.12006>. PMID:23062105.
23. Duncan HF, Bun S, Chong BSC. Non-surgical retreatment: experimental studies on the removal of root filling materials. *Int Endod.* 2010;4(2):111-126.

24. Barletta FB, Rahde NM, Limongi O, Moura AA, Zanesco C, Mazocatto G. In vitro comparative analysis of 2 mechanical techniques for removing gutta-percha during retreatment. *J Can Dent Assoc.* 2007 Feb;73(1):65. PMID:17295947.

CONFLICTS OF INTERESTS

The authors declare no conflicts of interest.

*CORRESPONDING AUTHOR

Carina Michelin, Departamento de Estomatologia, UFSM – Universidade Federal de Santa Maria, Rua Floriano Peixoto, 1184, 97015-372, Santa Maria - RS, Brasil, e-mail: carina.michelon@hotmail.com

Received: October 29, 2014

Accepted: May 4, 2015