

# Establishing the maxillary occlusal plane as a requisite for placement of an immediate implant-supported fixed prosthesis in the mandible: a case report

*Estabelecimento do plano oclusal na maxila como pré-requisito para a colocação de uma prótese fixa imediata implanto-suportada na mandíbula: relato de caso*

Milton Edson MIRANDA<sup>a</sup>, Karina Andrea OLIVIERI<sup>a</sup>

<sup>a</sup>Faculdade de Odontologia, SLMANDIC – São Leopoldo Mandic, Campinas, SP, Brasil

## Resumo

**Introdução:** Em pacientes com bruxismo, a atrição pode resultar em desgaste oclusal excessivo que excederá o mecanismo compensatório e ocorrerá uma perda de dimensão vertical de oclusão. **Objetivo:** O propósito deste artigo é mostrar a importância do restabelecimento de um adequado plano oclusal no arco não restaurado por meio de uma overlay fixa de acrílico, compatível com o tratamento protético do arco a ser reabilitado. A recuperação do plano oclusal do paciente na maxila com uma overlay de resina acrílica numa apropriada dimensão vertical de oclusão simultaneamente com uma prótese fixa na mandíbula, suportada por 5 implantes dentais é detalhada. **Conclusão:** Quando há um severo desgaste devido ao atrito dental em um dos arcos, é importante restabelecer o plano oclusal e as curvas de compensação simultaneamente com a restauração protética do arco a ser reabilitado.

**Descritores:** Relação cêntrica; implantes dentários; dimensão vertical; resina acrílica.

## Abstract

**Introduction:** In patients with Bruxism, the attrition can result in excessive occlusal wear that exceeds the compensatory mechanism and loss of occlusion vertical dimension occurs. **Objective:** The purpose of this article is to show the importance of re-establishing an adequate occlusal plane for the non treated arch by means of a fixed acrylic overlay, compatible with the prosthetic treatment of the arch to be rehabilitated. An upper maxillary fixed acrylic overlay restored the patient's occlusal plane in an appropriate vertical dimension of occlusion together with a fixed prosthesis in the mandible, supported by five dental implants. **Conclusion:** When there is severe wear due to dental attrition in one of the arches, it is important to re-establish the occlusal plane and compensation curves in conjunction with the prosthetic treatment of the arch to be rehabilitated.

**Descriptors:** Centric relation; dental implants; vertical dimension; acrylic resin.

## INTRODUCTION

Tooth loss leads to a change in the vertical dimension of occlusion and occlusal pathologies, such as bruxism also lead to this frame. If for any reason only one of the dental arches is to be rehabilitated, it is essential for the non treated arch to have an adequate occlusal plane and compensation curves compatible with those of the prosthetic treatment of the arch to be rehabilitated<sup>1</sup>. It is relatively common for patients to request rehabilitation of only one arch, although opposing arch needs to be treated as well.

Reconstructing dental arches with severe attrition is a unique restorative challenge. Tooth grinding habits, such as bruxism, can seriously compromise mastication and esthetics, and a reduction in the vertical dimension of occlusion may alter the patient's profile and initiate angular cheilitis with gradual alterations in

the musculature<sup>2</sup>. A fixed or removable transitional restoration is suggested to validate the tolerance of an increase in the vertical dimension of occlusion and the occlusal plane, which can be used in the final restoration procedure.

Dentists often find themselves in a situation where they cannot restore the maxillary and mandibular arches simultaneously, mostly for financial reasons<sup>3</sup>. However, it is possible to create an occlusal plane in an acceptable vertical dimension of occlusion by using an acrylic or metal overlay in one arch and performing a definitive treatment in the opposite arch. Most types of the overlay treatments described involve removable appliances and use metal frameworks similar to those used in removable partial dentures<sup>2-6</sup>. Nevertheless, if the dentist's treatment plan for the transitional overlay is to rebuild some of the worn teeth

with permanent crowns connected to a removable appliance, the patient would hesitate to agree to a fixed permanent restoration in the future, because of the amount already spent on the transitional overlay. Therefore, transitional overlays should be a reversible and relatively inexpensive treatment for patients with congenital or acquired anomalies, severely worn dentition and collapsed occlusion due to missing teeth<sup>6,7</sup>.

The purpose of this article is to describe a simple, effective and inexpensive method of fabricating a transitional fixed acrylic overlay in a patient with severely worn dentition to restore the occlusal plane in the maxilla prior to performing definitive treatment in the mandible with an implant supported fixed dental prosthesis.

## CASE PRESENTATION

The patient, a 75 year-old man with a class III profile and anterior crossbite, presented with severely worn dentition in the maxilla and an unsuitable removable partial denture in the mandibular arch, supported by two mobile teeth, the left canine and left first bicuspid (Figure 1). His chief complaint was the unstable removable partial denture and he asked for a solution to improve stability and function. Through a written consent authorizing the patient to consent to participation and provision of photographs.

His medical and dental histories were recorded, and a complete series of radiographs, which included computed tomography, were taken. The patient's medical history showed no contraindications to dental treatment, and he presented good general health.

On the basis of the clinical and radiographic examinations, a diagnosis of worn dentition in the maxilla with reduced vertical dimension of occlusion was made. The collapse in the mandible was due to lack of teeth, with the only remaining two presenting severe mobility. The different treatment modalities were explained to the patient. Initially, a fixed full arch rehabilitation in the maxilla and a fixed implant- supported prosthesis in the mandible were proposed to the patient. For financial reasons,

he decided to accept the definitive treatment proposed for the mandible but opted for a transitional fixed acrylic overlay for the maxilla.

Impressions were made of both arches using irreversible hydrocolloid impression material (Hydrogum, Zhermack – Badia Polesine Rovigo, Italy) and poured with type IV stone (Herostone, Vigodent – Rio de Janeiro, Brazil). The mandibular and maxillary casts were used to build up occlusal rims using # 7 wax (Duradent – Odonto Comercial Ltda – São Paulo, Brazil). Padronizar os nomes de produtos e seus fabricantes.

An acceptable vertical opening was estimated and recorded by measuring the distance between two points, one on the nose and the other on the chin along the patient's midline. The proposed vertical dimension of occlusion was recorded with softened # 7 wax. The transitional overlay was then fabricated along the established plane of occlusion and vertical dimension (Figure 2). A Co-Cr framework (Vera PDN, Albadent – San Francisco, USA) was made to reinforce the acrylic used to fabricate the transitional overlay (Ivocron, Ivoclar- – Vivadent, Bendererstrasse 2, Liechtenstein).

Surgical planning for implant placement in the mandible was based on the computerized tomography images (Figure 3). Surgery was scheduled and five dental implants, 15.0 mm long and 4.1 in diameter (Osseotite Tapered Certain, Biomet 3I Inc., Palm Beach Gardens, FL – USA) were installed. Five conical abutments (Biomet 3I Inc) were placed over the implants and the soft tissue sutured (Figure 4). The screw- retained square transfers were fixed on the abutments and united with self-curing acrylic resin (Pattern Resin LS, GC America, ALSIP- IL, USA). The impression was made with an individualized acrylic open tray using a polyether material (3M ESPE – Impregum Penta – CA, USA).

The impression was sent to the laboratory, a master cast obtained and a Co-Cr (Vera PDN, Albadent – San Francisco, USA) framework was made, which was checked intraorally for adequate fit. After this, the vertical dimension of occlusion and centric relation were recorded with softened # 7 wax, with the maxillary overlay in place. Acrylic teeth (Premium,

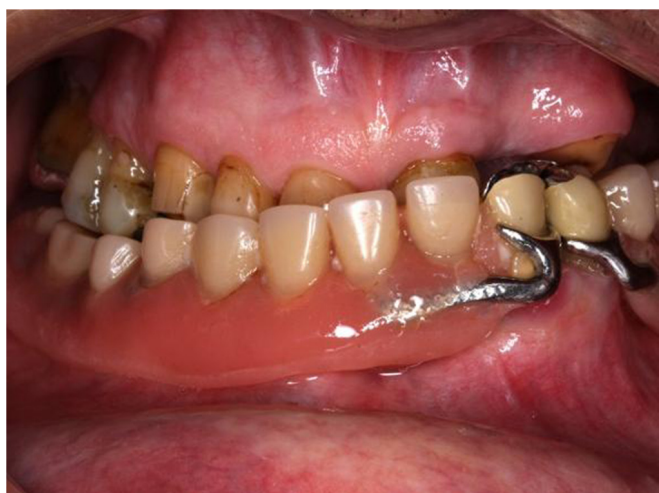

Figure 1. Frontal view–anterior crossbite.

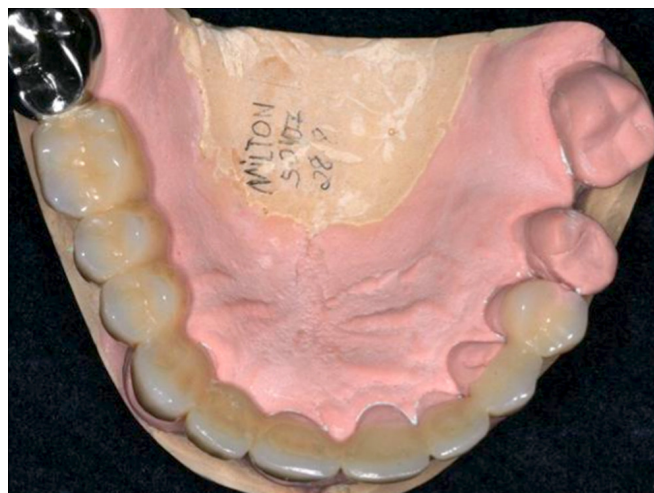
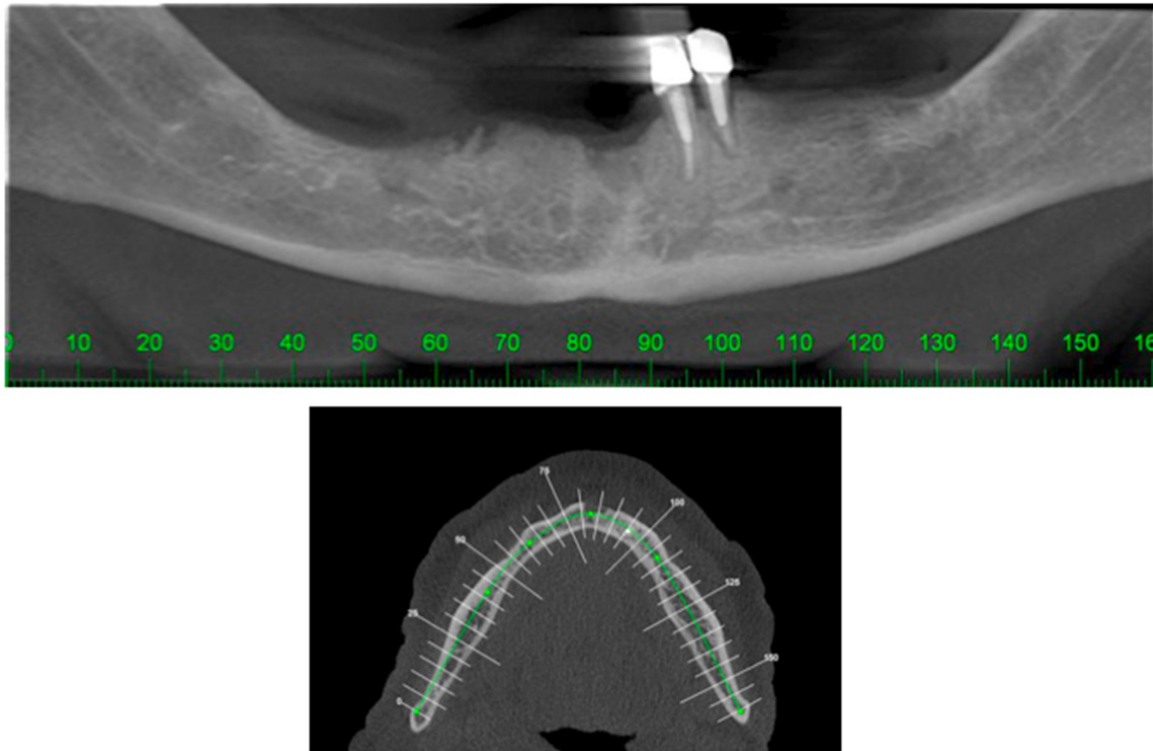
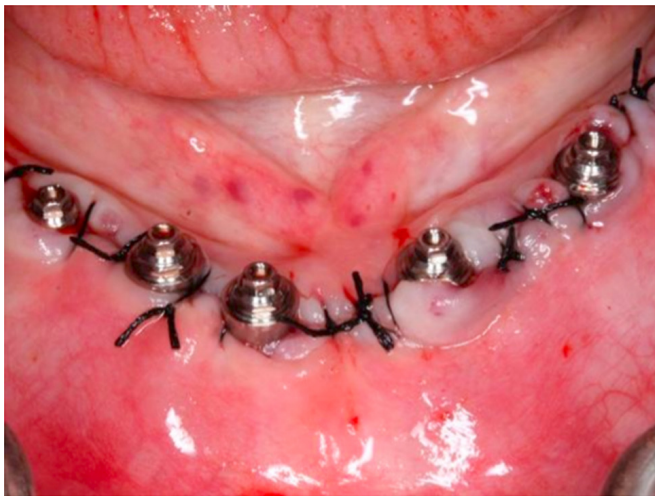


Figure 2. Transitional acrylic overlay.



**Figure 3.** CT of the mandible.



**Figure 4.** Soft tissue sutured and abutments in place.

Ivoclar – Vivadent, Bendererstrasse 2, Liechtenstein), were mounted in the mandibular arch and tried in the patient's mouth for esthetics, vertical dimension and occlusion.

After acrylization, the mandibular implant-supported fixed denture was screwed in place and the acrylic overlay cemented in the maxilla with resinous cement (Relyx U100- 3 M/ESPE, CA, USA), as shown in Figure 5.

The concluded case may be seen in Figure 6, restoring the occlusal plane, vertical dimension, esthetics and lip support.

## DISCUSSION

According to some authors<sup>8,9</sup>, loss of the vertical dimension of occlusion (VDO) caused by physiological tooth wear is usually

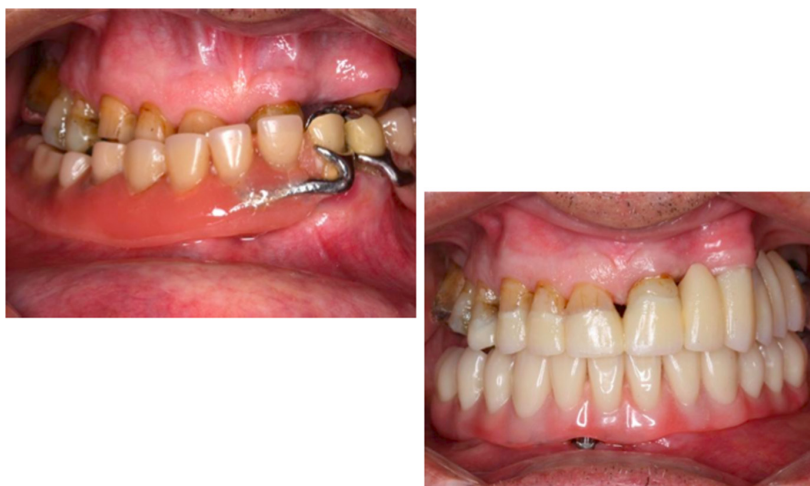compensated for by continuous tooth eruption and alveolar bone growth. However, in patients with Bruxism, the attrition can result in excessive occlusal wear that exceeds the compensatory mechanism and loss of VDO occurs. Usually, together with the worn dentition, the occlusal plane is also compromised<sup>9</sup>. The appropriate VDO and occlusal plane can be determined by several methods, such as phonetics, measuring the interocclusal distance and swallowing<sup>10,11</sup>.

Overlay removable partial dentures are frequently used to establish a proper plane of occlusion in an appropriate vertical dimension of occlusion, because they are reversible and a relatively inexpensive treatment for patients with severely worn dentition, in addition to using the existing teeth with minimal or no alterations<sup>3,4,6</sup>.

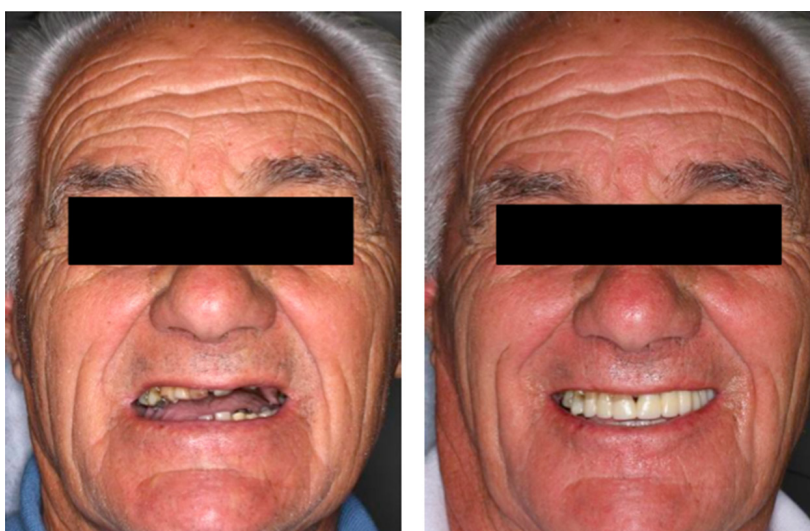Nevertheless, a removable appliance poses a number of problems and its use should be considered for a short period of time<sup>12</sup>. Some of the disadvantages are the inadequate appearance because of the metal clasps, and the butt joint made with the overlay and teeth<sup>13</sup>. A removable overlay may also retain biofilm and consequently, may cause halitosis. In addition, a removable appliance may cause a feeling of insecurity in patients. Thus, as a transitional prosthesis, a fixed acrylic overlay may be an alternative to a removable one, as presented in this clinical case.

Some patients did not want a removable partial dentures and most of the time they ask for a fixed prosthesis. A fixed implant supported restoration with occlusal plane correction, that may also improve labial support, esthetics, phonetics and oral function, are well indicated and accepted for most patients. This type of restoration can be applied also to treat the severely worn dentition.

The use of dental implants-supported fixed prosthesis offers a multitude of benefits over a tooth-soft tissue supported removable partial prosthesis<sup>14</sup>.



**Figure 5.** Before (upper) and after treatment (below).



**Figure 6.** Before (left) and after (right).

Severely worn dentition is a common problem seen in the population and rehabilitation is still a challenge for dentists. Treatment time can be lengthened during the initial trial phase of the increased VDO. This trial phase can be done by using an occlusal bite plane to allow neuromuscular adjustment to a change in VDO. In this presented clinical case it was first used a bite plane for a short period of time and then the fixed acrylic overlay was installed. According to some authors<sup>15,16</sup> a period of 6 to 8 weeks adaptation is recommended before the permanent prosthesis placed, to allow for muscle relaxation and adaptation due to the change in the VDO.

Formulation of a treatment plan for patients with severe worn dentition and inadequate occlusal plane is not simple. It requires time for muscle relaxation and for the treatment planning itself, besides a large professional expertise is crucial.

In this clinical case, the maxillary occlusal plane was established in a semi-adjustable articulator with an increase in the vertical dimension of occlusion in centric relation. The use of a provisional acrylic overlay was fundamental to organize the anterior guidance in an appropriate vertical dimension of occlusion.

In summary, the following steps are recommended:

1. A fixed acrylic overlay is made to cover the remaining and worn teeth, re-establishing the occlusal plane in an appropriate vertical dimension of occlusion;
2. After 2-3 months, when the patient has become comfortable, the teeth are prepared and a set of provisional fixed restorations are placed, using a heat-processed acrylic resin;
3. Finally, the definitive restorations are planned and developed, in a way to mimic the occlusal plane, vertical dimension, esthetics and occlusion previously developed while wearing the transitional fixed prosthesis.

## CONCLUSION

When there is severe wear due to dental attrition in one of the arches, it is important to re-establish the occlusal plane and compensation curves in conjunction with the prosthetic treatment of the arch to be rehabilitated.

The author has no financial interest in the materials listed in this article.

## REFERENCES

---

1. Fradeani M, Barducci G. Prosthetic treatment: a systematic approach to esthetic, biologic, and functional integration. Chicago: Quintessence Publishing; 2009.
2. Brown KB. Reconstruction considerations for severe dental attrition. *J Prosthet Dent.* 1980; 44: 334-88. [http://dx.doi.org/10.1016/0022-3913\(80\)90094-3](http://dx.doi.org/10.1016/0022-3913(80)90094-3)
3. Schweikert EO. Establishing a plane of occlusion with a partial overlay denture. *Quintessence of Dental Technology.* 1982; 5: 389-94.
4. Farmer JB, Conelly ME. Treatment of open occlusions with onlay and overlay removable partial dentures. *J Prosthet Dent.* 1984; 51: 300-3. [http://dx.doi.org/10.1016/0022-3913\(84\)90208-7](http://dx.doi.org/10.1016/0022-3913(84)90208-7)
5. Trushkowsky RD, Bahman G. Restoration of occlusal vertical dimension by means of a silica-coated onlay removable partial denture in conjunction with dentin bonding: a clinical report. *J Prosthet Dent.* 1991; 66: 283-6. [http://dx.doi.org/10.1016/0022-3913\(91\)90250-Z](http://dx.doi.org/10.1016/0022-3913(91)90250-Z)
6. Patel MB, Bencharit S. A treatment protocol for restoring occlusal vertical dimension using an overlay removable partial denture as an alternative to extensive fixed restoration: a clinical report. *The Open Dentistry Journal.* 2009; 3: 213-8. <http://dx.doi.org/10.2174/1874210600903010213>
7. Turner KA, Missirlian DM. Restoration of the extremely worn dentition. *J Prosthet Dent.* 1984; 52: 467-74. [http://dx.doi.org/10.1016/0022-3913\(84\)90326-3](http://dx.doi.org/10.1016/0022-3913(84)90326-3)
8. Almog DM, Ganddini MR. Maxillary and mandibular overlay removable partial dentures for restoration of worn teeth: a three-year follow-up. *NY State Dent J.* 2006; 72(3): 32-5.
9. Murphy T. Compensatory mechanism is facial height adjustment to functional tooth attrition. *Aust Dent J.* 1959;4(5): 312-23. <http://dx.doi.org/10.1111/j.1834-7819.1959.tb03727.x>
10. Lundquist DO, Luther WW. Occlusal plane determination. *J Prosthet Dent.* 1970; 23(5): 489-98. [http://dx.doi.org/10.1016/0022-3913\(70\)90198-8](http://dx.doi.org/10.1016/0022-3913(70)90198-8)
11. Sato S, Hotta TH, Pedrazi V. Removable occlusal overlay splint in the management of tooth wear: a clinical report. *J Prosthet Dent.* 2000; 83: 392-5. [http://dx.doi.org/10.1016/S0022-3913\(00\)70032-1](http://dx.doi.org/10.1016/S0022-3913(00)70032-1)
12. Watson RM. The role of removable prostheses and implants in the restoration of the worn dentition. *Eur J Prosthodont Rest Dent.* 1997; 5: 181-6.
13. Del Castilho R, Lamar Jr F, Ercoli C. Maxillary and mandibular overlay removable partial dentures for the treatment of posterior open-occlusal relationship: a clinical report. *J Prosthet Dent.* 2002; 87: 587-92. <http://dx.doi.org/10.1067/mpr.2002.125578>
14. Bozini T, Petridis H, Garafis K, Garafis P. A meta-analysis of prosthodontics complication rates of implant-supported fixed dental prostheses in edentulous patients after an observation period of at least 5 years. *Int J Oral Maxillofac Implants.* 2011 Mar/Apr; 26(2): 304-11.
15. Maló P, de Araújo Nobre M, Borges J, Almeida R. Retrievable metal ceramic implant-supported fixed prostheses with milled titanium framework all-ceramic crowns: retrospective clinical study with up to 10 years of follow up. *J Prosthodont.* 2012 Jun; 21(4): 256-64. <http://dx.doi.org/10.1111/j.1532-849X.2011.00824.x>
16. Meulen DV, Linden WV, Eeden RV. Optimal restoration of dental esthetics and function with advanced implant-supported prostheses: a clinical report. *J Prosthodont.* 2012 Jul; 21(5): 393-9. <http://dx.doi.org/10.1111/j.1532-849X.2011.00841.x>

## CONFLICTS OF INTERESTS

---

The authors declare no conflicts of interest.

## CORRESPONDING AUTHOR

---

Milton Edson Miranda  
Faculdade de Odontologia, SLMANDIC – São Leopoldo Mandic, Av. Coronel Silva Telles, 276, Apto. 12, 13024-000  
Campinas – SP, Brasil  
e-mail: memiranda@memiranda.com.br

Received: January 21, 2013

Accepted: April 26, 2013