

Thoracic actinomycosis simulating neoplastic disease in Pediatrics

Actinomicose torácica simulando doença neoplásica em Pediatria

Actinomicosis torácica simulando enfermedad neoplásica en Pediatría

Ricardo Mendes Pereira¹, Fabio Bucarechi¹, Antonia Teresinha Tresoldi²

ABSTRACT

Objective: To describe a pulmonary actinomycosis case in a pediatric patient.

Case description: A ten-year-old healthy girl was admitted with a history of chest pain for the past three months. During the last two months, she evolved with bulging of the left anterior chest wall. Physical examination showed a mass with 8.0cm diameter in the left inframamilar region, without signs of inflammation. Chest tomography showed an expansion process in the left anterior chest wall. Biopsy and culture of the material identified *Actinomyces israelii*. She was treated with crystalline penicillin and amoxicillin, leading to the disappearance of the thoracic mass.

Comments: Actinomycosis is a rare, indolent and invasive bacterial infection, and is often not considered in children as a cause of chest masses. Early diagnosis is uncommon.

Key-words: actinomycosis; *actinomyces*; tomography; child.

RESUMO

Objetivo: Descrever um caso de actinomicose pulmonar em paciente pediátrico.

Descrição do caso: Menina de dez anos, saudável, com história de dor torácica há três meses, evoluindo há dois meses com abaulamento em parede torácica anterior esquerda. Ao exame físico, apresentava massa de 8,0cm de diâmetro em região inframamilar esquerda, sem sinais flogísticos. A tomografia do tórax mostrou processo expansivo em parede torácica anterior

esquerda. Realizou-se biópsia e a cultura do material identificou *Actinomyces israelii*. Foi tratada com penicilina cristalina e amoxicilina, com desaparecimento da massa torácica.

Comentários: A actinomicose é uma doença bacteriana rara, indolente, invasiva e, frequentemente, não considerada em crianças como causa provável de massas torácicas, sendo incomum o diagnóstico precoce.

Palavras-chave: actinomicose; *actinomyces*; tomografia; criança.

RESUMEN

Objetivo: Describir un caso de actinomicosis pulmonar en paciente pediátrico.

Descripción del caso: Muchacha de diez años, saludable, con historia de dolor torácico hace tres meses, evolucionando, hace dos meses, con abombamiento en pared torácica anterior izquierda. Al examen físico, presentaba masa de 8,0 cm de diámetro en región inframamilar izquierda, sin señales flogísticas. La tomografía del tórax mostró proceso expansivo en pared torácica anterior izquierda. Se realizó biopsia y la cultura del material identificó *Actinomyces israelii*. Se trató con penicilina cristalina y amoxicilina, con desaparición de la masa torácica.

Comentarios: La actinomicosis es una enfermedad bacteriana rara, indolente, invasiva y, frecuentemente, no considerada en niños como causa probable de masas torácicas, siendo poco común el diagnóstico temprano.

Palabras clave: actinomicosis; *actinomyces*; tomografía; niño.

Instituição: Departamento de Pediatria da Faculdade de Ciências Médicas da Universidade Estadual de Campinas (Unicamp), Campinas, SP, Brasil
¹Doutor em Saúde da Criança e do Adolescente pela Unicamp; Professor Doutor da Faculdade de Ciências Médicas da Unicamp, Campinas, SP, Brasil
²Doutora em Ciências Médicas pela Unicamp; Professora-Associada da Faculdade de Ciências Médicas da Unicamp, Campinas, SP, Brasil

Endereço para correspondência:
Ricardo Mendes Pereira
Avenida Oscar Pedrosa Horta, 202 – apto 5 – Barão Geraldo
CEP 13083-510 – Campinas/SP
E-mail: ricardmp@hc.unicamp.br

Conflito de interesses: nada a declarar

Recebido em: 3/9/2011
Aprovado em: 12/12/2011

Introduction

Chest wall lesions in childhood include a wide range of pathologies; among the benign lesions, lipoma, neurofibroma, hemangioma, lymphangioma, and mesenchymal hamartoma stand out. Malignant lesions can be related to rhabdomyosarcoma and neuroblastoma. Manifestations of systemic diseases, such as leukemia, lymphoma, Langerhans

cell histiocytosis, and infections like tuberculosis and actinomycosis, may also cause chest wall lesions⁽¹⁾.

Thoracic actinomycosis is much more common in adults than in children and in male patients. Risk factors in children include dental caries, trauma, severe malnutrition, and uncontrolled diabetes mellitus^(2,3). We present the case of a ten-year old with pulmonary actinomycosis initially simulating malignant disease.

Case report

ten-year-old female patient, previously healthy, was admitted with a history of continuous chest pain during the past three months, with a mass in the left anterior chest wall. In the last two months, she sought several health services, with no diagnosis, and was initially referred to a Pediatric Oncology Center with the hypothesis of malignant disease.

Physical examination showed a mass of nearly 8.0cm of diameter in the left inframammary region, hardened and with no signs of infection, as well as absence of caries or lymph node megaly and weight and height appropriate for age and sex. Laboratory tests showed: hemoglobin of 10.1g/dL, leukocyte count of 12,350/mm³ (66% of which were polymorphonuclear, 30% lymphocytes, and 4% monocytes), platelet count of 345,000/mm³, and high C-reactive protein (10.5mg/dL). Assessment of liver and kidney functions was normal. Tuberculin test was negative, and chest radiograph revealed a homogenous opacity in the upper left hemithorax, with increase in adjacent soft tissues (Figure 1). The contrast computed tomography scan showed a soft tissue mass in the left pulmonary lobe expanding to the left anterior mediastinum and the left anterior chest wall (Figure 2).

The anatomohistologic study revealed an inflammatory process with no evidence of malignancy. Hematoxylin-eosin (HE) staining revealed sulfur granules, suggesting *Actinomyces*. Investigation for alcohol-acid resistant bacilli was negative. *Actinomyces israelii* was identified in the culture of biopsy fragments (5% sheep's blood agar for anaerobic culture, Center for Disease Control).

The patient received crystalline penicillin (200,000units/kg/day) during three weeks, followed by six months of amoxicillin (40mg/kg/day). During the first week of treatment, she showed clinical and radiograph improvement. She was followed up every two weeks until completing oral antibiotic therapy and remained asymptomatic two years after the end of the treatment.

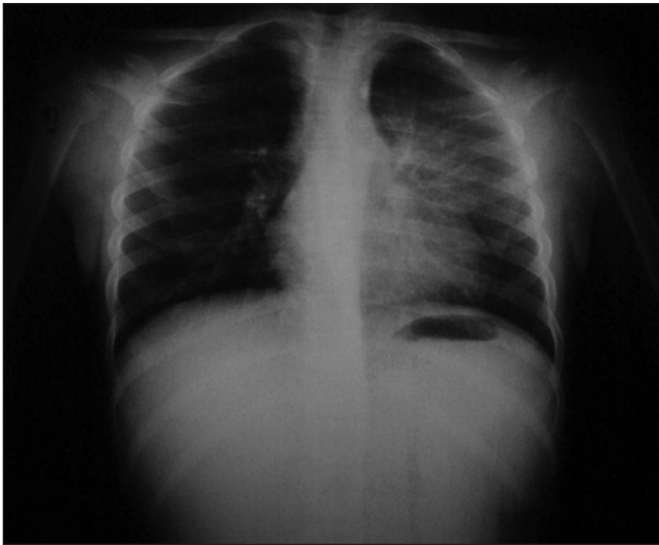


Figure 1 - Frontal chest radiograph showing a poorly defined opacity in the left hemithorax with no defined boundaries, which suggests the presence of an extrapulmonary component

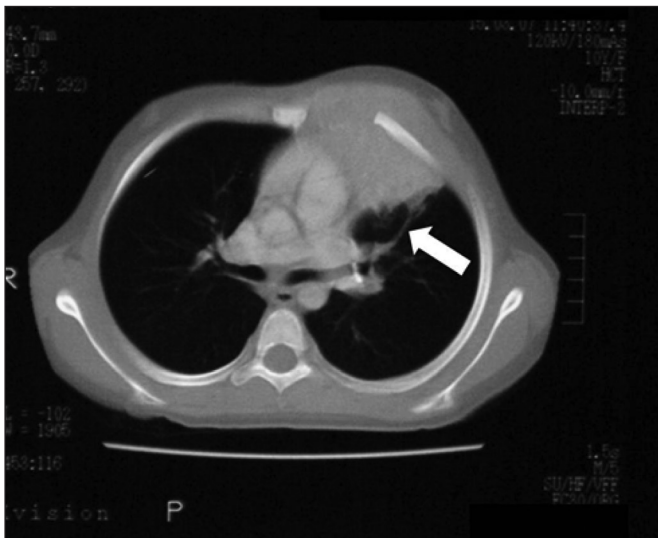


Figure 2 - Contrast computed tomography scan showing the image of a large mass of soft tissue at the left upper lobe, expanding to the anterior mediastinum and the left anterior chest wall. The eighth rib is displaced anterolaterally (arrow)

Discussion

Actinomycosis is an indolent, uncommon and invasive infection caused by several *Actinomyces* species, which are anaerobic facultative bacteria constituting the normal flora of oropharynx, intestinal tract, and female genital tract⁽²⁾. Nearly 20 *Actinomyces* species are known; however, *A. israelii* is the most frequently reported in human infections^(2,3). The most common sites involved are cervicofacial (60 to 40%), abdominopelvic (28 to 18%) and thoracic (34 to 14%) regions⁽²⁾.

Thoracic actinomycosis is a rare disease in childhood⁽³⁻⁶⁾. Bartlett *et al*⁽²⁾, in a literature review of studies conducted after computed tomography became available in 1975, identified 55 cases of thoracic actinomycosis in children and adolescents under 18 years old, mainly in boys (64%).

The most common findings in patients with thoracic actinomycosis are: chest wall mass (49%); pain (36%), generally located at the back of the elbow or at the axillary region; weight loss (35%); fever (35%); fistulas (15%); and hemoptysis (9%)^(2,3). Although some risk factors for infection have been described, such as the presence of dental caries, local trauma, foreign bodies, and uncontrolled diabetes^(2,4), their absence does not rule out the diagnosis of actinomycosis, as can be seen in the case described. Thoracic actinomycosis may be explained as a result of aspiration of *Actinomyces* and is also associated with tooth extractions.

The most frequent clinical presentation is chest wall mass, either mediastinal or pulmonary, as described in this case report. Pulmonary actinomycosis rarely presents as pneumonia, empyema or endobronchial mass⁽²⁻⁸⁾. Rib involvement is frequent, although sternum or vertebra invasion is rare^(2,4). Lower pulmonary lobes are the most affected⁽⁹⁾.

The diagnosis of actinomycosis is frequently delayed because it is not considered in the differential diagnosis for chest wall mass^(2,4); moreover, it is based on histology (sulfur granules). In the tissues, the bacteria develop into dense granules or microcolonies, called 'sulfur granules' due to its yellowish color, and may be observed on gross examination. In the series reported by Bartlett *et al*⁽²⁾, the diagnosis of actinomycosis was confirmed on histopathology in only 38% of patients.

Microorganisms of the *Actinomyces* genus are uniformly sensitive to penicillin, and the treatment is generally a combination of prolonged antibiotic therapy with surgical drainage. Despite the absence of available data to justify the optimal duration of treatment, most authors recommend that antibiotic treatment should last between six and 12 months, being administered intravenously at the beginning and then orally^(2,3,8-11). The evolution is satisfactory, rarely leading to death in children^(2,12).

The hypothesis of actinomycosis should always be considered in the differential diagnosis of chest masses, even in the absence of risk factors, which is important to guide microbiological and histological studies.

References

1. Watt AJ. Chest wall lesions. *Paediatr Respir Rev* 2002;3:328-38.
2. Bartlett AH, Rivera AL, Krishnamurthy R, Baker CJ. Thoracic actinomycosis in children: case report and review of the literature. *Pediatr Infect Dis J* 2008;27:165-9.
3. Whitworth S, Jacobs RF. Actinomycosis. In: Feigin RD, Cherry J, Demmler-Harrison GJ, Kaplan SL, editors. *Textbook of pediatric infectious diseases*. 6th ed. Philadelphia: Sanders; 2009. p. 1880-5.
4. Alborzi A, Pasyar N, Nasiri J. Actinomycosis as a neglected diagnosis of mediastinal mass. *Jpn J Infect Dis* 2006;59:52-3.
5. Goussard P, Gie R, Kling S, Beyers N. Thoracic actinomycosis mimicking primary tuberculosis. *Pediatr Infect Dis J* 1999;18:473-5.
6. Lin CH, Lin WC, Ho YJ, Chang CL, Liu FC, Lin CM. Pulmonary actinomycosis with remote lower chest wall involvement in an immunocompetent child. *Pediatr Int* 2010;52:129-31
7. Celebi S, Sevinir B, Saraydaroglu O, Gurpinar A, Hacimustafaoglu M. Pulmonary actinomycosis. *Indian J Pediatr* 2009;76:236-8.
8. Yeung VH, Wong QH, Chao NS, Leung MW, Kwok WK. Thoracic actinomycosis in an adolescent mimicking wall tumor or pulmonary tuberculosis. *Pediatr Surg Int* 2008;24:751-4.
9. Ganesan K, Khan R, Eisenhut M. Pulmonary actinomycosis masquerading as a malignant lung tumor in a 9-year-old boy. *Clin Pediatr (Phila)* 2005;44:181-3.
10. Teixeira AN, Alves CL, Martins Filho EP, Mendes EM, Nunes JT. Pulmonary actinomycosis simulating Tobias-Pancoast tumor. *Rev Soc Bras Med Trop* 2011;44:260-2.
11. Fatureto MC, Oliveira PF, Almeida CO, Fernandes LH. Lung actinomycosis with chest wall involvement. *Rev Soc Bras Med Trop* 2007;40:82-5.
12. Barikbin P, Grosser K, Hahn G, Fisher R, Suttorp M. Thoracic actinomycosis imitating a malignant chest wall tumor. Diagnosis: pulmonary actinomycosis. *J Pediatr Hematol Oncol* 2007;29:345-6.