

RELATO DE CASO

LABREA-LIKE HEPATITIS IN VITORIA, ESPIRITO SANTO STATE, BRAZIL: REPORT OF A CASE

Fausto Edmundo Lima Pereira, Carlos Musso and Elton de Almeida Lucas

A case of fulminant hepatitis with microvesicular steatosis resembling Labrea's fever, diagnosed in Vitoria (ES) is reported. The 16 year old boy presented with severe epistaxis, agitation, jaundice and hemorrhagic vomiting and died two days after admission to the emergency unit of the University Hospital. The disease started five days before with fever, myalgias, dark urine and jaundice and progressed with psychic agitation, torpor and coma. The liver and spleen were not palpable. HBsAg was negative in the serum. The autopsy showed acute hepatitis with lytic necrosis confluent in the midzonal and periportal areas with massive microvesicular steatosis in the remaining hepatocytes. Mononuclear cells predominated in the exudate. The reticulum showed condensation in the necrotic areas without typical bands of collapse. The portal tracts were edematous with mononuclear infiltration and mild bile duct proliferation. Absence of cholestasis. Except for the confluent midzonal and periportal necrosis this case showed several clinical and morphological aspects of the Labrea fever described from the East Amazon, demonstrating that the anatomical picture of this disease probably is not related to a factor peculiar to the Amazon region.

Key-words: Acute hepatitis. Labrea's fever. Viral hepatitis. Fatty liver.

Microvesicular steatosis giving a spongy or morular appearance to the hepatocytes is described as one of the main features of some kind of acute hepatitis occurring in children and young people living in East Amazon. These fulminant hepatitis has been described as Labrea's hepatitis (in Amazon region of Brazil)^{5 8 9 10}, Santa Marta's fever (in Colombia)⁷ and Amazon black fever (in French Guyana and Venezuela)^{14 20}. Cases of fulminant hepatitis in children, with clinical and morphological aspects of Labrea's hepatitis, has been described out of Amazonian region: in Salvador, Bahia (one case)¹, in Niteroi, Rio de Janeiro (five cases)^{4 19} and several cases in Bangui in the Central Africa Republic¹⁷, where this form of hepatitis has been denominated spongy hepatitis. One case of non fatal acute delta virus hepatitis with microvesicular steatosis in a young woman, was reported in the United States¹⁶.

In this communication we report a case of fulminant hepatitis in a young boy that showed lytic necrosis, focal in the centrolobular zone but that was confluent (submassive) in the midzonal and peripheric areas and with massive

microvesicular steatosis in remnant hepatocytes. The report is justified because the case resemble some aspects of Labrea's fever (and the other fulminant hepatitis in children with microvesicular steatosis described out of the Labrea region) and the knowledge of new cases of fulminant hepatitis with microvesicular steatosis could give some elements to clarify the etiology and the pathogenesis of this kind of acute hepatitis.

CASE REPORT

A 16 years old boy born in the locality of Serra (E. Santo State) was admitted to the emergency unit of the University Hospital Cassiano A Moraes. The patient had psychic agitation, episodes of hemorrhagic vomiting and severe epistaxis. The disease started five days before with fever, jaundice, myalgias, dark urine, epigastric pain and black vomiting. The patient was a marijuana addicted and a schumaker glue sniffer.

The epistaxis was controlled and the patient progressively developed coma and died in the second day after the admission.

Physical examination showed jaundice and a soft abdome with unpalpable liver and spleen.

Laboratory findings: total bilirubin 12mg %; creatin 1.4mg %; urea 35mg %; erithrocytes 3500000/mm³; band neutrophils 314/mm³; polimorphonuclear neutrophis 4980/mm³; eosinophils 410/mm³;

Departamento de Patologia do Centro Biomédico, Universidade Federal do Espírito Santo, Vitória, ES.

Address to: Dr. Fausto EL Pereira. Caixa Postal 780, 29001-970 Vitória, ES.

Recebido para publicação em 20/05/93.

monocytes 420/mm³; lymphocytes 1966/mm³; platelets 60000/mm³; prothrombin activity time 10% HBsAg non reactive (ELISA, investigated in the serum).

Autopsy observations. Liver reduced in volume and weight (950g) showing a smooth surface with a mottled appearance: diffuse irregular dark red dots on a yellowish background. The cut surface showed yellowish areas in the centrolobular region surrounded by dark red halos (Figure 1A). Microscopic examination showed preservation of the general architecture of the liver. Two main microscopic findings dominated the picture: a) confluent lytic necrosis (submassive necrosis) in the midzonal and peripheric zones of the lobules; b) focal lytic necrosis in the centrolobular areas where the hepatocytes were swollen and vacuolated with morular or spongy appearance (Figures 2A, 2B and 2C). Sudan black stained sections showed diffuse fat deposition as small droplets in all the remnant hepatocytes (microvesicular steatosis. Figures 1B, 3A and 3B). The hepatic reticulum appeared preserved in the centrolobular zone but showed diffuse thickening in the midzonal and periportal areas (Figures 4A and 4B). There was a mild inflammatory exsudate in correspondence with the areas of necrosis with predominance of lymphocytes and macrophages. Polimorphonuclear leucocytes and eosinophils were present in small number in the inflammatory exsudate. Portal spaces were edematous with mononuclear infiltration and mild bile duct proliferation. Cholestasis was absent. Partially healed *Schistosoma mansoni* granulomas were seen into the lobules.

Other autopsy findings: cerebral edema (brain weight 1400g). Severe edema of the kidneys (right kidney 160g and left kidney 150g) that showed fatty change in the proximal tubules (Figure 3C). Hemorrhagic petechiae in the visceral pleura, pericardium and kidney's capsule.

DISCUSSION

The case presented could be considered morphologically as a spongy hepatitis because the extensive microvesicular steatosis observed; on the other hand it showed some differences in respect to the spongy hepatitis described in or out of the Amazonian region because the submassive (confluent) pattern of the necrosis. In Labrea's hepatitis and in the similar forms of fulminant

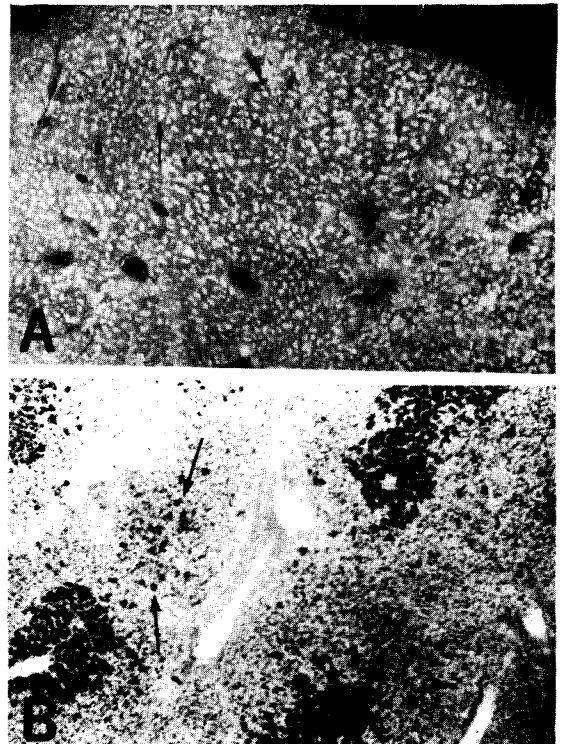


Figure 1 - A. Macroscopic aspect (view in close) of the surface of one slice of the liver: clear areas are the centrolobular zones (thin arrows) and dark areas are periportal zones (head of arrows). B. Frozen section of the liver (12 um) stained with Sudan black showing the massive steatosis in hepatocytes of the centrolobular region, corresponding the clear areas in figure A; confluent necrosis in midzonal and periportal zones (dark areas in figure A). some remnants hepatocytes in the midzonal and periportal zones are stained for lipids (arrows). Oc 10x; Obj 4x.

hepatitis described out of the Amazonian region the lytic necrosis is multifocal non confluent. According to Andrade et al³, although the microvesicular steatosis is an important morphological manifestation of the Labrea's hepatitis, the main feature of the disease is lytic, multifocal necrosis without collapse of the reticulum; the colestasis is infrequent, the bile duct proliferation is mild or absent and the portal spaces are edematous with mononuclear inflammatory exsudate. As we can see

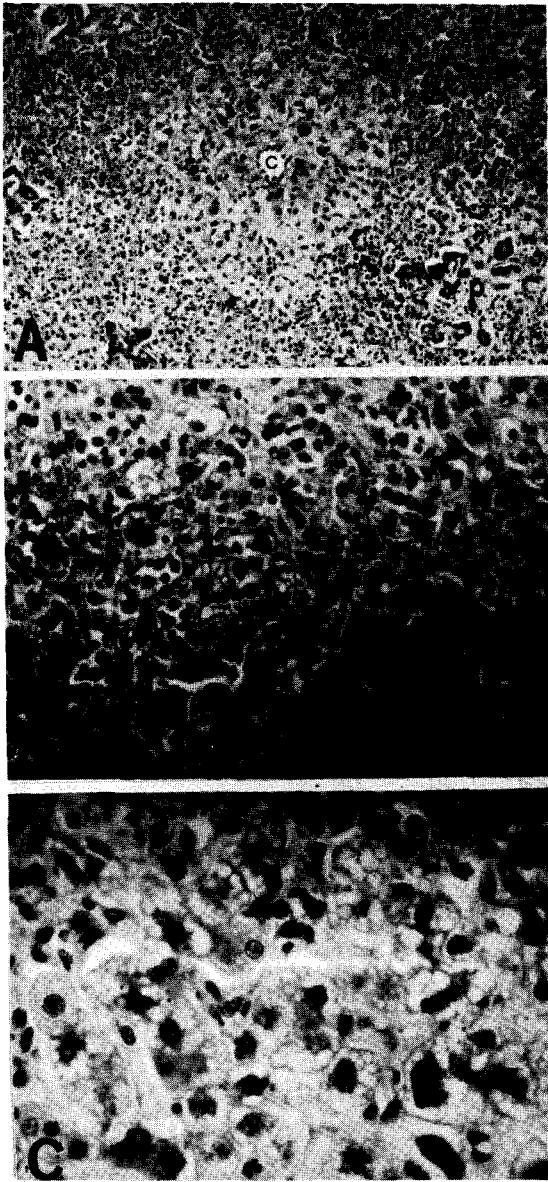


Figure 2 - Paraffin sections of the liver stained with hematoxylin eosin. **A.** Low magnification showing the central vein (c) surrounded by preserved hepatocytes; confluent necrosis in the midzonal and periportal zones; portal spaces (P) with mild biliar proliferation. Oc 10x; Obj 10x. **B.** Centrolobular and midzonal areas (zones 2 and 3 of the hepatic acinus): swollen, microvacuolated hepatocytes and focal lytic necrosis that is confluent in midzonal area; inflammatory cells are mainly mononuclear. Oc 10x; Obj 20x. **C.** High power view of centrolobular hepatocytes: microvacuolization is evident (morular or spongyform appearance). Oc 10x; Obj 40x.

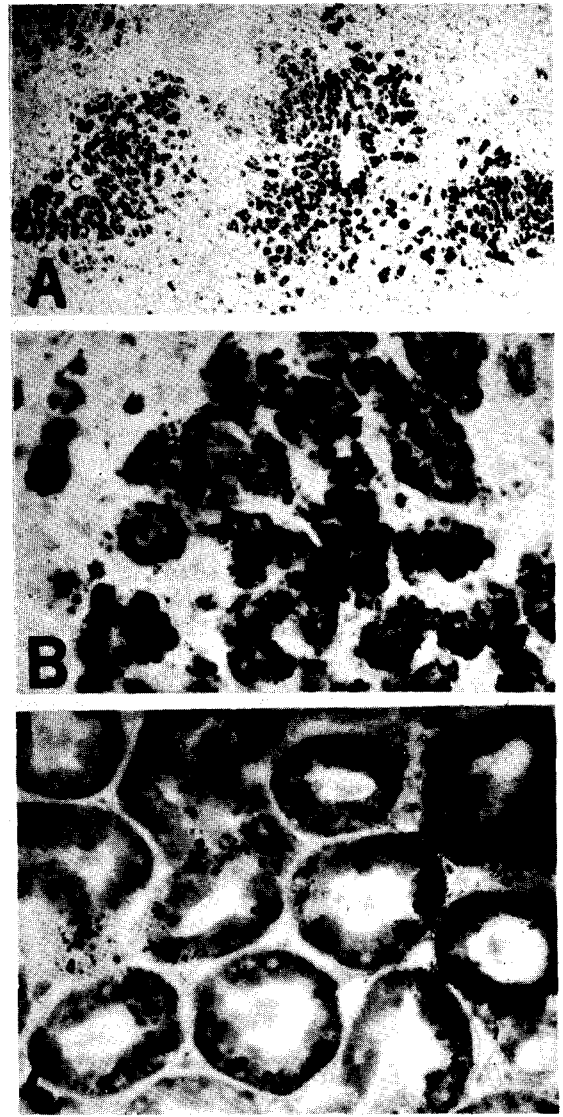


Figure 3 - **A.** Frozen sections of the liver (10µm) stained with Sudan black: massive steatosis in the centrolobular areas (c=central vein); in necrotic areas (not stained) there are hepatocytes, isolated or in small groups, loaded with lipids (stained by the Sudan black, arrows). Oc 10x; Obj 4x. **B.** High power view of a frozen section of the liver stained with Sudan black: observe the microvesicular (microglobular_ aspect of the lipid deposition; areas of lytic, multifocal necrosis, are not stained. Oc 10x; Obj 40x. **C.** Frozen section of the kidney stained with Sudan black: the proximal tubules have numerous small droplets of lipids in the cytoplasm. Oc 10x; Obj 20x.

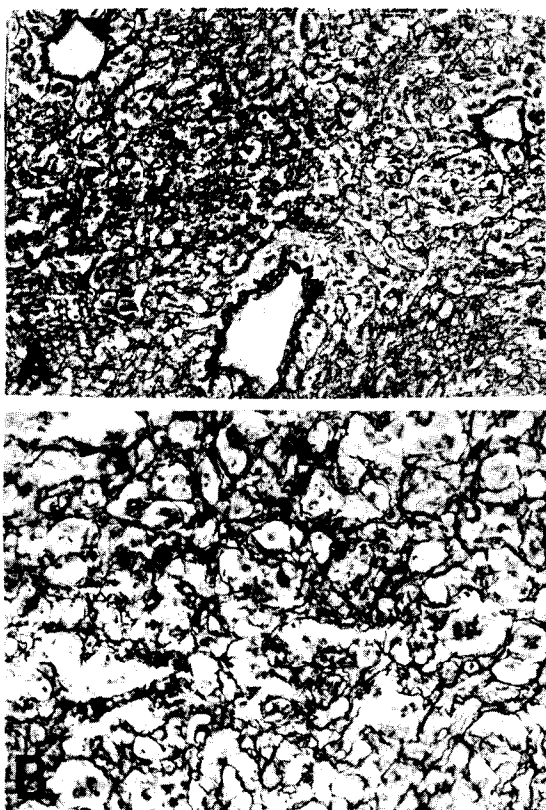


Figure 4 - Paraffin sections of the liver stained for reticulum: A. The reticulum is preserved in centrilobular area but the reticulin fibers are condensed in midzonal and periportal zones. Oc. 10x; Obj 10x. B. High power view of A showing areas of condensation of the reticulum (areas of microcolapses). Oc. 10x; Obj 40x.

by description and the documentation of the case presented, only the confluent aspect of necrosis differentiate it from the cases described as Labrea's fever (and from the similar cases described in Brazil, out of the Amazonian region). The evolution of the disease was similar to that observed in Labrea's fever: fever, myalgias, black vomiting, psychic agitation, coma and rapid evolution to death; other similar aspect was the fatty change in the proximal tubules of the kidneys also observed in autopsied cases of patients with the Labrea's fever.

The etiology of these fulminant hepatitis with microvesicular steatosis described in or out of the Amazonian region is not clear. In Amazonian and

in Bangui (Central African Republic) the infection by the virus A, B, C and D (Delta) are frequent and great number of cases studied by immunohistochemical methods showed Delta antigen in the liver sections, but there are cases in which the Delta antigen could not be demonstrated^{7 11 14 17}. In Bahia and Niteroi where some cases of fulminant hepatitis with microvesicular steatosis has been described the infection with A and B hepatitis virus are frequent but infection with Delta virus has not been demonstrated^{4 18}. In the E. Santo State infection with A and B hepatitis virus are frequent but autoctonous cases of Delta virus infection has not been reported. In the case reported here only the HBsAg was investigated and was negative.

It is possible that these fulminant spongy hepatitis are caused by the different hepatotropic viruses (A, B, C, D and others) that acquire peculiar features because the action of another factor acting simultaneously inducing specially the microvesicular fatty change. This kind of liver fatty change has been described in acute fatty liver of pregnancy²¹ and in the intoxication with tetracycline¹³ and hycanthone². Some authors admitted that it is consequence of impairment in the secretion of lipoproteins from the liver resulting in accumulation of fat in small vesicles into the cytoplasm of the hepatocytes. The patient described here was a schumaker glue sniffer and a marijuana addicted. The schumaker glue has toluen as solvent. Toluen is known as a toxic for the central nervous system but liver lesions were not seen in rats and mice submitted to acute or chronic intoxication, or in men after chronic exposition to the toxic^{6 12 15 22}. Toxic effects of marijuana on the liver are not described but are improbable.

The description of another case of fulminant hepatitis resembling Labrea's fever in the east region of Brazil confirm that the disease is not peculiar to the amazonian region, reinforcing the idea that the anatomical pictures of that disease are not specific and are not related to some peculiar factor of the Amazonian region.

RESUMO

É relatado um caso de hepatite fulminante com esteatose microvesicular semelhante à hepatite de Lábrea, diagnosticado em Vitória (E. Santo). Um adolescente de 16 anos deu entrada no Pronto Socorro do Hospital Universitário Cassiano A Moraes apresentando epistaxe grave, agitação psicomotora, icterícia e vômitos hemorrágicos, vindo a falecer dois dias depois da admissão. A doença havia iniciado cinco dias antes com febre, dores musculares, urina escura e icterícia e evoluiu com agitação psicomotora, torpor e coma. O fígado e o baço não eram palpáveis. O HBsAg foi negativo no soro. A autópsia mostrou hepatite aguda com necrose lítica, confluyente nas áreas mediozonal e periportal, com esteatose microvesicular maciça nos hepatócitos remanescentes. O exsudato era predominantemente de mononucleares e o retículo mostrava áreas de condensação nas zonas de necrose, sem faixas de colapso. Os espaços porta eram edemaciados com discreto infiltrado de mononucleares e escassa proliferação biliar. Exceto pelo aspecto confluyente (submaciço) da necrose o caso apresenta várias características clínicas e morfológicas semelhantes à hepatite de Lábrea observada na Amazônia Ocidental, servindo de argumento a favor da idéia de que o quadro anatômico dessa hepatite possivelmente não está relacionado a nenhum fator peculiar daquela região.

Palavras-chaves: Hepatite aguda. Febre de Lábrea. Hepatite viral. Esteatose hepática.

REFERENCES

1. Andrade ZA, Barbosa Jr AA. Hepatite de Lábrea em Salvador Ba? (apresentação de um possível caso). *Memórias do Instituto Oswaldo Cruz* 78:491-496, 1986.
2. Andrade ZA, Santos HA, Borojovic R, Grimaud JA. Lesões hepáticas produzidas pelo Hycanthone (Etrenol). *Revista do Instituto de Medicina Tropical de São Paulo* 16:160-170, 1974.
3. Andrade ZA, Santos JB, Prata A, Dourado H. Histopatologia da hepatite de Lábrea. *Revista da Sociedade Brasileira de Medicina Tropical* 16:31-40, 1983.
4. Bartolo MEP. Hepatite aguda grave na infância com padrão histopatológico da hepatite de Lábrea. Tese de doutorado, Universidade Federal Fluminense. Niterói, Rio de Janeiro, 1989.
5. Bensabath G, Dias LB. Hepatite de Lábrea em Sena Madureira, Acre e Boca do Acre, Amazonas, Brasil. *Revista do Instituto de Medicina Tropical de São Paulo* 25:182-194, 1983.
6. Bruckner JV, Peterson RG. Evaluation of toluene and acetone inhalant abuse: II Model development and toxicology. *Toxicology and Applied Pharmacology* 61:302-312, 1981.
7. Buitrago B, Popper H, Hadler SC, Thung SN, Gerber MA, Purcell RH, Maynard JE. Specific histologic features of Santa Marta hepatitis: a severe form of hepatitis Delta virus infection in Northern South America. *Hepatology* 6:1285-1291, 1986.
8. DePaola D, Strano AJ, Hopps HC. Labrea hepatitis (Black Fever). A problem in geographic pathology. *Bulletin of the International Academy of Pathology* 9:43-49, 1968.
9. Dias LB, Coura JR. Hepatite de Lábrea. Estudo de revisão em viscerotomias hepáticas dos anos de 1934 a 1940. *Revista do Instituto de Medicina Tropical de São Paulo* 27:242-246, 1985.
10. Dias LB, Moraes MAP. Hepatite de Labrea. *Revista do Instituto de Medicina Tropical de São Paulo* 15:86-93, 1973.
11. Fonseca JCF, Gayotto LCC, Ferreira LCL, Araujo FR, Alecrim WD, Santos RTH, Simonetti JP, Alves VA. Labrea hepatitis: hepatitis B and Delta antigen expression in liver tissue: report of three autopsy cases. *Revista do Instituto de Medicina Tropical de São Paulo* 27:224-227, 1985.
12. Gibson JE, Hardisty JF. Chronic toxicity oncogenicity bioassay of inhaled toluene in Fischer 344 rats. *Fundamentals of Applied Toxicology* 3:315-319, 1983.
13. Gombes B, Whallery PJ, Adams RH. Tetracycline and the liver. In: Popper H, Schaffner F (eds) *Progress in Liver Disease*, Grunne & Stratton, New York p.589-602, 1972.
14. Hadler SC, Monzon M, Ponzetto A, Anzola E, Rivero D, Mondolfi-Bracho A, Francis DP, Gerber MA, Thung S, Gerim J, Maynard JE, Popper H, Purcell RH. Delta virus infection and severe hepatitis. An epidemic in the Yucpa Indian of Venezuela. *Annals of Internal Medicine* 100:339-344, 1984.
15. Klassen CD. Nonmetallic environmental toxicants: air pollutants, solvent and vapors, and pesticides. In: Gilman AG, Rall TW, Nies AS, Taylor P (eds) *The Pharmacological Basis of Therapeutics*, 8th Ed, Pergamon Press, New York p.1615-1664, 1990.
16. Lefkowitz JH, Goldstein H, Yatto R, Gerber AM. Cytopathic liver injury in acute Delta virus hepatitis. *Gastroenterology* 92:1262-1263, 1987.
17. Lesbores JL, Ravisse P, Georges AJ, Beuzit Y, Ave P, Enamra D, Meunier DMY, Georges MC, Gonzales JP, Chevalier P, Pichon C, Trepo C. Le role du virus Delta dans les hepatites fulminantes en Afrique Centrale. *Annales de Medecine Interne* 136:199-201, 1987.

18. Lyra LC, Parana R, Cotrim H, Mascarenhas R, Trepo C. The hepatitis delta virus in Salvador Bahia (Northeast-Brazil): Its correlation with the population of Africa descent. *Acta Hepatologica* 1:36-38, 1991.
19. Paiva LM, Kezem J, Miyagu T, Barreto-Netto M. Esteatose microvesicular como substrato de hepatite aguda grave: provável relação com a hepatite de Lábrea. *Arquivos Brasileiros de Medicina* 57:71-74, 1983.
20. Pelletier L, Lecante A, Destombes D, Serie C. La fevre noire amazonienne en Guayane Francaise?. *Archives de l'Institute Pasteur Guayane Française et l'Inini* 21(Pub 518):79-82, 1982.
21. Ralfes DB, Ishak K. Acute fatty liver of pregnancy: a clinical pathologic study of 35 cases. *Hepatology* 5:1149-1158, 1985.
22. World Health Organization. Toluene. International Programme on Chemical Safety. *Environmental Health Criteria* 52, Geneva, 1985.