

Images in Infectious Diseases

Pneumothorax in a COVID-19 Patient Receiving Long-Term Mechanical Ventilation

Erdem Yuzuak^[1], Serdar Aslan^[1] and Ismet Mirac Cakir^[1]

[1]. Giresun University, Faculty of Medicine, Department of Radiology, Giresun, Turkey.

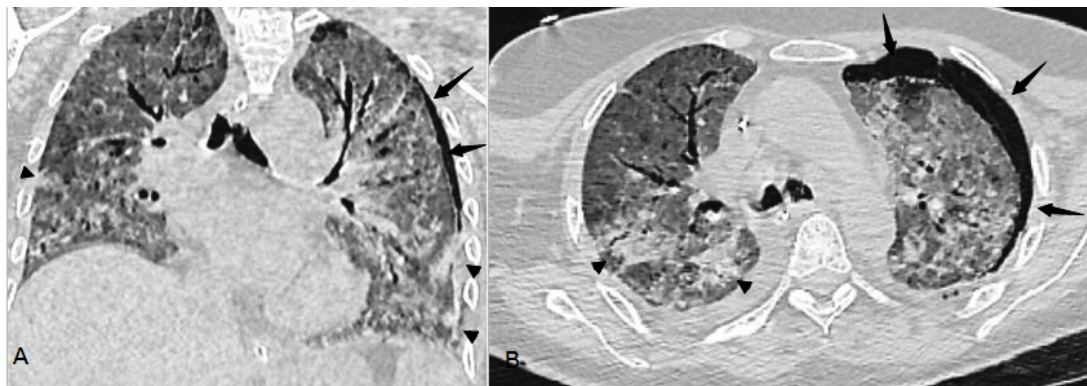


FIGURE 1: Axial and coronal unenhanced chest computed tomography. Pneumothorax (arrows), multiple ground-glass opacities and consolidations (arrowheads), in both lung fields.

A 58-year-old woman reported to the clinic while being followed up after a diagnosis of COVID-19. She was administered favipiravir, dexamethasone, moxifloxacin, and a carbapenem. On the sixth day of treatment, she was admitted to the intensive care unit and intubated due to an oxygen saturation of 80–85% with an oxygen mask and the development of dyspnea and tachypnea. She was followed up in the intensive care unit for a month while mechanical ventilation, and she had worsening respiratory acidosis and elevated airway pressure. The general condition of the patient deteriorated, and chest CT showed left pneumothorax. In addition, there were bronchial enlargements, consolidated areas, and pleural effusion accompanied by diffuse ground-glass opacity in the thoracic CT scan (**Figure 1**, arrow).

Pneumothorax and pneumomediastinum are relatively common complications in patients with extensive alveolar damage requiring mechanical ventilation¹. In lung areas exposed to high pressure

during mechanical ventilation, alveolar rupture may develop and cause pneumothorax². Cases of spontaneous pneumothorax have also been reported in patients who are not intubated with COVID-19³. According to one hypothesis, cystic and fibrotic changes in the lung parenchyma during the early stages of COVID-19 may be the cause of the predisposition to pneumothorax³.

ACKNOWLEDGMENTS

Not Applicable.

AUTHORS' CONTRIBUTION

EY: conceptualization, data curation, resources, software, supervision, validation, writing-original draft, writing-review, and editing; SA: conceptualization, visualization, validation and writing review and editing; IMC: conceptualization, visualization, validation and writing review and editing.

CONFLICT OF INTEREST


The authors declare that there is no conflict of interest.

FINANCIAL SUPPORT

The authors declare that no grants or funds were received.

Corresponding author: Dr. ErdemYuzuak.

e-mail: erdemcayli@yahoo.com

 <https://orcid.org/0000-0003-2540-8881>

Received 15 June 2021

Accepted 24 June 2021

ORCID

Erdem Yuzuak: 0000-0003-2540-8881

Serdar Aslan: 0000-0003-2950-8767

Ismet Mirac Cakir: 0000-0002-4229-7493

REFERENCES

1. Belletti A, Palumbo D, Zangrillo A, Fominskiy EV, Franchini S, Dell'Acqua A, et al. COVIDBioB Study Group. Predictors of Pneumothorax/Pneumomediastinum in Mechanically Ventilated COVID-19 Patients. *J Cardiothorac Vasc Anesth.* 2021;S1053-0770(21)00103-8.
2. Mohammadi Tofigh A, Shojaei SP, Zebarjadi Bagherpour J, Mirkheshti A, Tahmasebi H. Pneumothorax as an Ominous Side Effect in COVID-19 Patients under Mechanical Ventilation: Report of Seven Patients. *J Cell Mol Anesth.* 2020;5(3):202-5.
3. Martinelli AW, Ingle T, Newman J, Nadeem I, Jackson K, Lane ND. COVID-19 and pneumothorax: a multicentre retrospective case series. *Eur Respir J.* 2020;56(5):2002697.