

Images in Infectious Diseases

Erythema Nodosum – An atypical presentation of melioidosis

Peh Yi Tan^[1]  and Jin Yi Goh^[1] 

[1]. Hospital Sultanah Nora Ismail, Department of General Medicine, Johor, Malaysia.

A 39-year-old woman presented with fever for one month. Tender and erythematous subcutaneous nodules ranging from 3 to 6 cm in size were observed over the bilateral upper forearms, anterior thighs, and lower back region (**Figure 1 and 2**). The patient was diagnosed with type II diabetes mellitus during admission and as evidenced by 13.8% glycated hemoglobin. Blood cultures yielded *Burkholderia pseudomallei*, and melioidosis was diagnosed. A skin biopsy of the subcutaneous nodules showed dense septal panniculitis without any visible vasculitis or malignancy (**Figure 3**). No acid-fast bacilli or fungal bodies were detected using Ziehl-Neelsen or periodic acid-Schiff staining, respectively. Histological findings of the subcutaneous nodules were consistent with erythema nodosum (EN). She received intravenous ceftazidime for four weeks, followed by six months of trimethoprim-sulfamethoxazole. The EN resolved spontaneously after two months.

EN is an uncommon and under-reported cutaneous manifestation of melioidosis¹⁻². It is a delayed hypersensitivity reaction that is triggered by various etiological factors, including tuberculosis, bacterial or deep fungal infection, sarcoidosis, leprosy, drugs, pregnancy, inflammatory bowel disease, or cancer. Classically, it is located in the bilateral pretibial area, but can also spread to the thighs, arms, and neck and occurs 3–5 times more often in women. The histological picture of EN shows septal panniculitis without vasculitis³. EN treatment is directed at the causative condition. Lesions typically resolve within 2–8 weeks without scarring.

Recognizing EN as an atypical presentation of melioidosis is essential to prevent any delay in diagnosis and reduce morbidity.

ACKNOWLEDGMENTS

We express our deepest gratitude to the staff members at Hospital Sultanah Nora Ismail who were involved in the care of the patient.

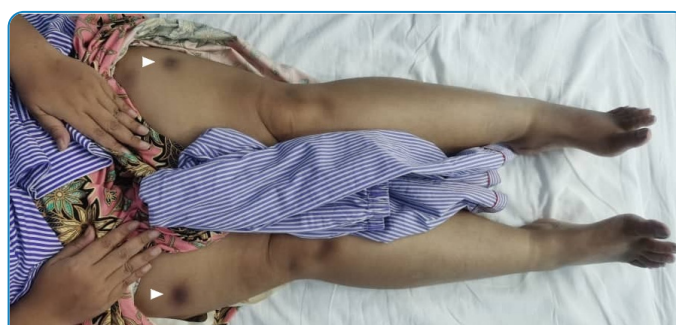

FIGURE 1: Erythema nodosum were seen on the bilateral thighs (white arrow).

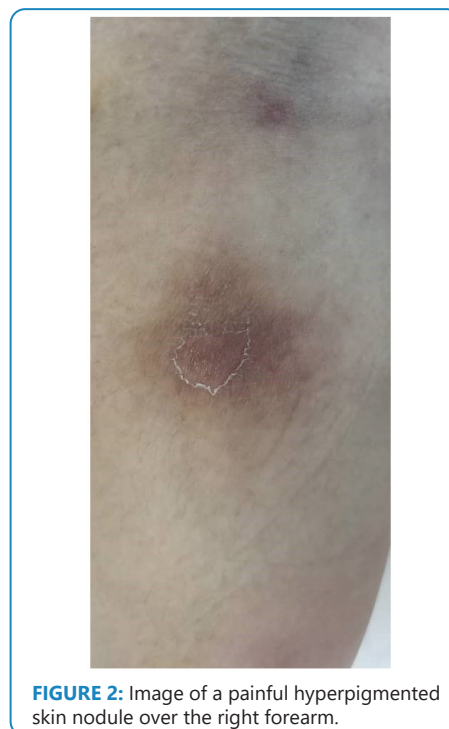

FIGURE 2: Image of a painful hyperpigmented skin nodule over the right forearm.

Corresponding author: Dr. Jin Yi Goh. e-mail: jinyigoh1988@yahoo.com

Authors' contribution: TPY: drafting the article, acquisition of data; GJY: conception and design of the study, final approval of the version to be submitted.

Conflict of Interest: The authors declare that there is no conflict of interest.

Financial Support: None.

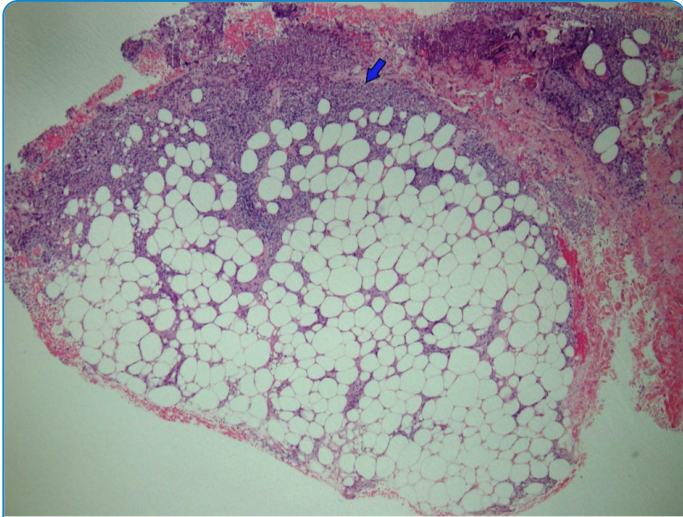


FIGURE 3: Histopathological examination of the skin biopsy specimen revealing dense septa panniculitis composed mainly of lymphohistiocytic infiltrates (blue arrow). 40X magnification.

REFERENCES

1. Diolombi M, Seneviratne M, Norton R. Case Report: Erythema Nodosum and Melioidosis: An Unreported Association. *Am J Trop Med Hyg.* 2020;103(5):1841-3.
2. Gibney KB, Cheng AC, Currie BJ. Cutaneous melioidosis in the tropical top end of Australia: a prospective study and review of the literature. *Clin Infect Dis.* 2008;47(5):603-9.
3. Blake T, Manahan M, Rodins K. Erythema nodosum - a review of an uncommon panniculitis. *Dermatol Online J.* 2014;20(4):22376.

Received 30 January 2022 | **Accepted** 16 February 2022