

Case Report

Challenging Management of Hepatitis B infection in Ankylosing Spondylitis Patients in an Endemic Area during Immunosuppressive Therapy

Gabriel Pacífico Seabra Nunes^[1], Patrícia da Silva Cunha^[2],
Daniele Patrícia Dal Bosco^[2] and Sandra Lúcia Euzébio Ribeiro^[3]

[1]. Departamento de Medicina, Universidade Nilton Lins, Manaus, AM, Brasil.

[2]. Departamento de Reumatologia, Hospital Universitário Getúlio Vargas, Manaus, AM, Brasil.

[3]. Departamento de Clínica Médica, Residência de Reumatologia, Faculdade de Medicina, Universidade Federal do Amazonas, Amazonas, Brasil.

Abstract

Hepatitis B infection is a global health issue. When considering patients with rheumatic diseases, this is no different. By using immunosuppressant drugs, such as DMARDs and biologics, viral reactivation is possible, leading to serious consequences on the patient. We report 3 cases of association between ankylosing spondylitis and hepatitis B with the use of immunosuppressant drugs. Case 1 was a patient with previous HBV infection using DMARD. Cases 2 and 3 were patients chronically infected by HBV during immunosuppressant therapy. The management of HBV infection during immunosuppressant therapy is challenging and needs multidisciplinary support.

Keywords: Hepatitis. Reactivation. Immunosuppressive therapy. Ankylosing spondylitis.

INTRODUCTION

Hepatitis B virus (HBV) infection is a global health issue and one of the major causes of liver diseases. According to the Global Hepatitis Report, 257 million people worldwide were living with HBV in 2015¹⁻⁴.

In Brazil, HBV infection is a serious public health issue. In 2016, there were around 14,199 cases of HBV infection per 100,000 inhabitants. The state of Amazonas is an endemic area, being responsible for 486 cases per 100,000 inhabitants in 2016⁵.

Disease-modifying antirheumatic drugs (DMARDs) such as methotrexate and sulfasalazine and tumor necrosis factor (TNF)- α are drugs used to treat chronic inflammatory conditions, largely used in rheumatology. Those drugs are associated with the reactivation of HBV, which is defined as an abrupt rise in viral replication⁶.

Since this is an important matter, we describe 3 cases of HBV in Ankylosing spondylitis (AS) patients in an endemic area and in use of immunosuppressive drugs.

CASE REPORT

Patient 1: A 45-year-old man from Manaus, Amazonas, Brazil. In 2000, he presented with inflammatory low back pain, calcaneal enthesitis, and recurrent uveitis. Laboratory examination revealed elevated inflammatory marker levels (erythrocyte sedimentation rate [ESR] and C-reactive protein [CRP]), negative results for rheumatoid factor and HLA-B27+. The diagnosis of AS was made fulfilling the New York Modified Criteria 1984 with bilateral grade 2 sacroiliitis on X-rays. The patient had been using sulfasalazine (SSZ) since 2013 and, in February 2016, started methotrexate. In September 2016, HBV serology revealed HBsAg- and anti-HBs+. In March 2017, the patient presented active AS (Ankylosing Spondylitis Disease Activity Score [ASDAS-ESR] = 3.34 and Bath Ankylosing Spondylitis Disease Activity Index [BASDAI] = 4); the service suggested TNF inhibitors, requesting serology for HBV that showed HBsAg- and anti-HBs+. In May 2017, he was started on Etanercept. In December 2017, laboratory results revealed a normal hemogram, normal transaminase levels,

Corresponding Author: Dra. Sandra Lúcia Euzébio Ribeiro.

e-mail: sandraler04@gmail.com

ORCID: 0000-0002-4777-8659

Received 19 September 2018

Accepted 29 November 2018

urea = 15 mg/dL, creatinine = 0.8 mg/dL, HBsAg⁻, anti-HBs⁺, and anti-HBc⁺, suggesting that the patient had had a previous resolved infection. The infectologist requested a viral load test that came negative, and suggested that the treatment should continue. The treatment continued and a follow-up of 19 months was documented with no HBV flare.

Patient 2: A 47-year-old woman from Manaus, Amazonas, Brazil. In 2004, she presented with inflammatory low back pain, calcaneal enthesitis and positive family history of Ankylosing Spondylitis. Laboratory examination revealed chronic disease anemia, high inflammatory markers (ESR and CRP), negative results for rheumatoid factor and HLA-B27⁺. The diagnosis of AS was made fulfilling the New York Modified Criteria 1984 with bilateral grade 3 sacroiliitis on X-rays. She had been using SSZ since 2013 (ASDAS-ESR = 2.9 and BASDAI = 3.9). In 2016, she came asymptomatic for consultation with the following laboratory results: normal hemogram, ALT = 55 IU/L, AST = 47 IU/L, urea = 24 mg/dL, creatinine = 0.9 mg/dL; HBV serology: HBsAg⁺, anti-HBs⁻, anti-HBc⁺, IgM anti-HBc⁻, suggesting a chronically infected patient. Viral load test yielded 4,277 copies/mL. The hepatologist decided to start entecavir 0.5 mg per day. The treatment with SSZ continued, and after 10 months, the viral load was negative. During 30 months of follow-up, no flare of HBV was documented.

Patient 3: A 52-year-old man from Manaus, Amazonas, Brazil. In 1981, he presented with inflammatory low back pain, calcaneal enthesitis, peripheral arthritis and positive family history of Ankylosing Spondylitis. Laboratory examination revealed elevated inflammatory markers (ESR and CRP), negative results for rheumatoid factor and HLA-B27. The diagnosis of AS was made fulfilling the New York Modified Criteria 1984 with bilateral grade 3 sacroiliitis on X-rays. He had been using SSZ since 2004 and in March 2016, the patient presented with active AS (ASDAS-ESR = 3.53 and BASDAI = 4.2) and was placed on TNF inhibitors. The laboratory test revealed AST = 21 IU/L, ALT = 26 IU/L, urea = 37 mg/dL, creatinine = 0.84 mg/dL, HBsAg⁺, anti-HBs⁺, anti-HBc⁺, and anti-HBe⁻. Viral load test yielded 3,478 copies/mL. The hepatologist started entecavir 0.5 mg per day. The treatment with SSZ continued, and after 9 months, the viral load test was negative. The follow-up continued and after 20 months, no flare of HBV was documented.

DISCUSSION

Management of patients bearing a rheumatologic disease with HBV infection is complex and requires attention and care of professionals from several areas. Therefore, special measures shall be taken for the early diagnosis of that association and the appropriate management (Figure 1)^{2,6-7}.

Universal screening is a major point. It is a consensus in the literature that all patients starting an immunosuppressant therapy should be tested for HBsAg, anti-HBs and anti-HBc total^{2,7-10}. That is a measure with major prophylactic impact, but those patients should not be neglected, since they may acquire an infection during treatment. Therefore, it is important to conduct an ongoing screening at least every six months to enable early diagnosis of future infections.

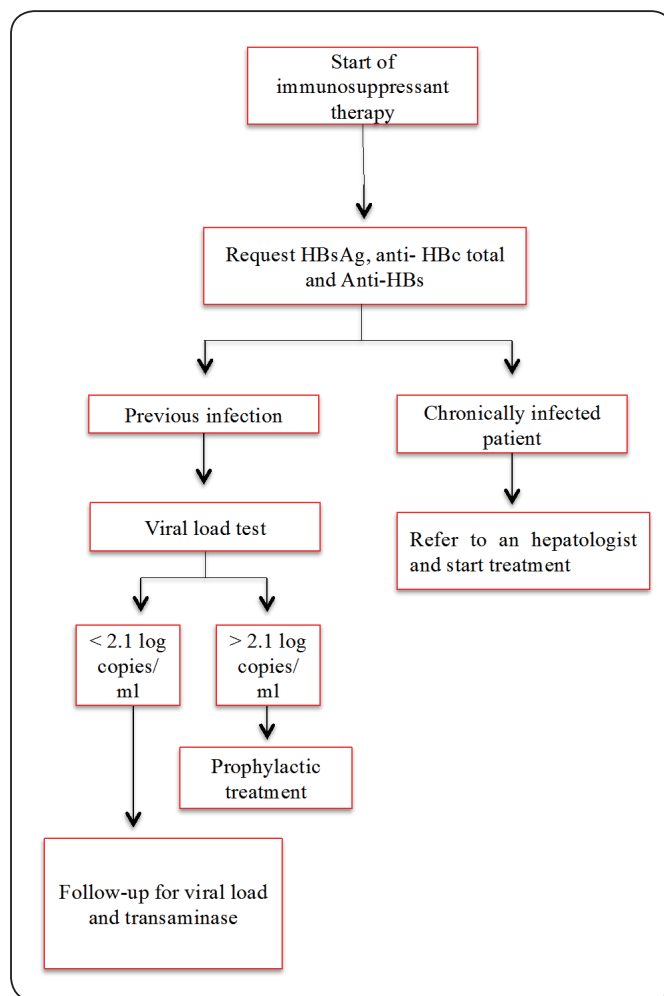


FIGURE 1: Flow chart of management of hepatitis B during immunosuppressant therapy.

Patients with previous infection serology, as in case 1, should have a viral load requested. If the result is undetectable or detectable up to 2.1 log copies/ml, follow-up for viral load and transaminase should be conducted during the entire treatment and up to 12 months after drug withdrawal⁷⁻⁸.

For patients with previous infection and viral load over 2.1 log copies/ml, prophylactic treatment is indicated two weeks before the treatment onset, maintained throughout it and up to 12 months after immunosuppressant drug interruption⁷⁻⁸.

Patients with HBsAg⁺ should be referred to a hepatologist and should start treatment with nucleoside analogs as soon as possible. The use of nucleoside analogs should continue during the entire immunosuppressant treatment and up to 12 months after its interruption⁷⁻¹⁰.

Prophylactic treatment is achieved with nucleoside analogs, such as lamivudine, adefovir, and entecavir. In patients with rheumatic diseases, first-line treatment is with entecavir 0.5 mg/day. That indication is a result of the potent antiviral activity, low resistance rates and long term studies of its association with rheumatic drugs⁷⁻¹⁰.

By analyzing cases 2 and 3, we have patients presenting HBsAg+ during treatment with a DMARD. In that case, we notice the importance of the ongoing serologic monitoring and use of entecavir prophylaxis, which should be kept during the entire treatment and in association with a hepatologist⁷⁻¹⁰.

In the literature, it is emphasized that even with hepatitis B diagnosis during the immunosuppressant treatment, this should not be abruptly interrupted, since immune restoration may cause rapid immune-mediated destruction of infected hepatocytes, leading to hepatitis⁷⁻⁸.

Concerning TNF inhibitors, HBV reactivation is a known consequence. The frequency of previous infections in patients with rheumatic diseases is extremely diverse in the literature^{7,11}. Silva et al. in 2009 assessed seropositivity to hepatitis B and C in 143 patients with rheumatic diseases using TNF inhibitors, and found previous positivity for hepatitis B infection in 5% of those patients. They observed that those patients might, despite the low probability, be a risk group for viral reactivation¹¹.

Concerning the safety of use of those drugs, several articles observe that, with appropriate prophylactic measures, reactivation possibility is low, reiterating the need for systematic serologic monitoring and appropriate prophylaxis according to each case, especially in endemic areas, including the Amazonas^{1,12}.

Acknowledgments: We offer our deepest thanks to the institution that provided technical support for the development and implementation of this study.

Conflict of Interest: The authors declare that there is no conflict of interest.

REFERENCES

1. Ye H, Zhang XW, Mu R, Fang LK, Gu JR, Lin J, et al. Anti-TNF therapy in patients with HBV infection--analysis of 87 patients with inflammatory 66 arthritis. *Clin. Rheumatol.* 2014;33(1):119-23.
2. Zingarelli S, Frassi M, Bazzani C, Scarsi M, Puoti M, Airò P. Use of tumor necrosis factor-alpha-blocking agents in hepatitis B virus-positive patients: reports of 3 cases and review of the literature. *J. Rheumatol.* 2009;36(6):1188-94.
3. Zheng B, Li T, Lin Q, et al. Prevalence of hepatitis B surface antigen in patients with ankylosing spondylitis and its association with HLA-B27: a retrospective study from south China. *Rheumatol Int.* 2012;32(7):2011-6.
4. Global Hepatitis Report 2017. Geneva: World Health Organization; 2017. Licence: CC BY-NC-SA 3.0 IGO.
5. Ministério da Saúde. Boletim Epidemiológico - Hepatites Virais. 2016, volume 47.
6. Garcia JCC, Medrano M. Reactivación de hepatitis B en un paciente con espondiloartritis tras a suspender metotrexato y eficacia del tratamiento con antiviral sin asociación con adalimumab. *Reumatol. Clin.* 2011;7(3):200-2.
7. Mori S, Fujiyama S. Hepatitis B virus reactivation associated with antirheumatic therapy: risk and prophylaxis recommendations. *World J. Gastroenterol.* 2015;21(36):10274-89.
8. Drafting Committee for Hepatitis Management Guidelines and the Japan Society of Hepatology. JSH Guidelines for the Management of Hepatitis B Virus Infection. *Hepatol. Res.* 2014;44(Suppl S1):1-58.
9. Vassilopoulos D. Should we routinely treat patients with autoimmune/rheumatic diseases and chronic hepatitis B virus infection starting biologic therapies with antiviral agents? *Yes. Eur J Intern Med.* 2011;22(6):572-5.
10. Marzano A. Management of HBV Infection During Immunosuppressive Treatment. *Mediterr. J. Hematol. Infect Dis.* 2009;1(3):e2009025.
11. Silva BSP, Endo AC, Medeiros AC, Golçalves C, Moraes GCB, Bonfá E, et al. Frequência de anticorpos aos agentes etiológicos da síndrome da imunodeficiência adquirida, sífilis, hepatites virais B e C e doença de Chagas em pacientes reumatológicos em tratamento com antifator de necrose tumoral (Tumor Necrosis Factor – TNF). *Rev Bras Reumatol.* 2009;49(5):590-8.
12. Vassilopoulos D, Apostolopoulou A, Hadziyannis E, Papa-theodoridis GV, Manolakopoulos S, Koskinas J, et al. Long-term safety of anti-TNF treatment in patients with rheumatic diseases and chronic or resolved hepatitis B virus infection. *Ann. Rheum. Dis.* 2010;69(7):1352-5.