

Disseminated cutaneous sporotrichosis in patient with alcoholism

Ana Maria Benvegnú^{[1],[2]}, Juliana Stramari^[1], Lia Natália Diehl Dallazem^{[1],[2]},
Raíssa Massaia Londero Chemello^{[1],[3]} and André Avelino Costa Beber^{[1],[3]}

[1]. Departamento de Dermatologia, Hospital Universitário de Santa Maria, Santa Maria, RS, Brasil.

[2]. Programa de Pós-Graduação em Ciências da Saúde, Universidade Federal de Santa Maria, Santa Maria, RS, Brasil.

[3]. Departamento de Clínica Médica, Universidade Federal de Santa Maria. Santa Maria, RS, Brasil.

Abstract

Sporotrichosis is the most prevalent subcutaneous mycosis and is characterized by a subacute or chronic development of a cutaneous or subcutaneous nodular lesion. It is caused by the dimorphic fungus *Sporothrix* spp, which may manifest in different clinical forms. The disseminated cutaneous form is uncommon and is more likely to occur in immunocompromised patients. We report a 47-year-old male patient with multiple cutaneous and subcutaneous nodules. The patient was diagnosed with disseminated cutaneous sporotrichosis based on the isolation and identification of *Sporothrix* spp. The patient was treated with potassium iodide, which resulted in clinical improvement of the lesions.

Keywords: Sporotrichosis. Alcoholism. Subcutaneous nodules.

INTRODUCTION

Sporotrichosis is a subacute or chronic subcutaneous mycosis caused by a dimorphic and geophilic fungus, *Sporothrix* spp, which can infect humans and other mammals^{1,2}. Infection occurs through trauma to the skin through contaminated wood, soil and decomposing plants, as well as abrasions or bites from contaminated animals, particularly domestic cats, which are primarily responsible for the current increase of cases in humans in the Brazilian territory^{1,3,4}.

Sporotrichosis has a global distribution, although it is more common in regions with a tropical and subtropical climate, such as Central America, South America, and Africa². In Brazil, epidemics have been reported in recent decades in the State of Rio de Janeiro⁴.

Sporotrichosis is classified into the following four clinical forms: localized cutaneous, cutaneolymphatic, disseminated cutaneous, and extracutaneous. The most common form in humans is the cutaneolymphatic form, followed by the localized cutaneous form^{2,5,6}.

Disseminated sporotrichosis is an uncommon form of presentation, found in approximately 4% of cases and is usually related to diseases (immunosuppressive disease such as human immunodeficiency virus (HIV) infection and hepatitis

C, diabetes mellitus and alcoholism) and treatment measures (chemotherapy treatment for neoplasia, transplantation, and corticosteroid treatment)⁷.

Cell culture, is the gold standard diagnostic test. However, anatomopathological examination may strongly suggest the diagnosis by showing granulomatous inflammation, epithelial hyperplasia, and histiocytic plasma cell infiltration. Asteroid corpuscles can still be found^{2,8}.

The recommended treatment for the disseminated cutaneous form is amphotericin B and, after initial disease control, maintenance with itraconazole. In endemic areas, the saturated solution of potassium iodide is considered an excellent option due to its cost-effectiveness².

We report a case of disseminated cutaneous sporotrichosis with an exuberant clinical condition in a patient with alcoholism.

CASE REPORT

A 47-year-old male patient, who worked as a farmer, presented with a soft, unattached and painless nodule in the left leg that had been present for 1 year. The appearance of similar disseminated cutaneous lesions occurred subsequently after the first lesion, with progressive growth, and drainage of purulent secretion as well as a weight loss of 13kg in the 3 months prior to his visit were noted. The patient had a 30-year history of alcoholism but no other medical conditions. On physical examination, the patient had cutaneous softened nodules and subcutaneous masses, some with superficial ulceration and drainage of a purulent secretion in the upper and lower limbs, trunk, abdomen, scalp, and cervical region

Corresponding author: Dra. Ana Maria Benvegnú.

e-mail: anabenvegnu@yahoo.com.br

Received 16 August 2017

Accepted 17 November 2017

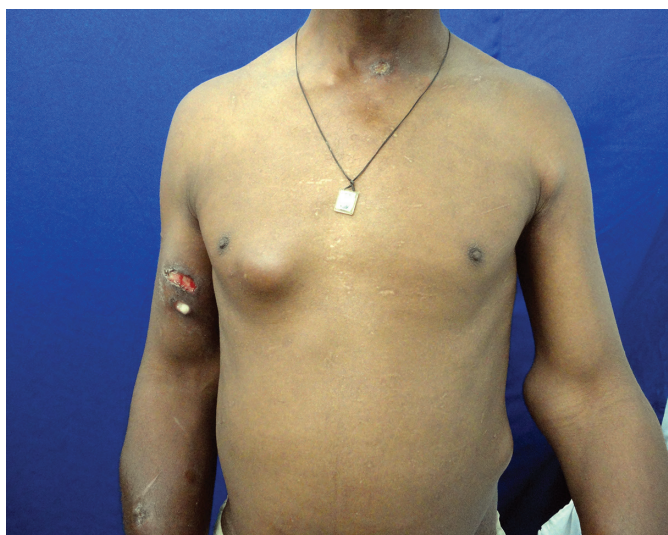

FIGURE 1 - Softened nodules and skin masses in the upper limbs, trunk, abdomen, and cervical region.

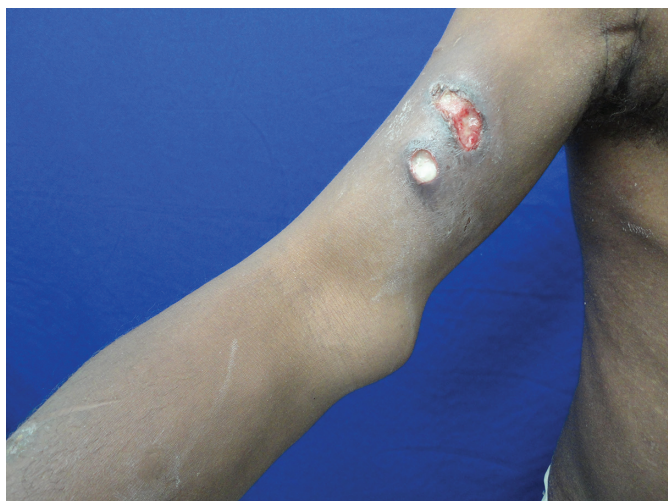


FIGURE 2 - Superficial ulceration and drainage of a purulent secretion in the upper limb.

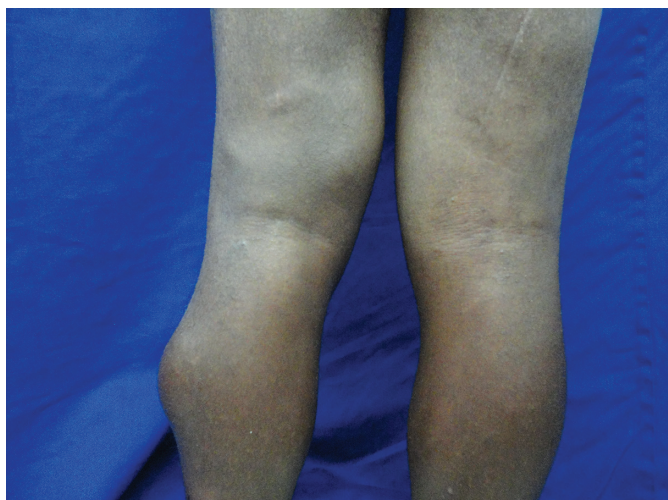


FIGURE 3 - Softened nodules and skin masses in the lower limbs.

(**Figure 1, Figure 2 and Figure 3**). Skin biopsy and mycological examination showed a positive culture for *Sporothrix* spp. Chest radiography and abdominal ultrasound results were normal, except for the presence of visceral involvement. The laboratory tests (hemogram, kidney function, liver function and thyroid function) did not show any abnormal results, and the serology test results [hepatitis B, hepatitis C, Venereal Disease Research Laboratory (VDRL) and HIV] were negative. The patient was then diagnosed with disseminated cutaneous sporotrichosis and treatment with saturated potassium iodide (20 drops three times a day) was started for 5 months, which resulted in complete resolution of the lesions. Upon 5-year follow-up, the patient reported continued alcoholism.

DISCUSSION

We present an unusual case of disseminated cutaneous sporotrichosis without systemic involvement in a patient with alcoholism who lived in an endemic area of this disease. In this case, the likely contributing factor of the spread of the fungus was the alcoholism. Our report corroborates the association previously reported by other authors^{7,9,10,11} between alcoholism and the spread of sporotrichosis.

We believe that the alcoholism and the lack of access to dermatological services delayed the time to diagnoses and treatment and therefore contributed to this unusual form of sporotrichosis. We know that chronic alcohol consumption suppresses innate and adaptive immune systems, yet activates chronic inflammation. Ethanol is a known inhibitor of nuclear factor kappa B (NF- κ B) activation and its consumption is associated with decreased circulating levels of tumor necrosis factor (TNF) and interleukin-1 beta (IL-1 β); however, the methods through which ethanol exerts its immunosuppressive effects are still unclear.

The patient was treated with a saturated solution of potassium iodide, which had a satisfactory therapeutic response. This resulted in a complete resolution of symptoms, demonstrating the favorable cost-benefit ratio of this therapeutic option.

Acknowledgments

I thank the dermatology department and the dermatology professors for providing the knowledge and opportunity to learn from clinical cases. I also thank the patient who kindly agreed to have this case reported.

Conflicts of interest

The authors declare that there is no conflict of interest.

REFERENCES

1. Madrid IM, Mattei AS, Fernandes CG, Nobre MO, Meireles MC. Epidemiological findings and laboratory evaluation of sporotrichosis: a description of 103 cases in cats and dogs in southern Brazil. *Mycopathologia*. 2012;173(4):265-73.
2. Ramos-e-Silva M, Vasconcelos C, Carneiro S, Cestari T. Sporotrichosis. *Clin Dermatol*. 2007;25(2):181-7.
3. Barros MB, Schubach AO, do Valle AC, Gutierrez Galhardo MC, Conceição-Silva F, Schubach TM, et al. Cat-transmitted

- sporotrichosis epidemic in Rio de Janeiro, Brazil: description of a series of cases. *Clin Infect Dis*. 2004;38(4):529-35.
4. Ishida K, de Castro RA, Borba Dos Santos LP, Quintella LP, Lopes-Bezerra LM, Rozental S. Amphotericin B, alone or followed by itraconazole therapy, is effective in the control of experimental disseminated sporotrichosis by *Sporothrix brasiliensis*. *Med Mycol*. 2015;53(1):34-41.
 5. Vásquez-del-Mercado E, Arenas R, Padilla-Desgarenes C. Sporotrichosis. *Clin Dermatol*. 2012;30(4):437-43.
 6. da Rosa AC, Scroferneker ML, Vettorato R, Gervini RL, Vettorato G, Weber A. Epidemiology of sporotrichosis: a study of 304 cases in Brazil. *J Am Acad Dermatol*. 2005;52(3 Pt 1):451-9.
 7. Espinoza-Hernández CJ, Jesús-Silva A, Toussaint-Caire S, Arenas R. Disseminated sporotrichosis with cutaneous and testicular involvement. *Actas Dermosifiliogr*. 2014;105(2):204-6.
 8. Patel A, Mudenda V, Lakhi S, Ngalamika O. A 27-year-old severely immunosuppressed female with misleading clinical features of disseminated cutaneous sporotrichosis. *Case Rep Dermatol Med*. 2016;2016Article ID:9403690.
 9. Nassif PW, Granado IR, Ferraz JS, Souza R, Nassif AE. Atypical presentation of cutaneous sporotrichosis in an alcoholic patient. *Dermatol Online J*. 2012;18(6):12.
 10. Sharon VR, Kim J, Sudhakar S, Fung MA, Maniar A. Disseminated cutaneous sporotrichosis. *Lancet Infect Dis*. 2013;13(1):95.
 11. Chang S, Hersh AM, Naughton G, Mullins K, Fung MA, Sharon VR. Disseminated cutaneous sporotrichosis. *Dermatol Online J*. 2013;19(11):20401.