

Images in Infectious Diseases

Pericardial effusion with a ruptured mycotic pseudoaneurysm secondary to *Salmonella* infection

Lai Kuan Leong^[1] , Bui Khiong Chung^[2]  and Chen Ting Tan^[2] 

[1]. Ministry of Health Malaysia, Miri General Hospital, Department of Medicine, Miri, Sarawak, Malaysia.

[2]. Ministry of Health Malaysia, Sarawak General Hospital Heart Centre, Department of Cardiology, Kuching, Sarawak, Malaysia.

A 59-year-old Iban man with an underlying hypertension and a history of pulmonary tuberculosis experienced an on-off chest pain and reduced effort tolerance for 1 month. He presented to the hospital due to a worsening chest pain.

On physical examination, the patient was afebrile. Result of the cardiovascular examination was unremarkable. Consolidation or effusion was not observed on chest radiography. Electrocardiography showed diffuse ST elevation; hence, fibrinolytic therapy was administered (**Figure 1**). Electrocardiography showed persistent ST elevation without dynamic ischemic changes. The patient's C-reactive peptide level was high (408.8 mg/L).

The ST elevation myocardial infarction had reverted to pericarditis. Nonsteroidal anti-inflammatory drug therapy was started but was later switched to high-dose aspirin due to acute kidney injury. Echocardiography revealed pericardial effusion with signs of tamponade (**Figure 2**). Pericardiocentesis was performed, and the pericardial fluid culture showed *Salmonella* enteritidis. Intravenous ceftriaxone was administered.

The patient's condition deteriorated.

Patient's computed tomography angiogram showed a ruptured aortic arch saccular aneurysm measuring 1.7×3×4.1 cm,

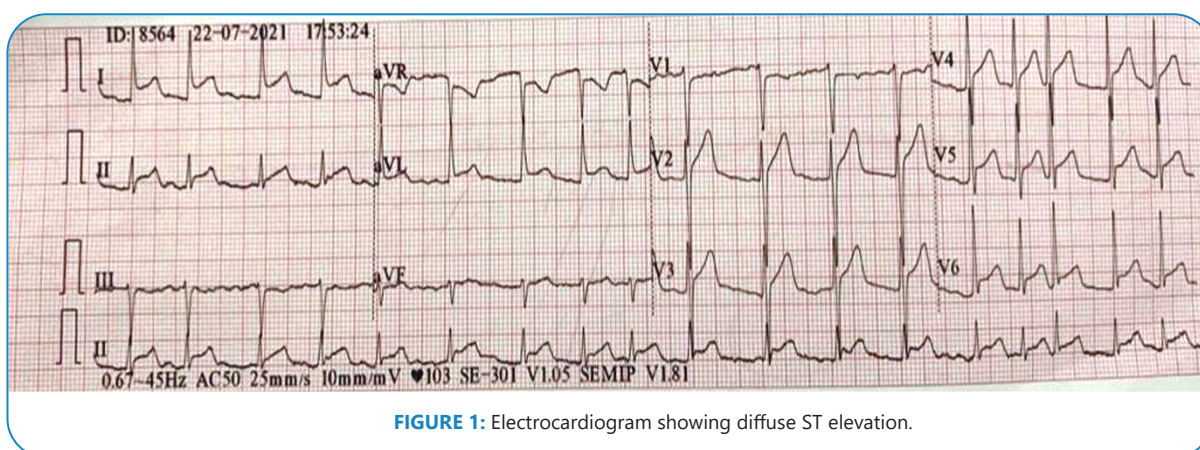


FIGURE 1: Electrocardiogram showing diffuse ST elevation.

Corresponding author: Dr. Lai Kuan Leong. **e-mail:** lk429@yahoo.com

Authors' contribution: LKL: Conceptualization of the study, acquisition of data, writing the article and submitting the article. BKC: Supervision, review and editing the article. CTT: Supervision, review and editing the article.

Conflict of Interest: The authors declare that there is no conflict of interest.

Financial Support: We did not receive any financial support.

Received 11 February 2022 | **Accepted** 9 March 2022

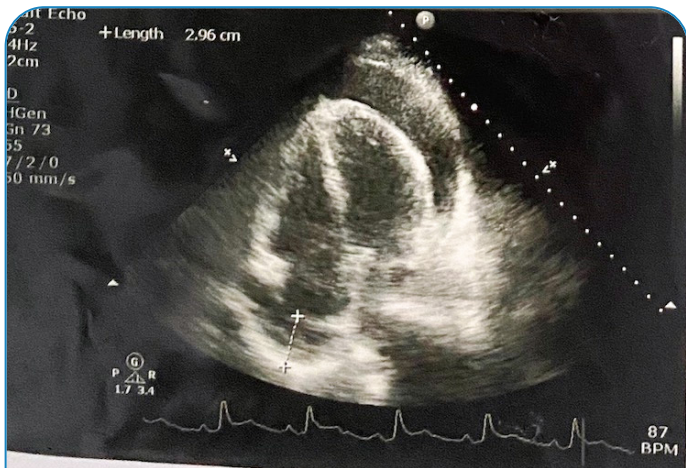


FIGURE 2: Echocardiography showing pericardial effusion and tamponade signs.

surrounded by a rim of mediastinal hematoma 5.7×6.6×5.3 cm that extended into the left main bronchus (**Figure 3**).

The patient was frail to undergo surgical intervention and eventually died.

Mycotic pseudoaneurysms and massive pericardial effusion due to *Salmonella* infection rarely occur¹. However, complications are often fatal. Hence, early diagnosis and intervention are crucial to reduce mortality¹.

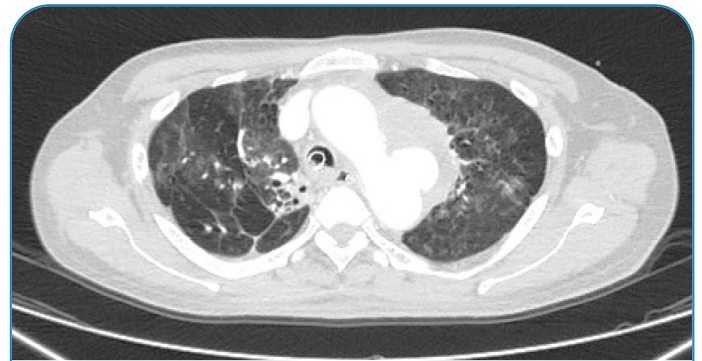

FIGURE 3: Computed tomography angiogram showing a ruptured aortic arch saccular aneurysm (arrow).

ACKNOWLEDGMENTS

We would like to thank the Director General of Health Malaysia for his permission to publish this article. We express our greatest gratitude to Hospital Miri staff who took good care of the patient.

REFERENCES

1. Guo Y, Bai Y, Yang C, Wang P, Gu L. Mycotic aneurysm due to *Salmonella* species: clinical experiences and review of the literature. *Braz J Med Biol Res.* 2018;51(9):e6864.