

Clinical and laboratorial evidence of *Rickettsia felis* infections in Latin America

Evidência clínica e laboratorial de infecções por *Rickettsia felis* na América Latina

Márcio Antônio Moreira Galvão¹, Cláudio Mafra², Chequer Buffe Chamone³, Simone Berger Calic³, Jorge E. Zavala-Velazquez⁴ and David Hughes Walker⁵

ABSTRACT

After the discovery and initial characterization of *Rickettsia felis* in 1992 by Azad and cols, and the subsequent first description of a human case of infection in 1994, there have been two communications of human rickettsiosis cases caused by *Rickettsia felis* in Latin America. The first one was published in 2000 by Zavala-Velazquez and cols in Mexico. In 2001 Raoult and cols described the occurrence of two human cases of *Rickettsia felis* rickettsiosis in Brazil. In the present discussion these two articles were compared and after the description of the principal signs and symptoms, it was concluded that more studies are needed with descriptions of a greater number of patients to establish the true frequency of the clinical signs and symptoms present in *Rickettsia felis* rickettsiosis.

Key-words: *Rickettsia felis*. Rickettsioses. Latin America.

RESUMO

Depois da descoberta e caracterização inicial da *Rickettsia felis* em 1992 por Azad e cols, e à descrição subsequente do primeiro caso de infecção humana em 1994, houveram duas comunicações de rickettsioses causadas por *Rickettsia felis* na América Latina. A primeira foi feita por Zavala-Velazquez e cols em 2000 no México. Em 2001, Raoult e cols descreveram a ocorrência de dois casos humanos de rickettsiose por *Rickettsia felis* no Brasil. Na presente discussão, esses dois artigos foram comparados, e depois da descrição dos principais sinais e sintomas, conclui-se que outros estudos são necessários, com a participação de um maior número de pacientes, para se estabelecer a verdadeira frequência dos sinais clínicos e sintomas presentes nas rickettsioses por *Rickettsia felis*.

Palavras-chaves: *Rickettsia felis*. Rickettsioses. Latin America.

The pathogenic *rickettsiae* are a group of intracellular bacteria responsible for a variety of human diseases. *Rickettsia rickettsii* and *Rickettsia typhi* and their respective diseases, Brazilian spotted fever, the equivalent of Rocky Mountain spotted fever transmitted by the *Amblyomma cajennense* tick, and murine typhus transmitted by the Oriental rat flea, have been known in Brazil since the 1920s^{5,6}.

Rocky Mountain spotted fever was documented in Mexico during the 1930s, although epidemic typhus caused by

Rickettsia prowazekii had importance in the outbreaks that have been described since 1736. Rickettsial diseases have subsequently received little attention in tropical areas of Latin America. Endemic Rocky Mountain spotted fever and other rickettsioses such as epidemic typhus have been identified in countries of Latin America only because their high fatality-case ratio has demanded investigation. It is possible that other spotted fever group rickettsioses have occurred unrecognized in Mexico and Brazil for long periods.

1. Departamento de Nutrição Clínica e Social da Escola de Nutrição da Universidade Federal de Ouro Preto, Ouro Preto, MG. 2. Departamento de Bioquímica e Biologia Molecular da Universidade Federal de Viçosa, Viçosa, MG. 3. Fundação Ezequiel Dias, Belo Horizonte, MG. 4. Universidad Autónoma de Yucatán, Mexico. 5. World Health Organization Collaborating Center for Tropical Diseases of University of Texas Medical Branch, Texas, USA.

Address to: Dr. Márcio A. Moreira Galvão. DNCS/EN/UFOP, 35400-000 Ouro Preto, MG, Brazil.

Tel: 55 313559-1838.

e-mail: mgalvao@enut.ufop.br.

Recebido para publicação em 20/11/2002

Aceito em 23/4/2004

Serological and clinical evidence of severe and mild-to-moderate cases of rickettsioses and the application of molecular methods including detection by PCR amplification and characterization by DNA sequence analysis has allowed the identification of new species of *Rickettsia*, such as *R. felis* in opossums, fleas^{9,10} and blood and skin from diseased humans in the USA, Mexico, France, Brazil, and Germany^{2,4,7,8,11}.

MATERIAL AND METHODS

During the 1990's reports of serological studies in Mexico¹² and Brazil³ discussed the possibility of the existence of other rickettsioses in these countries. In the role of the new rickettsioses, *R. felis* rickettsiosis currently appears to be one of the most important. Some authors^{7,11} have discussed the existence of human cases caused by this bacterium in Mexico and Brazil. The objective of this article was to compare the data and clinical symptoms of human rickettsiosis cases described in these two communications and to evaluate the severity, epidemiology and clinical course of this new rickettsiosis.

RESULTS

In Mexico three patients with fever, exanthem, headache and central nervous system involvement were diagnosed with *R. felis* infection by specific PCR of blood in two cases and PCR of skin in another case. In all three cases, acute serum samples contained no detectable antibodies to *rickettsiae*. The convalescent sera contained antibodies at a titer of 1:64 to *Rickettsia akari*, *R. rickettsii* and *R. typhi*¹.

PCR amplification of DNA from skin biopsy and blood samples with specific primers for the *Rickettsia* 17kDa protein gene was confirmed by DNA sequencing, which showed that the sequence was 100% identical to *R. felis*¹. In the two human cases of *R. felis* rickettsiosis in Brazil, first suspected to be Brazilian spotted fever, the disease was confirmed in serum by IFA (IgG/IgM) with high titers to *R. felis* (1024/64 and 512/64) and by identification of

R. felis in one case by DNA sequencing following nested-PCR amplification from a serum sample⁸.

In both reports from Mexico and Brazil (Figure 1), the patients (five) initially had systemic symptoms (fever, headache and myalgia). All the cases also showed a rash. Visceral involvement was suggested in all patients with abdominal pain, nausea and vomiting and diarrhea in four patients. Four patients had involvement of central nervous system with photophobia in two patients from Mexico and hearing loss and signs of meningismus in the other one and the presence of coma in one of the Brazilian cases. One patient from Mexico had conjunctivitis. Laboratory data in the Brazilian cases revealed thrombocytopenia (platelets <100,000/mm³) and increased serum concentration of aspartate transaminase associated with hepatosplenomegaly. One of the three Mexican cases manifested anemia, leukocytosis, thrombocytosis and prolonged prothrombin time. The third one showed leukopenia.

DISCUSSION

The clinical manifestations in these patients increase our knowledge of the illness caused by *R. felis* infection.

Fever, headache, and myalgia suggested systemic acute-phase response, the exanthem reflects a vasculitis, a common manifestation of rickettsial diseases, and the occurrence of abdominal pain, nausea, vomiting and diarrhea indicate possible visceral involvement. Neurological symptoms suggest that we are facing a potentially severe new rickettsial disease.

The epidemiologic data suggested contact with an opossum in one of the Mexican cases, and with fleas and ticks in the Brazilian patients and one of the Mexican cases. Regarding treatment, the Brazilian cases received chloramphenicol, and in the Mexican cases one patient received doxycycline after the acute illness. All these cases survived in the two countries studied.

More studies are needed to establish the real frequency of the symptoms present in *R. felis* rickettsiosis, the true case-fatality ratio of this disease, the epidemiology and the role of *R. felis* as an important pathogen.

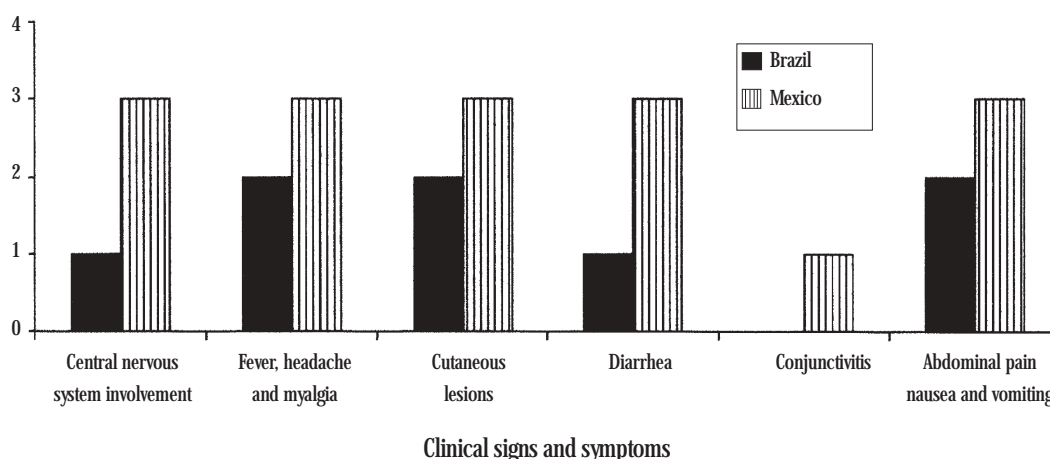


Figure 1 - Clinical and symptoms in Brazilian and Mexican patients with *Rickettsia felis* infection.

REFERENCES

1. Azad AF, Sacci Jr JB, Nelson WM, Dasch GA, Schmidtman ET, Carl M. Genetic characterization and transovarial transmission of a typhus-like *Rickettsia* found in cat fleas. Proceedings of National Academy of Science of the United States of America 89:43-46, 1992.
2. Bouyer DH, Stenos J, Croquet-Valdes P, Moron CG, Popov VL, Zavala-Velazquez JE, Foil LD, Stothard DR, Azad AF, Walker DH. *Rickettsia felis*: molecular characterization of a new member of the spotted fever group. International Journal of Systematic and Evolutionary Epidemiology 51:339-347, 2001.
3. Galvão MAM, Chamone, CB, Calic SB, Machado MC, Otoni MEA, Dietze R, Moron C, Feng HM, Olano JP, Walker DH. Serologic evidence of spotted fever group *Rickettsia* in Novo Cruzeiro Municipality-Minas Gerais State-Brazil. In: Raoult D, Brouqui P (eds) Rickettsial Diseases at the Turn of the Third Millennium, Marseille, Elsevier p. 240-243, 1999.
4. Higgins JA, Sacci JB, Schrieffer ME, Endris RG, Azad AF. Molecular identification of *Rickettsia*-like microorganisms associated with colonized cat fleas (*Ctenocephalides felis*). Insect Molecular Biology 3:27-33, 1994.
5. Monteiro JL, Fonseca F. Typho endêmico de São Paulo. Novas experiências sobre a transmissão experimental por carrapatos *Boophilus microplus* e *Amblyomma cajennense*. Memórias do Instituto Butantan (São Paulo) 10:33-50, 1932.
6. Piza JT. Considerações epidemiológicas e clínicas sobre o Tifo Exantemático de São Paulo. São Paulo, Sociedade Imprensa Paulista 11-119, 1932.
7. Raoult D, Fournier P-E, Abboud P, Caron F. First documented human *Rickettsia aeschlimannii* infection. Emerging Infectious Diseases 8:748-749, 2002.
8. Raoult D, La Scola B, Enea M, Fournier P-E, Roux V, Fenollar F, Galvão MAM, Lamballerie X. A flea associated *Rickettsia* pathogenic for humans. Emerging Infectious Diseases 7:73-81, 2001.
9. Schrieffer ME, Sacci JB Jr, Dumler JS, Bullen MG, Azad AF. Identification of a novel rickettsial infection in a patient diagnosed with murine typhus. Journal of Clinical Microbiology 32:949-954, 1994.
10. Schrieffer ME, Sacci Jr JB, Taylor JP, Higgins JA, Azad AF. Murine typhus: updated roles of multiple urban components and a second typhus-like *Rickettsia*. Journal of Medical Entomology 31:681-685, 1990.
11. Zavala-Velazquez JE, Ruiz-Sosa JA, Sanchez-Elias RA, Becerra-Carmona G, Walker DH. *Rickettsia felis* rickettsiosis in Yucatan. Lancet 356:1079-1080, 2000.
12. Zavala-Velazquez JE, Yu XJ, Walker DH. Unrecognized spotted fever group rickettsioses masquerading as dengue fever in Mexico. American Journal of Tropical Medicine and Hygiene 55:157-159, 1996.