

Images in Infectious Diseases

Aureobasidium melanogenum isolation from the cerebrospinal fluid of a patient with human immunodeficiency virus/acquired immunodeficiency syndrome: A novel report

Lincoln de Oliveira Sant'Anna^[1], Louisy Sanches dos Santos^[1]
and Max Roberto Batista Araújo^[2]

[1]. Universidade do Estado do Rio de Janeiro, Faculdade de Ciências Médicas,
Departamento de Microbiologia, Imunologia e Parasitologia, Rio de Janeiro, RJ, Brasil.

[2]. Instituto Hermes Pardini, Núcleo Técnico Operacional, Setor de Microbiologia, Vespasiano, MG, Brasil.

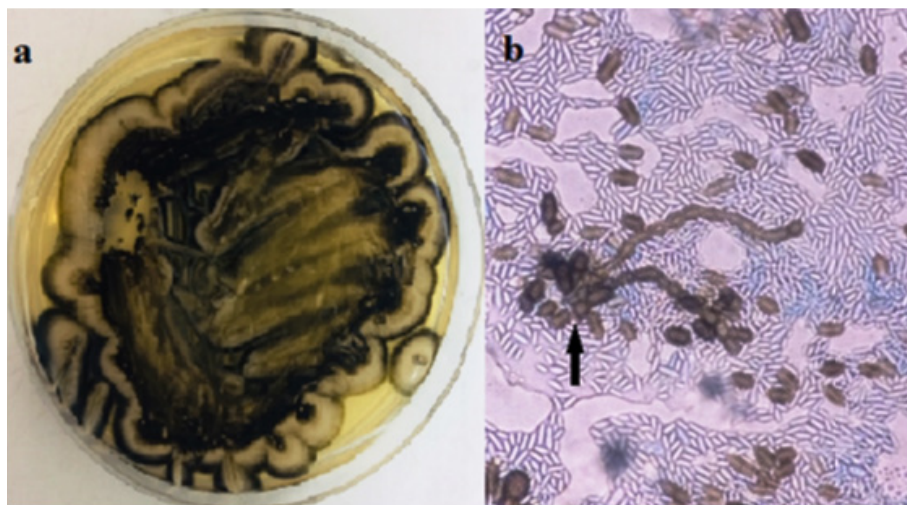


FIGURE 1: (a): Macromorphology of *A. melanogenum* in Sabouraud Dextrose agar incubated for 7 days at 25 °C. (b): Image showing dark brown conidia of *A. melanogenum* (black arrow) on a wet mount microscopy slide (40× objective lens).

A 22-year-old Brazilian man with untreated ulcerative colitis and human immunodeficiency virus (HIV) infection was admitted to the intensive care unit (ICU) for holocranial headache, fever, nausea, malaise, and diarrhea. Antiretroviral therapy (ART) was discontinued eight months earlier. Medical history included prior hospitalization due to pneumomediastinum secondary to perforated esophageal moniliasis. Laboratory tests showed leukocytosis, elevated C-reactive protein levels, high HIV viral load (133.627 copies/mL), low CD4+T-cell count (14 cells/mm³), and abnormal

levels of cerebrospinal fluid (CSF) proteins and glucose. Treatment with ceftriaxone, metronidazole, and mebendazole was initiated. Further CSF analysis was negative for *Cryptococcus* spp., but fungal culture showed the growth of black, rough colonies (**Figure 1a**) with conidia as observed by optical microscopy (**Figure 1b**). The fungus was identified as *Aureobasidium melanogenum* using gene sequencing. Treatment with amphotericin B lipid complex was initiated for 14 days, and he was discharged from the ICU after re-initiating ART.

A. melanogenum is ubiquitous in the environment. Although commonly considered a contaminant, this species has been increasingly associated with invasive infections in immunocompromised patients and seems to present a high pathogenic potential¹⁻³.

Corresponding author: MSc. Lincoln de Oliveira Sant'Anna.

e-mail: lincolnsantanna2013@gmail.com

<https://orcid.org/0000-0002-6933-8961>

Received 5 May 2021

Accepted 15 June 2021

The prognosis of *A. melanogenum* infections depends on the extent of infection and host conditions¹ and on accurate species identification and therapy. To the best of our knowledge, this is the first report of *A. melanogenum* isolation from the CSF of a patient with acquired immunodeficiency syndrome (AIDS). Although such cases in HIV/AIDS patients are rare^{1,2}, physicians should be aware of the possibility of *A. melanogenum* infections in these individuals.

ACKNOWLEDGMENTS

We offer our deepest thanks to the institutions that provided technical support for the development and implementation of this study and to Rafael Sanches for his availability in advising on editing the image for this work.

AUTHOR'S CONTRIBUTION

LOS: Conceptualization, Data curation, Formal analysis, Writing-original draft, and Writing-review & editing; LSS: Conceptualization, Data curation, Formal analysis, and Writing-original draft; MRBA: Conceptualization, Data curation, Formal analysis, Investigation, Methodology, Project administration, and Writing-review & editing.

CONFLICT OF INTEREST

The authors declare that there is no conflict of interest.

ETHICAL APPROVAL

The study was a retrospective analysis of laboratory data. No ethical approval was applied.

FINANCIAL SUPPORT

No funding was received.

ORCID

Lincoln de Oliveira Sant'Anna: 0000-0002-6933-8961

Louisy Sanches dos Santos: 0000-0002-5303-6395

Max Roberto Batista Araújo: 0000-0002-3293-8496

REFERENCES

1. Wang SC, Lo HJ, Lin LJ, Chen CH. Port catheter-associated *Aureobasidium melanigenum* fungemia. *J Formos Med Assoc.* 2018;117(4):346-7. Available from: <https://doi.org/10.1016/j.jfma.2017.06.009>.
2. Mittal J, Szymczak WA, Pirofski LA, Galen BT. Fungemia caused by *Aureobasidium pullulans* in a patient with advanced AIDS: a case report and review of the medical literature. *JMM Case Rep.* 2018;5(4):e005144. Available from: <https://doi.org/10.1099/jmmcr.0.005144>.
3. Wang M, Danesi P, James TY, Al-Hatmi AMS, Najafzadeh MJ, Dolatabadi S, et al. Comparative pathogenicity of opportunistic black yeasts in *Aureobasidium*. *Mycoses.* 2019;62(9):803-11. Available from: <https://doi.org/10.1111/myc.12931>.