

Case Report

Hepatic fascioliasis in Mashhad, Northeast Iran: first report

Alireza Badirzadeh^[1] and Sadaf Sabzevari^[2]

[1]. Department of Medical Parasitology and Mycology, School of Medicine, Shahid Beheshti University of Medical Sciences, Tehran, Iran.

[2]. North Khorasan University of Medical Sciences, Bojnurd, Iran.

Abstract

Fascioliasis is a zoonotic disease caused by a leaf-like worm (fluke) called *Fasciola*. Herein, we present a case of human hepatic fascioliasis. A 57-year-old man was referred to the hospital for ambiguous gastrointestinal symptoms with suspected hemangioma. Hepatic fascioliasis was diagnosed using abdominal computed tomography and serology. He tested positive for the IgG antibody against *Fasciola hepatica*. The patient was treated successfully with triclabendazole. This is the first published report on the occurrence of fascioliasis in Northeast Iran, a non-endemic area for fascioliasis. Our results suggest the emergence of a new focus in the region.

Keywords: Fascioliasis. Hemangioma. *Fasciola hepatica*.

INTRODUCTION

Fascioliasis is a zoonotic, food-borne, helminthic disease caused by *Fasciola* spp.^{1,2}. It generally causes severe infection in domestic animals such as sheep, goats, and cattle, which are its definitive hosts; however, it can also infect humans sporadically as incidental hosts. The risk of human fascioliasis (HF) has increased considerably in the last decade, and HF is now considered an emerging disease. It has been deemed as one of the *neglected tropical diseases* by the World Health Organization (WHO)². Approximately 2.4-17 million people are estimated to be infected by this disease in more than 51 countries and approximately 91 million people are at risk of infection worldwide^{2,3}.

Iran is one of the main endemic foci of fascioliasis⁴ (**Figure 1**), and HF has repeatedly been highlighted in provinces situated along the shore of the Caspian Sea⁵. Recent studies have shown that the disease is prevalent in many parts of the country including Kurdistan, Zandjan, Mazandaran, Tehran, Azerbaijan, Gilan, Kermanshah, Kohgiluyeh and Boyer-Ahmad, Ardabil, Ilam, Isfahan, and Lorestan⁶. In the past few decades, Iran has experienced two major outbreaks of human fascioliasis – in 1988 and 1999 – and more than 10,000 people were affected in each outbreak. These outbreaks were the largest worldwide and occurred in the Gilan Province in Northern Iran. Owing to the environmental conditions and dietary habits in that region,

the Gilan Province is a major endemic focus of the disease in Iran⁴. In addition, sporadic cases of the disease have been recently reported in new emerging regions such as the Mashhad district in Northeast Iran, which is a non-endemic region for HF. Interestingly, the prevalence of animal fascioliasis has decreased in this district during the past few decades⁴.

Human contamination occurs via ingestion of encysted infectious larvae or metacercariae attached to aquatic plants or floating on the surface of water. After entering the mobile phase, the metacercariae cause destruction of hepatic tissue; the fluke is trapped and undergoes necrosis. Subsequently, adult flukes cause obstruction in the biliary ducts through thickening, dilatation, and fibrosis of the segmental bile ducts⁷.

Herein, we report the first case of a hepatic mass caused by *Fasciola* spp. that was initially thought to be hemangioma in Northeast Iran.

CASE REPORT

In August 2015, a 57-year-old male mountaineer living in the Mashhad province complained of fever, abdominal discomfort, nausea, dyspepsia, loss of weight, and lack of appetite 3 months after returning from the Cloud Forest (Jangal-e Abr) (**Figure 1**). This region is located in Shahrood City, close to Abr village, near the border of the Semnan and Golestan Provinces that are the endemic foci of fascioliasis. The patient had a history of consuming freshwater plants and unsafe water.

The patient complained of progressive and gradual worsening of his symptoms. Physical examination showed the presence of abdominal distension, mild epigastric pain, eructation, and heartburn. An upper gastrointestinal (GI) endoscopy demonstrated erosive gastritis and erosive mucosa.

Corresponding author: Dr. Sadaf Sabzevari
e-mail: sadafsabzevari@hotmail.com; s.sabzevari@nkums.ac.ir
Received 21 December 2016
Accepted 28 March 2017

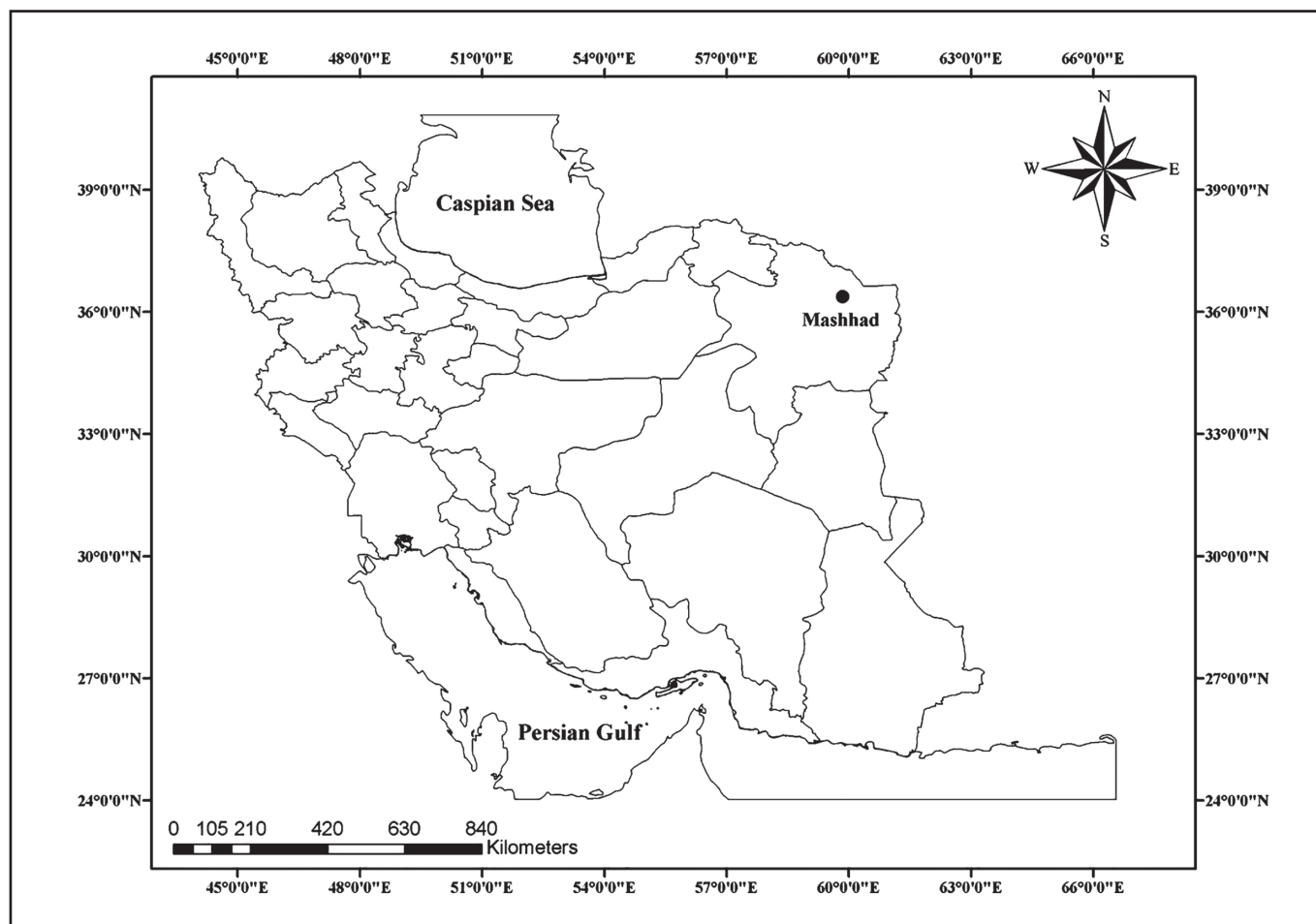


FIGURE 1 - Map of Iran showing the location of Mashhad City, in Northeast Iran (Created by Arc GIS version 10.2).

An abdominal ultrasonography revealed heterogeneity in the liver parenchyma and a nodule (12mm) in the right hepatic lobe. The size of the liver and the intrahepatic bile ducts was normal. A subsequent abdominopelvic computed tomography (CT) revealed multiple hypodense, irregular, nodular focal lesions of different sizes in segments of the right hepatic lobe. On the basis of this evidence, a diagnosis of hemangioma was confirmed. A liver biopsy was not performed, as it was dangerous to the patient's condition.

Immediately after misdiagnosis, he complained of continuous severe abdominal pain and nausea. According to the laboratory values upon admission, he had mild leukocytosis (10.06k/ μ l) with prominent eosinophilia (47.6%) and elevated alkaline phosphatase and alanine aminotransferase levels of 498IU/L and 57IU/L, respectively; however, all other parameters were normal. Subsequent laboratory studies revealed marked eosinophilia and abnormal liver function tests, indicating parasitic etiology. Stool examinations, performed thrice, were found to be consistently negative for ova of any pathogenic parasites, white blood cells, and red blood cells (RBCs). Subsequently, the patient was admitted to the hospital with a hepatic mass, which led to the suspicion of hydatidosis or a hepatic disease of an unknown origin.

After admission, a serologic evaluation and an RBC liver scan were performed. The findings of the liver scan did not indicate liver hemangioma and hydatidosis (**Figure 2A** and **Figure 2B**). Thereafter, we suspected the presence of other helminthic diseases (toxocariasis, ascariasis, and schistosomiasis). Therefore, serologic tests [immunoglobulin G (IgG)] for toxocariasis and stool/sputum exams for ascariasis and schistosomiasis were conducted; however, the results were negative. Finally, a serological test was performed to detect any antibody against fluke in the serum by using an enzyme-linked immunosorbent assay (ELISA), and the IgG antibody against *Fasciola hepatica* was found to be positive. A single dose of triclabendazole (10mg/kg) was orally administered, and the patient's symptoms improved with the reversal of eosinophilia. During the follow-up, a test to determine the serological titer was repeated after symptom improvement, and the results were negative. Moreover, CT was repeated, but did not show any focal lesions in the right hepatic lobe. During outpatient follow-up, the patient's symptoms disappeared within 1 week and no further administration of triclabendazole was needed.

DISCUSSION

The WHO has recently included Iran as one of the 6 countries where fascioliasis is a major health problem. Until 1989, HF

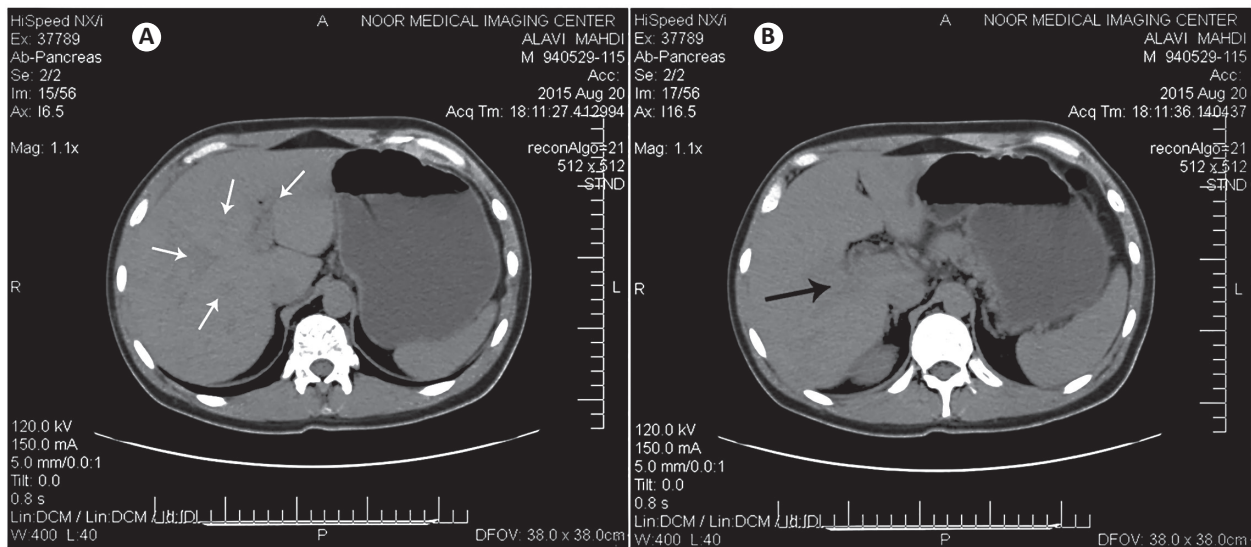


FIGURE 2 - Abdominal computed tomography scan findings. (A): Some small and tubular cysts are seen in the peripheral and subcapsular areas of right hepatic lobe of liver (white arrows). (B): An hypodense solid mass of approximately 35 × 37mm diameter is seen in the border of segments VI and VII of the live (black arrow).

was sporadic in Iran and only a few cases were reported. During several outbreaks between 1989 and 1999, thousands of cases were reported in Northern Iran, including the Gilan Province and Bandar-Anzali City, which appear to be the most significant endemic zones.

Another important northern province, Mazandaran, which shows the HF prevalence, is divided into two zones – west and east – and the prevalence of fascioliasis in the western region is clearly higher than that in the other regions. In 1998, a small outbreak of HF occurred in the western province of Kermanshah. Importantly, a new focus recently emerged from the Kohgiluyeh and Boyer-Ahmad Province. Several cases of the disease have been reported from various parts of the country, but these areas are not considered endemic⁸. Thus far, no case of HF has been reported in the city of Mashhad. The environmental conditions in this city are not ideal for successful completion of the life cycle of *Fasciola* spp. and this region is not endemic for HF. The results of our study are in agreement with those of a recent study from Iran that showed the development of a risk map with records of fascioliasis outbreaks all over the country.

Human fascioliasis has two phases: hepatic (acute) and biliary (chronic). The hepatic phase is characterized by the migration of immature worms through the liver parenchyma that starts 1-3 months after the infection. The common symptoms are pain in the right upper quadrant, fever, hepatomegaly, and marked eosinophilia^{4,7}. Fascioliasis is commonly observed in developing countries, but the rate of infection is increasing in developed countries as well due to travel and immigration⁷. In non-endemic areas, its diagnosis can be difficult for physicians in both acute and chronic phases⁵. The patient in the current case study was not a resident of an endemic area but showed symptoms 3 months after his return from Cloud Forest (Jangal-e Abr), which is near the hyperendemic region for fascioliasis.

We first suspected parasitic diseases such as toxocariasis, ascariasis, and schistosomiasis, which had similar symptoms as HF; therefore, these diseases were tested for and excluded. In clinical settings, fascioliasis needs to be differentially diagnosed from other conditions such as acute hepatitis, neoplasm, hepatic amoebiasis, or pulmonary tuberculosis. In the acute hepatic phase of HF, eosinophilia is the most common laboratory finding, as was observed in our patient. However, the other symptoms of the patient were non-specific, which led to a misdiagnosis. To establish a definite diagnosis, a CT scan was performed, which led to the diagnosis of hemangioma. The imaging features of fascioliasis may overlap with other hepatic lesions⁹. The lack of specific symptoms in the acute phase of fascioliasis makes an early, accurate diagnosis difficult. However, with the advent of serologic methods such as ELISA, which is nearly 100% sensitive and specific, its diagnosis is easier and can be confirmed¹⁰. In the current study, a definite diagnosis was made using anti-*Fasciola* antibodies in a blood titer examination, and the IgG antibody against *F. hepatica* was positive⁶. The treatment of choice for fascioliasis is triclabendazole⁴, which resulted in the relief of symptoms in the current case.

Although the prevalence of animal fascioliasis is quite common in Northeastern Iran¹¹, HF is rare and occurs in sporadic cases with fascioliasis. Moreover, HF usually spreads from the northern provinces of Iran. Therefore, a misdiagnosis of HF will eventually lead to an acute disease and can cause severe problems in the non-endemic regions; hence, physicians should remain alert about this disease and consider travel and immigration history of patients during their diagnosis.

In conclusion, this case showed a positive IgG result as well as severe eosinophilia, a history of travel to endemic areas, and the consumption of fresh vegetables were useful indicators for the diagnosis of HF.

Acknowledgments

We would like to thank Dr. Zahra Asadgol (Department of Environmental Health Engineering, School of Public Health, Iran University of Medical Sciences, Tehran, Iran) for her great technical assistance in designing the GIS map.

Conflicts of interest

The authors declare that there is no conflict of interests.

Financial support

This report received no specific grant from any funding agency in the public, commercial, or not-for-profit sectors.

REFERENCES

1. Maco V, Marcos L, Delgado J, Herrera J, Nestares J, Terashima A, et al. Efficacy and tolerability of two single-day regimens of triclabendazole for fascioliasis in Peruvian children. *Rev Soc Bras Med Trop.* 2015;48(4):445-53.
2. Ashrafi K, Bargues MD, O'Neill S, Mas-Coma S. Fascioliasis: a worldwide parasitic disease of importance in travel medicine. *Travel Med Infect Dis Disease.* 2014;12(6):636-49.
3. Keiser J, Utzinger J. Emerging food-borne trematodiasis. *Emerg Infect Dis.* 2005;11(10):1507-14.
4. Ashrafi K. The status of human and animal fascioliasis in Iran: a narrative review article. *Iran J Parasitol.* 2015;10(3):306-28.
5. Mowlavi G, Mamishi S, Rokni MB, Mobedi I, Gharaguzlo MJ, Ashrafi K, et al. Neglected human fascioliasis case in a visceral leishmaniasis endemic area, North-Western Iran. *Iran J Public Health.* 2010;39(3):129-31.
6. Saberinasab M, Mohebbali M, Molawi G, Kia EB, Aryaeipour M, Rokni MB. Seroprevalence of human fascioliasis using indirect ELISA in Isfahan District, Central Iran in 2013. *Iran J Parasitol.* 2014;9(4):461-5.
7. Yılmaz B, Köklü S, Gedikoğlu G. Hepatic mass caused by *Fasciola hepatica*: a tricky differential diagnosis. *Am J Trop Med Hyg.* 2013;89(6):1212-3.
8. Ashrafi K, Valero MA, Massoud J, Sobhani A, Solaymani-Mohammadi S, Conde P, et al. Plant-borne human contamination by fascioliasis. *Am J Trop Med Hyg.* 2006;75(2):295-302.
9. Teke M, Önder H, Çiçek M, Hamidi C, Göya C, Çetinçakmak MG, et al. Sonographic findings of hepatobiliary fascioliasis accompanied by extrahepatic expansion and ectopic lesions. *J Ultrasound Med.* 2014;33(12):2105-11.
10. Aryaeipour M, Kia EB, Heidari Z, Sayyad Talaie Z, Rokni MB. Serological study of human fasciolosis in patients referring to the School of Public Health, Tehran University of Medical Sciences, Tehran, Iran during 2008-2014. *Iran J Parasitol.* 2015;10(4):517-22.
11. Oryan A, Mansourian M, Moazeni M, Nikahval B, Barband S. Liver distomatosis in cattle, sheep and goats of Northeastern Iran. *Glob Vet.* 2011;6(3):241-6.