

Images in Infectious Diseases

Giant peritoneal hydatid cyst causing pelvic venous congestion

Emine Izgi^[1] , Hayri Ogul^[2]  and Yener Aydin^[3] 

[1]. Medizinisches Versorgungszentrum Meine Radiologie Tuttlingen GmbH, Department of Radiology, Tuttlingen, Germany.

[2]. Duzce University, Medical Faculty, Department of Radiology, Duzce, Turkey.

[3]. Ataturk University, Medical Faculty, Department of Thoracic Surgery, Erzurum, Turkey.

A 53-year-old woman without a history of chronic disease was admitted to our hospital. On admission, the patient recounted a history of progressive abdominal distension and pelvic pain over the preceding 18 months. She had no history of systemic disease or abdominal trauma. On physical examination, a large, round abdominal mass was palpable. Abdominopelvic computed tomography revealed a giant peritoneal hydatid cyst and tortuous pelvic venous structures associated with compression by the peritoneal cyst (**Figure 1**).

A hydatid cyst is a parasitic disease caused by the larval form of *Echinococcus granulosus*¹. The liver is a vital organ that interacts with other organs^{1,2}. Peritoneal cysts, which are of a secondary origin, occur after the rupture of the primary hepatic hydatid cyst. A study has reported that peritoneal cysts develop in approximately 5–14% of patients with liver hydatid cysts³. Peritoneal hydatid cysts vary in number and can reach dimensions that cause abdominal distension or obstruction³. Pelvic venous congestion secondary to a giant peritoneal hydatid cyst is an unusual complication.

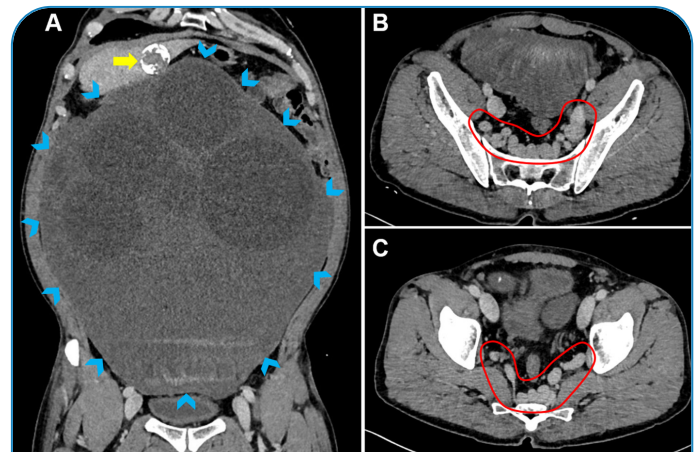


FIGURE 1: Coronal abdominal computed tomography (CT) scan (**A**) reveals a giant peritoneal hydatid cyst (arrowheads) and a calcified hepatic cyst (yellow arrow). Axial pelvic CT scans (**B and C**) reveal multiple dilated and tortuous pelvic venous structures (circle) in the presacral area.

REFERENCES

1. Aydin Y, Altuntas B, Kaya A, Ulas AB, Uyanik MH, Eroglu A. The Availability of Echinococcus IgG ELISA for Diagnosing Pulmonary Hydatid Cysts. *Eurasian J Med.* 2018;50(3):144-7.
2. Aydin Y, Ulas AB, Ince I, Korkut E, Ogul H, Eren S, et al. Large Case Series Analysis of Cystic Echinococcosis. *Indian J Surg.* 2021;83 (Suppl 4):S897-S906. Available from: <https://doi.org/10.1007/s12262-021-03061-0>.
3. Kosmidis C, Efthimiadis C, Anthimidis G, Vasileiadou K, Koimtzis G, Tzeveleki I, et al. Management of peritoneal hydatid cysts: A forty-year experience. *Heliyon.* 2018;4(12):e00994.

Corresponding author: Dr. Yener Aydin. **e-mail:** dryeneraydin@hotmail.com

Authors' contribution: EI: Conception and design of the study, Acquisition of data, Drafting the article, Final approval of the version to be submitted; HO: Conception and design of the study, Analysis and interpretation of data; YA: Conception and design of the study, Analysis and interpretation of data.

Conflict of Interest: The authors declared no conflicts of interest with respect to the authorship and/or publication of this article.

Financial Support: The authors declare that the article content was composed in the absence of any commercial or financial relationships that could be construed as a potential conflict of interest.

Received 26 July 2022 | **Accepted** 14 September 2022