



## Case Report/Relato de Caso

# Mediastinitis and pericardial effusion in a patient with AIDS and disseminated *Mycobacterium avium* infection: a case report

Mediastinite e derrame pericárdico em um paciente com AIDS e infecção disseminada por *Mycobacterium avium*: um relato de caso

Juan José Cortez-Escalante<sup>1</sup>, Aline Marques dos Santos<sup>2</sup>, Giovanna de Curcio Garnica<sup>2</sup>, Ana Lucia Sarmiento<sup>3</sup>, Cleudson Nery de Castro<sup>1</sup> and Gustavo Adolfo Sierra Romero<sup>1</sup>

### ABSTRACT

We report the case of a 36-year-old man who had acquired immune deficiency syndrome and developed suppurative mediastinitis extending over the left lung and anterior thoracic wall around the sternum, pericardial effusions, splenomegaly, and mesenteric and periaortic lymphadenomegaly due to *Mycobacterium avium* (genotype I). The organism was isolated from an axillary lymph node and the bone marrow. Mediastinitis associated with disseminated *M. avium* complex infection is uncommon and, to the best of our knowledge, this manifestation has not reported before.

**Keywords:** *Mycobacterium avium*. Pericarditis. Mediastinitis. AIDS. HIV.

### RESUMO

Relatamos o caso de um paciente de 36 anos vivendo com AIDS que desenvolveu mediastinite supurativa com extensão ao pulmão esquerdo e à parede anterior do tórax ao redor do esterno, derrame pericárdico, esplenomegalia e adenomegalia mesentérica e periaórtica, devido ao *Mycobacterium avium* genótipo I, isolado de linfonodo axilar e da medula óssea. A mediastinite associada à infecção pelo *Mycobacterium avium* é rara e, até onde conhecemos na literatura publicada, esta forma de apresentação ainda não foi relatada.

**Palavras-chaves:** *Mycobacterium avium*. Pericardite. Mediastinite. AIDS. HIV.

### INTRODUCTION

*Mycobacteria* are ubiquitous and important agents of opportunistic infections in patients with human immunodeficiency virus (HIV)/acquired immunodeficiency syndrome (AIDS). Non-tuberculous mycobacteria can produce severe disease such as disseminated disease. They have been recovered from surface and tap water, soil, domesticated and wild animals, milk, and food products<sup>1</sup>. They are not communicable from person to person and are often strikingly resistant to most available drugs. The *Mycobacterium avium* complex (MAC) involves the most common atypical mycobacteria to cause disease in HIV/AIDS patients with a low T-lymphocyte CD4+ count<sup>2,3</sup>. Mediastinitis and pericardial effusion in disseminated *Mycobacterium avium* complex (DMAC) infections are uncommon clinical features and, as far as we know from the published literature,

this manifestation has not been reported previously. The patient's identity was protected by excluding all personal data from this report, with the exception of age and sex data, and deleting his personal identification details from the radiological examination results, in agreement with the ethical principles for this kind of case report. All of the authors declare no conflicts of interest related to any matter associated with the present case report.

### CASE REPORT

A 36-year-old male with AIDS presented with 2 moderately swollen areas, i.e., in the suprasternal notch and the middle sternum area; mild odynophagia; fever; and weight loss of 1-month duration. Other symptoms included mild diarrhea, dyspnea, and decreased energy in the right upper and left lower limbs for the previous 2 months. Physical examination demonstrated tachypnea; pale mucosa; crackles on the base of the left lung; 2 painless and swollen areas with soft consistency, without erythema or heat; dullness of Traube's space; and right hemiparesis. The tuberculin skin test was non-reactive. A thoracic X-ray showed a chronic inflammatory lesion in the upper lobe of the left lung and moderate cardiac enlargement. Doppler echocardiography revealed a moderate pericardial effusion without cardiac tamponade or diastolic dysfunction. Chest computed tomography (CT) identified suppurative mediastinitis extending over the left lung and anterior thoracic wall, surrounding the sternum (**Figure 1A, B, C, and D**). Abdominal CT showed hepatomegaly and splenomegaly, with a 6-mm hypodense area. Mesenteric and periaortic lymphadenomegaly were also observed. Three cerebral white matter lesions localized in the right frontal, left parietal, and occipital lobes were detected on the axial T2 and T2 fluid attenuated inversion recovery-weighted magnetic resonance imaging (MRI) sequences; the post-contrast images demonstrated the ring-enhancing sign and surrounding vasogenic edema, suggesting toxoplasmic encephalitis. Laboratory tests showed negative sputum results for acid-fast bacilli and the following results: hemoglobin, 6.3g/dL; leukocytes, 5,400 cells/ $\mu$ L; platelets, 107,000 cells/ $\mu$ L; erythrocyte sedimentation rate, 85mm/h; and alkaline phosphatase, 854IU/L. The T-lymphocyte cell counts were as follows: CD4<sup>+</sup>, 12 cells/ $\mu$ L; CD8<sup>+</sup>, 115 cells/ $\mu$ L (CD4/CD8 = 0.10); the viral HIV load was above the superior limit of detection (>500,000 copies/ $\mu$ L). The results for anti-*Toxoplasma* immunoglobulin G (IgG) antibody were positive and those for IgM were negative. Cultures from peripheral blood, aspirates of purulent material from one of the swollen masses, and bronchoalveolar lavage samples were negative for pyogenic

1. Núcleo de Medicina Tropical, Universidade de Brasília, Brasília, DF. 2. Serviço de Doenças Infecciosas e Parasitárias, Hospital Universitário de Brasília, Universidade de Brasília, Brasília, DF. 3. Laboratório Central de Saúde Pública, Brasília, DF.

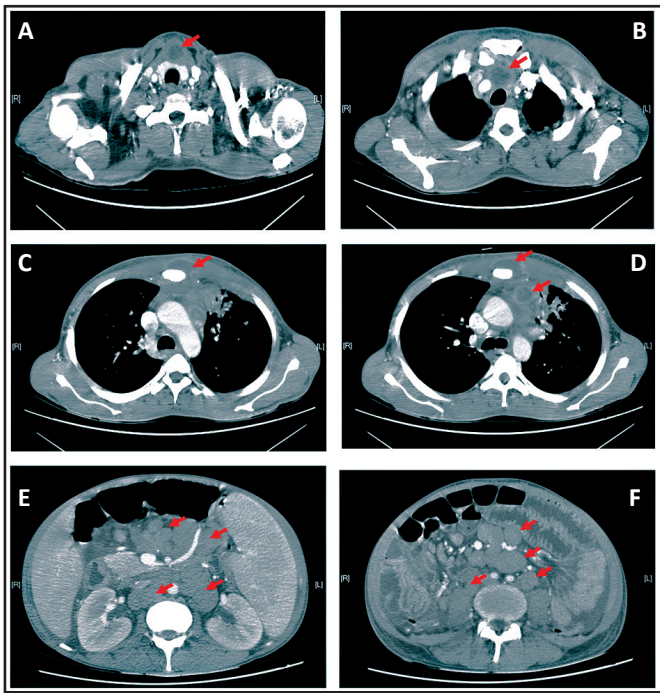
**Address to:** Dr. Gustavo Adolfo Sierra Romero. NMT/UnB. Caixa Postal 04517, Campus Universitário Darcy Ribeiro, Asa Norte, 70904-970 Brasília, DF, Brasil.

Phone: 55 61 3107-1043

e-mail: gromero@unb.br

**Received in** 16/07/2011

**Accepted in** 14/12/2011



**FIGURE 1** – Contrast-enhanced chest and abdominal computed tomography images. A, B, C, and D: Mediastinitis and chest wall abscess (red arrows) at the time of diagnosis. E and F: At 3 weeks before the patient's death, generalized abdominal lymph node enlargement (red arrows) was seen, and some of the lymph nodes had a diameter of 4 cm; significant splenomegaly was also seen.

bacteria, fungi, and mycobacteria. An axillary lymph node biopsy was performed, and the histopathology showed a diffuse granulomatous infiltrate with abundant acid-fast bacilli. One month later, the PCR-restriction enzyme analysis (PRA) method identified *M. avium* (genotype I) from an axillary lymph node biopsy and positive bone marrow aspiration cultures. Antimicrobial sensitivity testing was not performed.

Antiretroviral treatment was started with lamivudine, stavudine, and efavirenz. Sulfadiazine and pyrimethamine plus folinic acid were used against toxoplasmic encephalitis. Anti-tuberculous therapy was initiated with rifampin, isoniazid, and pyrazinamide after the initial histopathology findings. The patient developed toxic hepatitis with jaundice (total bilirubin: 7.62mg/dL; direct bilirubin: 5.2mg/dL; aspartate aminotransferase: 207IU/L; and alanine aminotransferase: 308IU/L). Therefore, overall therapy was suspended. Three weeks later, serum liver enzymes and bilirubin returned to baseline levels. At that time point, *M. avium* was identified and clarithromycin plus ethambutol and anti-retroviral and anti-*Toxoplasma* therapies were reintroduced. His neurological deficit improved with a significant reduction in cerebral lesions, as demonstrated in the MRI control image obtained in the sixth week of treatment. For the next 6 months, the patient improved with complete resolution of mediastinitis and pericardial effusion. No further invasive procedures were performed to confirm the etiology of the pericardial effusion. After this initial period, the patient began to lose weight; then, he underwent a medullar aspirate that revealed abundant acid-fast bacilli. Severe bowel obstruction with moderate ascites was observed 2 months later due to generalized abdominal lymph node enlargement (**Figure 1E and F**). Ciprofloxacin (500mg q12h) was added to the current therapy, obtaining mild clinical improvement. After 3 weeks, the patient died from multiple organ failure syndrome.

## DISCUSSION

DMAC infection in HIV/AIDS-patients could involve the pericardium and abdominal cavity<sup>3</sup>. However, mediastinal involvement has not been reported, neither as a part of the disseminated clinical form nor the isolated disease. *Cryptococcus neoformans*<sup>4</sup>, *Rhodococcus equi*<sup>5</sup>, and *Streptococcus pneumoniae*<sup>6</sup> have been identified as causes of mediastinitis in HIV/AIDS patients. Pericardial involvement in MAC infection has been reported. Pericardial effusion in HIV/AIDS patients is generally related to opportunistic infections or malignancy, but frequently, the cause is not identified<sup>7</sup>. Sometimes, this cardiac complication might represent a medical emergency, mainly when cardiac tamponade occurs, and may be a marker of end-stage HIV infection<sup>8</sup>. Fortunately, the pericardial effusion in our patient was moderate and did not exhibit this level of cardiac complication. Mesenteric or retroperitoneal lymph node enlargement and hepatosplenomegaly are common during MAC infection in patients with HIV/AIDS<sup>2</sup>. Our patient presented with all of these features, resulting in a significant intestinal obstruction. The physiopathological mechanisms of DMAC disease could explain the clinical presentation of our patient. We suspect that the mediastinal lymph nodes developed necrosis and drained to the mediastinum, involving neighboring organs such as the pericardium and lungs, and shortly after, the necrosis extended over the chest wall and resulted in 2 skin abscesses.

*M. tuberculosis* and MAC, often presents with the same clinical features in severely immunodeficient HIV patients<sup>2,3</sup>. Considering that *M. tuberculosis* disease is a relevant public health problem in developing countries with a high incidence, the first presumptive diagnosis was tuberculosis before the identification of *Mycobacterium* species. The diagnosis of a DMAC infection is usually achieved through isolation from blood culture, and the species is identified rapidly by species-specific molecular probes. If blood cultures fail to grow the mycobacteria, lymph node, bone marrow, or liver biopsies are helpful to establish the diagnosis<sup>2</sup>. Then, after a favorable clinical response with anti-MAC therapy, repeated negative cultures for fungi and pyogenic microorganisms from overall samples, and PRA analysis, we concluded that our patient had a very rare manifestation of DMAC disease.

Highly active antiretroviral therapy (HAART) and chemoprophylaxis have changed the natural course of MAC infection in patients with HIV/AIDS, with an important reduction of its incidence and survival improvement in patients with severe immunodeficiency<sup>3</sup>. However, patients without adequate adherence to HAART continue to be at risk for DMAC. In the present case, HAART plus specific MAC treatment showed some positive effects during the first few months, with the disappearance of mediastinitis, chest wall abscesses, and pericardial effusion. Thereafter, the patient's condition worsened and he died. Therapeutic failure could be due to either a reduced adherence to therapy or possible MAC resistance. Nowadays, impaired tolerance to the multi-drug regimens against MAC microorganisms in patients with HIV/AIDS is usually due to gastrointestinal intolerance and drug toxicity, besides other concomitant drug regimens. MAC resistance has been reported in ~13% of patients treated with long-term standard clarithromycin-based regimens due to non-compliance with MAC therapy, with a median time to treatment failure of 7 months<sup>9</sup>. In addition, there appears to be impaired drug absorption of some of the oral drugs

used in MAC therapy in HIV patients, even without gastrointestinal manifestations<sup>10</sup>. Overall, in this setting, the efficacy of the therapy was hampered probably by a combination of the patient's severe immunodeficiency and the impaired drug absorption. Unfortunately, the cause of death could not be attributed definitively to DMAC because acid-fast bacilli from the bone marrow were not isolated and submitted for species identification. However, DMAC is the more plausible cause of death in this patient. In conclusion, this case illustrates a very unusual clinical presentation of DMAC disease with mediastinal, pericardial, and chest wall involvement.

## FINANCIAL SUPPORT

Juan José Cortez-Escalante was a Ph.D. student and Aline Marques dos Santos was an undergraduate student, both with scholarships from the National Council for Scientific and Technological Development (CNPq) of the Ministry of Science and Technology (MCT), Brazil.

## REFERENCES

1. Gruft H, Falkinham JO, Parker BC. Recent experience in the epidemiology of disease caused by atypical mycobacteria. *Rev Infect Dis* 1981; 3:990-996.
2. MacGregor RR, Hafner R, Wu JW, Murphy RL, Perlman DC, Bermudez LE, et al. Clinical, microbiological, and immunological characteristics in HIV-infected subjects at risk for disseminated *Mycobacterium avium* complex disease: an AACTG study. *AIDS Res Hum Retroviruses* 2005; 21:689-695.
3. Karakousis PC, Moore RD, Chaisson RE. *Mycobacterium avium* complex in patients with HIV infection in the era of highly active antiretroviral therapy. *Lancet Infect Dis* 2004; 4:557-565.
4. Trevenzoli M, Cattelan AM, Rea F, Sasset L, Semisa M, Lanzafame M, et al. Mediastinitis due to cryptococcal infection: a new clinical entity in the HAART era. *J Infect* 2002; 45:173-179.
5. Casado JL, Antela A, Sanchez JA, Hermida JM, Meseguer M. Acute mediastinitis due to *Rhodococcus equi* in a patient with human immunodeficiency virus infection. *Eur J Clin Microbiol Infect Dis* 1997; 16:241-244.
6. Rodriguez-Barradas MC, Musher DM, Hamill RJ, Dowell M, Bagwell JT, Sanders CV. Unusual manifestations of pneumococcal infection in human immunodeficiency virus-infected individuals: the past revisited. *Clin Infect Dis* 1992; 14:192-199.
7. Chen Y, Brennessel D, Walters J, Johnson M, Rosner F, Raza M. Human immunodeficiency virus-associated pericardial effusion: report of 40 cases and review of the literature. *Am Heart J* 1999; 137:516-521.
8. Barbaro G, Fisher SD, Giancaspro G, Lipshultz SE. HIV-associated cardiovascular complications: a new challenge for emergency physicians. *Am J Emerg Med* 2001; 19:566-574.
9. Burman WJ, Stone BL, Rietmeijer CA, Maslow J, Cohn DL, Reves RR. Long-term outcomes of treatment of *Mycobacterium avium* complex bacteremia using a clarithromycin-containing regimen. *AIDS* 1998; 12:1309-1315.
10. Gordon SM, Horsburgh Jr CR, Peloquin CA, Havlik Jr JA, Metchock B, Heifets L, et al. Low serum levels of oral antimycobacterial agents in patients with disseminated *Mycobacterium avium* complex disease. *J Infect Dis* 1993; 168:1559-1562.