

Images in Infectious Diseases

Spontaneous healing of a ruptured pulmonary hydatid cyst: a rare phenomenon

Yener Aydin^[1] , Omer Araz^[2]  and Atilla Eroglu^[1] 

[1]. Ataturk University, Medical Faculty, Department of Thoracic Surgery, Erzurum, Turkey.

[2]. Ataturk University, Medical Faculty, Department of Pulmonary Diseases, Erzurum, Turkey.

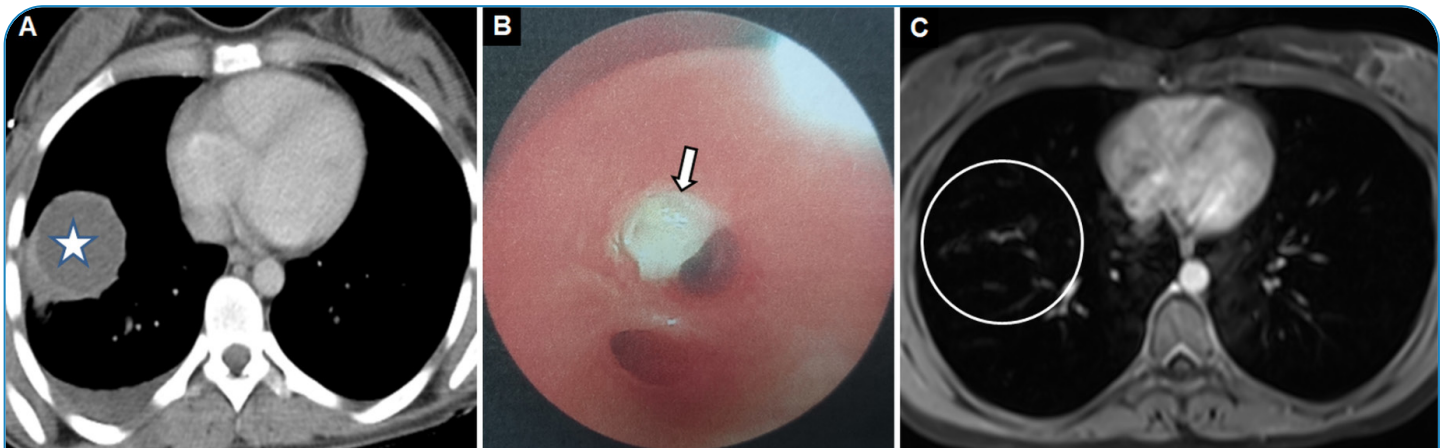


FIGURE 1: Axial computed tomography scans showing a hydatid cyst of 45-mm diameter with a unilocular water-dense lesion (indicated with star) and pleural effusion (A). Flexible bronchoscopy findings showing a membrane (arrow) originating from the hydatid cyst in the anterior basal segment of the right lower lobe (B). Control axial T2-weighted magnetic resonance image (circle) showing spontaneous healing of the hydatid cyst 3 months later (C).

A 28-year-old female patient presented to our hospital with cough, fever, and a salty, watery expectoration. She was diagnosed with a pulmonary hydatid cyst based on thorax computed tomography and flexible bronchoscopy findings. Surgical treatment of the hydatid cyst was recommended for the patient. However, the patient did not consent to undergo surgery and medical treatment until 3 months later. Follow-up examinations revealed that the hydatid cyst cavity had completely healed (Figure 1).

The lung is the second most common organ in which hydatid cysts are seen. Although a hydatid cyst is a benign lesion, it can lead to asphyxia and anaphylaxis when the cyst is ruptured. Moreover, the cyst cavity is often infected during the bronchial or pleural rupture of hydatid cysts^{1,2}. Therefore, surgical treatment is indicated

after the diagnosis³. As seen in the present case, spontaneous healing of a ruptured hydatid cyst rarely occurs.

REFERENCES

1. Aydin Y, Ulas AB, Ince I, Korkut E, Ogul H, Eren S, et al. Large Case Series Analysis of Cystic Echinococcosis. *Indian J Surg.* 2021;83(Suppl 4):S897-S906. Available from: <https://doi.org/10.1007/s12262-021-03061-0>
2. Aydin Y, Altuntas B, Kaya A, Ulas AB, Uyanik MH, Eroglu A. The Availability of Echinococcus IgG ELISA for Diagnosing Pulmonary Hydatid Cysts. *Eurasian J Med.* 2018;50(3):144-7.
3. Aydin Y, Ulas AB, Ince I, Kalin A, Can FK, Gundogdu B, et al. Evaluation of albendazole efficiency and complications in patients with pulmonary hydatid cyst. *Interact Cardiovasc Thorac Surg.* 2022;34(2):245-9.

Corresponding author: Dr. Yener Aydin. **e-mail:** dryeneraydin@hotmail.com

Authors' contribution: YA: Conception and design of the study, Acquisition of data, Drafting the article, Final approval of the version to be submitted; OA: Conception and design of the study, Analysis and interpretation of data; AE: Conception and design of the study, Analysis and interpretation of data.

Conflict of Interest: The authors declare that there is no conflict of interest.

Financial Support: The authors declare that the article content was composed in the absence of any commercial or financial relationships that could be construed as a potential conflict of interest.

Received 8 April 2022 - **Accepted** 19 May 2022