

Manoel João Batista Castello Girão, Marair Gracio Ferreira Sartori,
Wagner José Gonçalves, Geraldo Rodrigues de Lima

Peritoneal borderline cystadenocarcinoma

Department of Gynecology of Escola Paulista de Medicina - Universidade Federal de São Paulo - São Paulo, Brazil

Carcinomas of peritoneal origin represent a seldom diagnosed entity of unknown etiology, with important implications in terms of prophylactic oophorectomy. Initially described in patients belonging to families at high risk for ovarian cancer, it possibly has a pathogeny similar to that of endosalpingiosis and of some cases of endometriosis. We report a case of peritoneal borderline mucinous carcinoma with an anatomopathological diagnosis of normal ovaries.

UNITERMS: Peritoneum. Peritoneal carcinoma. Peritoneal adenocarcinoma.

INTRODUCTION

Reports of peritoneal tumors histologically similar to ovarian carcinoma have been published over the last few years, usually relating to patients with previous oophorectomy and with high familial risk.

Several investigators have reported cases of peritoneal carcinoma in patients whose families are at high risk for ovarian cancer, who had been submitted to prophylactic oophorectomy ⁽¹⁾. This fact appears to demonstrate that in these families gonadal exeresis may not provide total protection against ovarian cancer.

Since serous ovarian carcinomas are usually disseminated in the peritoneal cavity at the time of diagnosis, a hypothesis of multifocal rather than metastatic

origin may be proposed for these neoplasias. This possibility may justify the slight involvement of the ovaries observed in some cases, where extensive peritoneal involvement has already occurred.

The pathogeny is probably similar to that of endosalpingiosis and to some cases of endometriosis, possibly involving processes of peritoneal metaplasia and hyperplasia similar to the precursor alterations detected in the surface epithelium of the ovary. Gene instability may arise as a consequence of these processes, or its intensity may be directly related to the extent of hyperplasia. The pelvic peritoneum may apparently have a great capacity for transformation into several mullerian epithelia, especially into tubal and endometrial types ⁽²⁾.

CASE REPORT

A 51-year old white woman sought the Department of Gynecology at Escola Paulista de Medicina

Address for correspondence:

Manoel João Batista Castello Girão
Av. Onze de Junho, 1006, ap. 51
São Paulo/SP - Brasil - CEP 04041-003

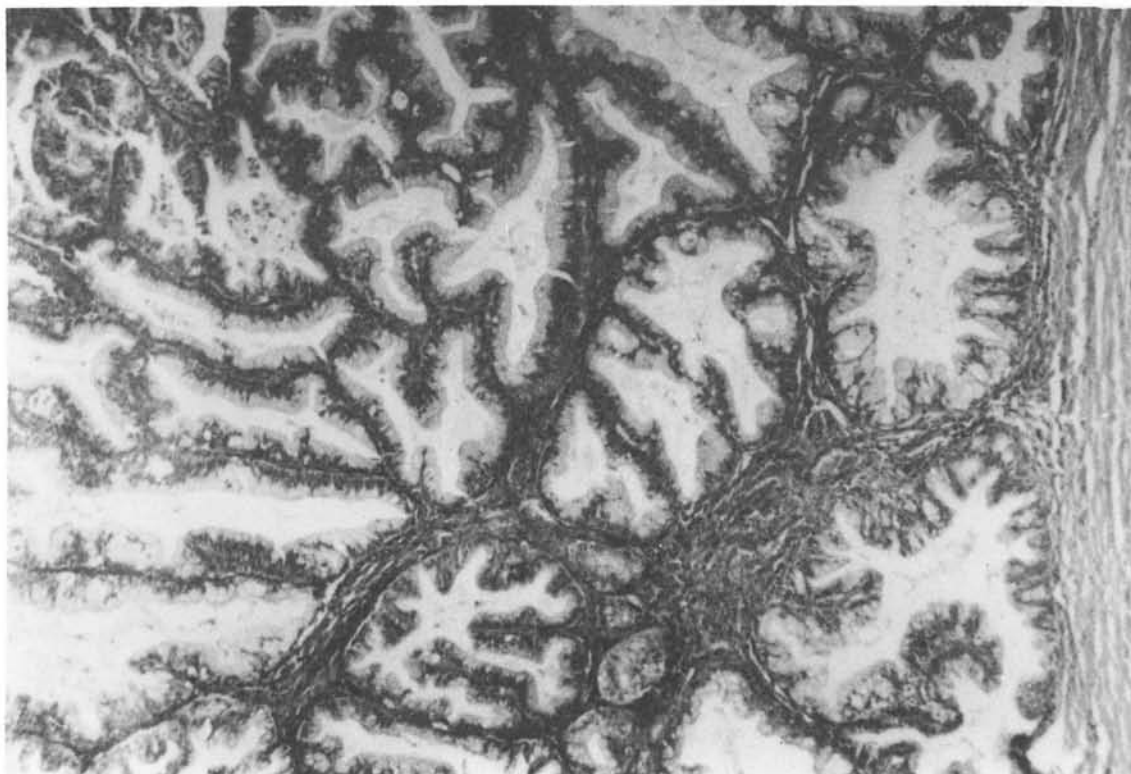

Figure 1a - The epithelium demonstrates multilayering, nuclear abnormalities and increased mitotic activity; (hematoxylin-eosin, X 160)

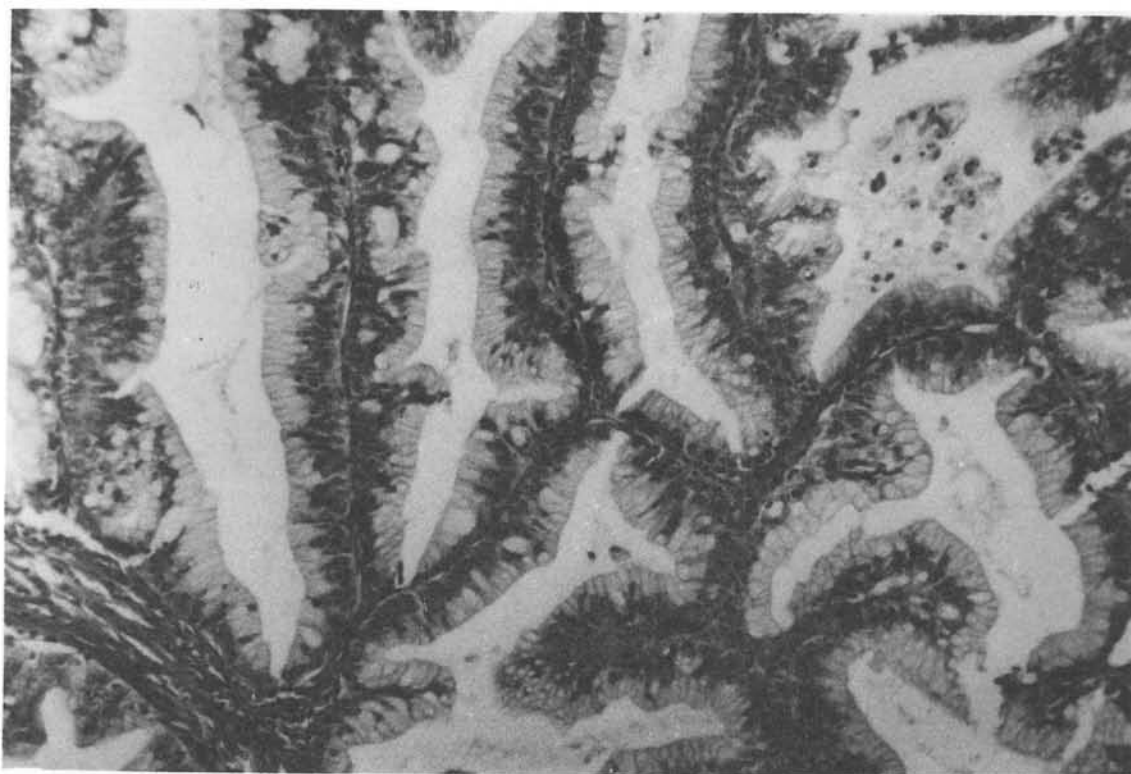


Figure 1b - The epithelium demonstrates multilayering, nuclear abnormalities and increased mitotic activity; (hematoxylin-eosin, X 390)

complaining of having had progressive swelling of the abdomen during the preceding 2 years, accompanied by cramp pain irradiating toward the dorsal region, and retrosternal pyrosis. She denied having epidemiological risk factors for malignant genital neoplasias.

Physical examination revealed a body mass index of 27.8, as well as a tumor of precise limits, elastic consistency, smooth surface, and little mobility, occupying the mesogastrium and hypogastrium; it measured approximately 16 x 20 mm.

Abdominal ultrasound revealed a predominantly cystic formation of regular limits and with a small internal solid area. The uterus was normal and the ovaries were not identified.

At laparotomy, a voluminous cystic tumor originating from the retroperitoneum and measuring approximately 20 mm in diameter was seen. The uterus and ovaries were normal, as well as the rest of the abdominal cavity. Tumor exeresis and bilateral oophorectomy were performed.

Anatomopathological examination of the tumor revealed the presence of a peritoneal mucinous borderline cystoadenocarcinoma, with atrophic ovaries.

DISCUSSION AND CONCLUSIONS

Little is known about the possible etiological and predisposing factors involved, making prevention extremely difficult. However, extraovarian peritoneal carcinoma behaves like its gonadal counterpart, ranging from benign and borderline to frankly malignant varieties. The prognosis is similar to ovarian carcinomas and the response to chemotherapy is estimated at 63%⁽³⁾.

It should be pointed out that the incidence of the borderline form tends to be higher among young women and that this form frequently has psammomatose bodies. The borderline form accounts for 8 to 15% of the lesions diagnosed in stages III and IV.

This type of neoplasia may possibly be observed with greater frequency in the future, as pathologists start to recognize it and establish better diagnostic criteria.

ACKNOWLEDGMENTS

We thank L.C. Granero, MD, PhD and F.M. Callegari, MD, Division of Pathology, Escola Paulista de Medicina, for the pathological analysis of the material.

RESUMO

O carcinoma de peritônio é raro, de etiologia desconhecida, tendo grande importância quando se discute a ooforectomia profilática como prevenção do carcinoma de ovário.

Foi inicialmente descrito em pacientes de famílias de alto risco para carcinoma de ovário, o que possibilita haver patogenia semelhante àquela observada em endossalpingiose ou alguns casos de endometriose.

Relata-se, no presente estudo, caso de carcinoma mucinoso "borderline" de peritônio, com exame histopatológico mostrando ovários normais.

REFERENCES

1. Piver MS, Jishi MF, Tsukada Y, Nava G. Primary Peritoneal carcinoma after prophylactic oophorectomy in women with a family history of ovarian cancer: a report of a Gilda Radner familial ovarian cancer registry. *Cancer* 1993;71(9):2751.
2. Morrow CP, Curtin JP, Townsend DE. *Synopsis Gynecologic Oncology*. 4th ed., New York, Churchill Livingstone 1993;209.
3. Disaia PJ, Creasman WT. *Clinical Gynecology Oncology*. 4th ed., St. Louis, Mosby Year Book 1993;458.