

## Angyomatous vocal polypus - A complete spontaneous regression

Otorhinolaryngology Course, Jundiaí College of Medicine - São Paulo, Brazil

The authors describe a male patient who had malignant lymphoma seven years ago which remitted with chemotherapy. Two years ago he developed dysphonia. An unilateral, pediculate smooth red lesion on the right vocal fold was later discovered. Even without benefit of medicamentous treatment, the patient refused surgery. In a reevaluation using rigid telescropy of the larynx two years later, the lesion had disappeared, completely and spontaneously. As there are no existing publications on this topic, this case report is an alert that surgery should be recommended with extreme caution in this type of vocal disease.

**UNITERMS:** Larynx. Polipus.

### INTRODUCTION

Vocal cords polyps are the most frequent benign larynx alterations which affect phonation, and rarely occur in children. Up to 75 to 80 percent of all patients with vocal cords polyps are males, and the polyps are 90 percent single and 10 percent bilateral or multiple unilateral. They occur chiefly on the vocal cord free edge, at the junction of the anterior third with the posterior two-thirds. The pathogenesis of the vocal polypus is not well-known. Since it is not a true tumor, the terms vocal fibroma and mixoma are inadequate. Its inflammatory origin is also very much discussed. Rarely are there signs of recent or old inflammation, even on a histological exam. Many of these patients overuse their voices routinely due to professional necessity. Some vocal

polyps arise from powerful, intense and unusual physical activity, which cause subglottic increased pressure followed by a sudden decrease.<sup>1</sup>

Vocal polyps are sometimes accompanied by varicosities; mainly in those cases caused by vocal abuse in voice professionals with no vocal training, more commonly in teachers.

The size, origin, color and consistence of polyps are extremely variable. The lesion is usually a round mass, mono- or multilobulated, and rarely ulcerated. Small polyps have a large base; and the bigger they are, the narrower is their base, causing confusion with Reinke's edema.<sup>1</sup> The major symptoms of vocal polyps are hoarseness and diplophonia (bitonal voice); dyspnea rarely occurs. The polypus are classified histologically as:

1. Gelatinous or Gallert's polypus - when it has little connective tissue, thin fibers, some capillary vessels, thin pavementous epithelium and many mucous gelatinous masses. It is a non-pediculated polyp, with a translucent aspect. Rarely is there thick, fibrous connective tissue; a sign of an aging polyp nucleus. Only 5 percent of the polyps have a macroscopic

**Address for correspondence:**

Edmir Américo Lourenço  
Rua do Retiro, 424 - 5º andar, conj. 53/54 - Anhangabaú  
Jundiaí /SP - Brasil - CEP 13209-000

keratinized cover. There are no nuclear atypias or other intense epithelium dysplasias. The polyp epithelium rarely shows discrete hyperplasia or acanthosis.

2. Fibrous - with a connective-tissue core rich in cells and fibers. It may be richly vascularized and hyalinized.

3. Telangiectasic - its core is composed of cavernous, coiled blood vessels, with variable diameters and thin walls. Some of these caverns may become trombosed and hyalinized. Around the polypus there are often older microscopic hemorrhages at the level of the submucosa, which look like yellow-red belts. This kind of polypus has a red-gray or dark red appearance, sometimes with a hemangiomatous aspect.

Among these three histological types there are some transitional forms, according to the age of the lesion. If aging results in a corneal cover, the polypus is always covered by a smooth and non-ulcerated mucosa. The treatment is surgical, with easy removal after finding its insertion.<sup>1</sup>

## CASE REPORT

Two years ago, a 54-year-old male banker came to us with dysphonic complaints that had begun one week before. One month prior to this, he had had dry coughing spells. There was no vocal abuse, acute vocal trauma, or intense physical effort. He did not smoke, and drank occasionally.

Seven years earlier, at age 47, he had had diffuse, non-clived, large-cell malignant lymphoma. At the onset there was high respiratory obstruction, due to a hard, voluminous, pediculated mass on the left side of the hypopharynx. Its implantation extended from the left tonsillar base to the homolateral vaeclula. The tonsil and the mass were submitted to extirpation under general anesthesia, followed by chemotherapy for four months. There was a complete regression of the disease, and up until this present complaint, the patient had been under oncological control.

Under a direct larynx exam with a flexible optical fibroscopy, there was a unilateral, pediculated smooth red lesion of the right vocal fold, macroscopically typical of an angiomatous polyp (Fig. 1). The patient was told that it was a benign pathology, and was treated with topical corticosteroid therapy with beclometasone for seven days, in addition to an antihistaminic drug with anticough agent and decongestant. Since this was not successful, surgical removal by microsurgery was recommended. The patient refused surgery, explaining that he had already gone

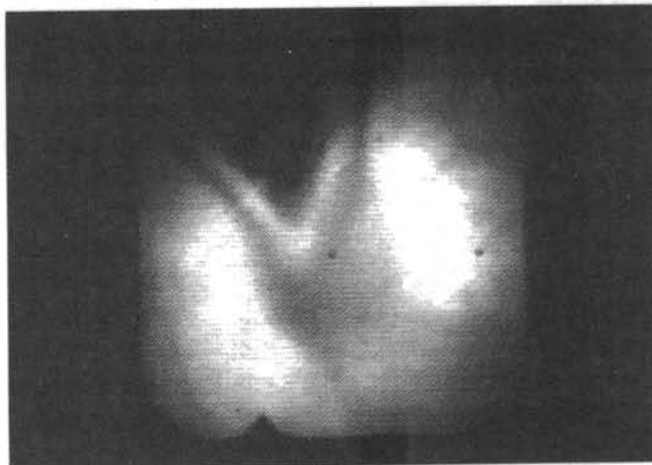


Figure 1 - Larynx fibroscopic image showing unilateral pediculated lesion of the right fold.

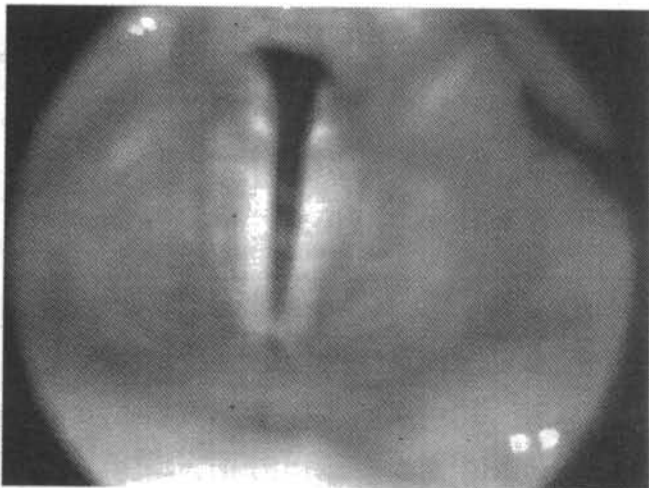
through a serious health problem, and preferred to live with this vocal polypus, as he did not use his voice professionally. He was reexamined recently, two years after the vocal angyoma diagnosis, because of dry coughing complaints. He underwent indirect laryngoscopy followed by larynx telescopy, using a rigid telescope 10 millimeters in diameter, Machida, model LY-C 30. There was no lesion at vocal fold (Figs. 2 and 3). The patient reported a progressive decrease of dysphonia, during the following year, and received phoniatic treatment and/or additional medications during this period.

## HISTOLOGICAL FINDINGS

Microscopically, the vocal nodules have varying patterns depending on their evolutionary stage, but the

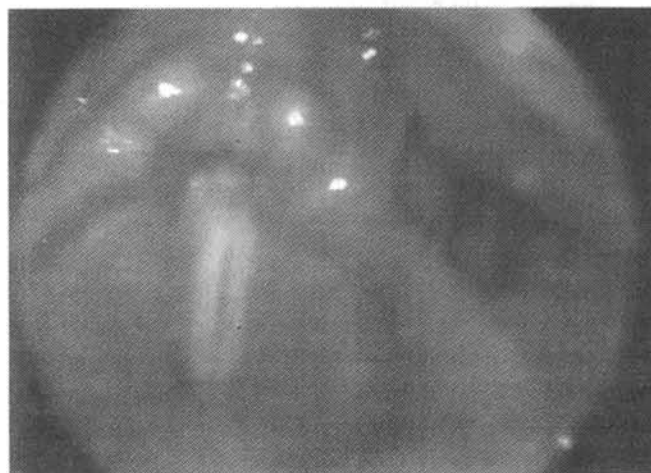

Figure 2 - Larynx rigid telescopy under phonation shows no lesions.



**Figure 3** - Larynx rigid telescope under inspiration shows no lesions.

main histological changes occur in the corium. These are multiple changes, and the predominance of specific change, plus the age of the lesion, explains endoscopic polymorphism. In the early stages, they show edema and proliferation of young fibroblasts.<sup>2</sup>

The constant edema may be accompanied by fibrin exudation or hemorrhage. Inflammatory infiltration may sometimes occur, but remains discrete.<sup>3</sup>

Later, dilated blood vessels and hyalinization of the stroma<sup>2</sup> and more or less marked fibrosis appear.<sup>3</sup> The lesions that show an exuberant vascular component are frequently mistaken for hemangioma.<sup>2</sup> Since these anomalies are lacunae, they may give rise to thrombosis.<sup>3</sup> The hyaline stage was the previously designated "amyloid tumor," a misnomer, because the material is hyalinized collagen rather than amyloid, and sometimes accompanied by amyloid deposits.<sup>2</sup>

The epithelium is generally normal, or sometimes thinned or ulcerated. In the course of development, the epithelium sometimes becomes hyperplastic, and may show a variable degree of acanthosis and keratosis. This is why pathologists often confuse polyps and nodules.<sup>3</sup>

A lesion known as posterior commissure ulcer, or contact (granulomatous) ulcer, is sometimes erroneously thought to be laryngeal nodule, but actually has a different presentation, histology and behavior. As the first name implies, the lesion is almost always found at the level of the posterior commissure, in the area of the vocal process

of the arytenoid cartilage, at a site where the amount of subepithelial stroma is lesser. Microscopically, it has the appearance of exuberant granulation tissue, and it is often confused with pyogenic granuloma, but lacks the characteristic lobular pattern of the latter. It stubbornly recurs following local excision, but eventually subsides. Conservative management is recommended.<sup>2</sup>

## DISCUSSION

The angiomatous vocal polypus is a relatively common lesion in laryngological practice. Its diagnosis was made easier by the development of flexible and rigid optical apparatus, which have not replaced the indirect laryngoscopy, basic, panoramic and routine semiological exam. After diagnosis by any method, the usual management is microsurgery, and some authors have recently developed new techniques for ambulatorial lesion extirpation with topical anesthesia. The bibliography makes reference to a 15-year-old pregnant patient with multiple vaginal polyps. These lesions had spontaneously regressed six weeks after the birth, and although benign, were microscopically mistaken for botryoides sarcoma.<sup>4</sup>

Surprised by the spontaneous regression of this lesion, with no similar bibliographic citations, the authors make this communication an alert. Angiomatous vocal polypus spontaneous regression possibly occurs with greater probability in new cases with no previous vocal function complaints. Macroscopically benign lesions like this should be carefully observed before surgery is recommended, in order to avoid unnecessary interventions. This is a suggested new routine in the management of these lesions.

## CONCLUSION

Physicians should be alerted to the fact that surgical recommendations must be more accurate and cautious in benign pathologies.

## RESUMO

Os autores descrevem um paciente do sexo masculino, que há sete anos teve um linfoma maligno, com remissão por meio de quimioterapia. Há dois anos desenvolveu disfonia, sendo detectada uma lesão pediculada lisa avermelhada na prega vocal direita. Mesmo sem benefício com tratamento medicamentoso, o paciente não aceitou o tratamento cirúrgico e numa reavaliação laringoscópica após dois anos, através de telescopia rígida, o pólipo havia desaparecido. Devido à inexistência de publicações sobre o tema na literatura médica pesquisada, este comunicado é um alerta, no sentido de que a indicação cirúrgica seja cautelosa e criteriosa neste tipo de doença vocal

## REFERENCES

1. Kleinsasser O. Microlaringoscopia e microcirurgia da laringe, 2a ed. São Paulo: Ed. Manole, 1977:87-95.
2. Rosai, J. Surgical Pathology. 7th ed. The C. V. Mosby Company, 1989;(1):247-8.
3. Lehmann W, Pidoux JM, Widmann JJ. Larynx Microlaryngoscopy and Histopathology. Switzerland: Inpharzam Medical Publications, 1981; 68-9.
4. Tobon H, McIntyre-Seltman K, Rubino M. Polyposis vaginalis of pregnancy. Arch Pathol Lab Med 1989;113(12):1391-3.