

Neuropsychological assessment before and after radiotherapy in a child with an intracranial tumor: case report

Avaliação neuropsicológica antes e após radioterapia em uma criança com tumor intracraniano: relato de caso

Alessandra Pereira Lopes,¹ Alina Lebreiro Teldeschi,² Flávia Miele,² Cíntia Mesquita,³ Manuela Corrêa Borges,³ Gabriel Coutinho,¹ Paulo Mattos¹

Abstract

Introduction: Brain tumors are the most common solid tumors and the second largest group of neoplasms diagnosed in childhood. Treatment includes surgery, radiotherapy, and chemotherapy. However, radiotherapy can cause complications, e.g., cognitive deficits.

Case description: We describe the case of a child diagnosed with a brain tumor evaluated before and after radiotherapy to investigate cognitive decline after treatment. The results showed a decline in Intelligence Quotient (IQ) scores and reversal of the predominance of verbal and nonverbal skills. After radiotherapy, the subject showed slowness, academic deficits, and difficulties learning new information.

Comments: Even though the post-treatment evaluation showed scores compatible with the average, comparison between pre- and post-treatment evaluations demonstrated the impact of radiotherapy on the subject's cognitive profile. These results highlight the importance of evaluating patients who undergo radiotherapy before and after treatment and understanding neuropsychological scores associated with the subjects' complaints.

Keywords: Radiotherapy, neuropsychology, case study, medulloblastoma.

Resumo

Introdução: Tumores cerebrais são os tumores sólidos mais comuns e o segundo maior grupo de neoplasias diagnosticadas na infância. O tratamento inclui cirurgia, radioterapia e quimioterapia. No entanto, a radioterapia pode causar complicações, como, por exemplo, déficits cognitivos.

Descrição do caso: Descrevemos o caso de uma criança diagnosticada com tumor cerebral e avaliada antes e após tratamento com radioterapia para investigar declínio cognitivo pós-tratamento. Os resultados demonstraram um declínio nos escores de Quociente de Inteligência (QI) e uma reversão da predominância em habilidades verbais e não verbais. Após a radioterapia, o sujeito demonstrou lentidão, déficits acadêmicos e dificuldade para aprender novas informações.

Comentário: Embora a avaliação pós-tratamento tenha mostrado escores compatíveis com a média, a comparação entre as avaliações pré e pós-tratamento evidenciaram o impacto da radioterapia sobre o perfil cognitivo do paciente. Esses resultados salientam a importância de avaliar pacientes tratados com radioterapia antes e após o tratamento e de entender os escores neuropsicológicos associados às queixas dos pacientes.

Descritores: Radioterapia, neuropsicologia, estudo de caso, meduloblastoma.

¹ Centro de Neuropsicologia Aplicada, Instituto D'Or de Pesquisa e Ensino (CNA/IDOR), Rio de Janeiro, RJ, Brazil. Universidade Federal do Rio de Janeiro (UFRJ), Rio de Janeiro, RJ, Brazil. ² CNA/IDOR, Rio de Janeiro, RJ, Brazil. ³ Psychologist, private practice.

Financial support: none.

Submitted Jun 07 2013, accepted for publication Aug 12 2013. No conflicts of interest declared concerning the publication of this article.

Suggested citation: Lopes AP, Teldeschi AL, Miele F, Mesquita C, Borges MC, Coutinho G, et al. Neuropsychological assessment before and after radiotherapy in a child with an intracranial tumor: case report. Trends Psychiatry Psychother. 2013;35(4):299-303. <http://dx.doi.org/10.1590/2237-6089-2013-0023>

Introduction

Cancer is a relatively rare disease in childhood, affecting approximately 10 in 100,000 children/year. Brain tumors are the most common solid tumors and the second largest group of neoplasms diagnosed in childhood.¹ In the U.S., brain tumors account for 20% of childhood cancers.² In Brazil, childhood brain tumors reach their highest incidence in the 10-15-year age group, with a higher incidence among males,^{3,4} similarly to other findings reported worldwide.

Intracranial brain tumors are classified according to anatomic location, symptoms, and clinical signs.¹ Treatment may involve surgery, radiotherapy, chemotherapy, or a combination of these therapies. Treatment effectiveness has contributed to increasing the rates of remission in childhood cancer.^{4,5}

Several studies have investigated quality of life, biopsychosocial implications, and other late effects of cancer treatments.⁶ Children treated with the aforementioned modalities who survive cancer may present cardiopulmonary, renal, gastrointestinal, endocrine, musculoskeletal, and cognitive problems⁵, especially at younger ages.⁷⁻⁹ Cognitive decline can manifest immediately after radiotherapy or progress over time.¹⁰

Specifically, radiotherapy may be associated with cognitive sequelae primarily associated with white matter lesions.⁵ The white matter is responsible for transmitting information among different brain areas.^{11,6} Cognitive slowing, memory and global deficits (e.g., reduced Intelligence Quotient [IQ]),^{7,10} and academic difficulties are commonly observed after radiation treatments.¹² Additionally, the risk of attentional, motor, and nonverbal deficits is present.^{2,5,8,9}

Cognitive deficits as a consequence of radiotherapy may vary depending on tumor location and histology, radiotherapy type and dosage (a higher radiation dosage is expected to generate more deficits), age at diagnosis and treatment,¹¹ time since diagnosis, preoperative complications, and presence of hydrocephalus and shunts.⁵

The present report describes the case of a 6-year-old male individual diagnosed with a brain tumor and evaluated before and after radiotherapy to investigate cognitive decline.

Case description

The patient's parents signed an informed consent form and agreed to have his case described and published.

Pre-radiotherapy assessment

A 6-year-old male patient was referred to our service for neuropsychological evaluation before starting radiotherapy

for brain cancer. Prior to this first assessment, he had undergone surgery to correct congenital squinting and remove a posterior fossa medulloblastoma located by the 4th ventricle. The symptoms that first appeared were headaches and projectile vomiting. At the time of evaluation, the patient was taking anticoagulants and weaning corticoids.

The evaluation included the following cognitive functions: visual and auditory-verbal attention, visuo-perceptual and visuoconstructive abilities, visuo-motor dexterity, global cognitive ability, memory, verbal abstraction, oral and written language, and calculation skills.

The patient's global cognitive ability, assessed by the Wechsler Intelligence Scale for Children, 3rd Edition (WISC-III),¹³ was within normal ranges, with a high-average classification. Significant discrepancies were found for verbal vs. nonverbal performance, with superior nonverbal skills. Perceptual organization was rated higher than expected for his age. The WISC-III resistance distraction index,¹³ largely associated with auditory-verbal working memory and language skills, was within normal ranges. Calculation capacity, assessed by the arithmetic subtest,¹³ was normal. Visuoconstructive ability was within the very high range. Some WISC-III subtests,¹³ e.g., the symbol search (visuo-motor task), comprehension (social judgment task), and mazes (planning task), could not be performed because the radiotherapy sessions began and the patient's parents decided to skip evaluation.

Visual attention, assessed by the Test of Visual Attention (TAVIS-3),¹⁴ showed a lower than expected degree of selective attention and normal sustained attention.

The phonological loop, central executive, and visuospatial sketchpad, assessed by the WISC-III digit span subtest¹³ and Finger Windows,¹⁵ were normal, suggesting preservation of specific aspects of working memory.¹⁶ Language assessment revealed language processing, both oral and written, within normal limits.

In sum, the results of the pre-radiotherapy neuropsychological assessment suggested cognitive ability within normal limits for the patient's age. The discrepancy found for verbal vs. nonverbal skills did not appear to have a negative impact on the patient's life. No diagnosis was made of a psychiatric disorder based on the Diagnostic and Statistical Manual of Mental Disorders, 4th edition (DSM-IV).¹⁷

Post-radiotherapy assessment

The patient was 11 years old and returned for neuropsychological reassessment to investigate possible cognitive decline secondary to treatment.

The patient was experiencing academic failure and was receiving pedagogical support. His parents reported mild hearing impairment and endocrine disruption, possibly

associated with radiotherapy.⁵ The patient was taking the thyroid hormone levothyroxine.

The same instruments applied at baseline were used to evaluate the same functions. In this second evaluation, global cognitive ability was within the limits of standard group variations, with an average rating. Verbal IQ was superior to nonverbal IQ, within average and low-average ranges, respectively, indicating a significant discrepancy between verbal skills and performance but revealing a profile that was opposite to that observed in the first assessment. Processing speed, perceptual organization, resistance to distraction, and verbal comprehension indices were within the average range. Calculation capacity remained normal for the patient's age. Visuoconstructive skills, assessed by the WISC-III block design and object assembly subtests,¹³ were within high-average and average ranges, respectively.

Visual attention was normal in all aspects (selective, sustained, and shifted). Two of the three tasks of the TAVIS-3¹⁴ showed slowness in reaction time. Visual and auditory-verbal aspects of memory were within normal ranges. Language did not appear to be influenced by the observed and reported mild hearing deficit.

The second evaluation showed cognitive abilities that were within the limits of normal group variations. Once again, no diagnosis of a psychiatric disorder was made based on DSM-IV criteria.¹⁷

Intraindividual analysis

We calculated separate mean scaled scores for verbal and performance abilities. Tests in which the scaled scores were equal to the mean were considered to have no intraindividual variance; otherwise, tests were recoded considering positive or negative differences from the mean (e.g., for performance tests, the mean was 13, so a test with a scaled score of 8 was recorded as -5).

This method allowed us to observe the decline in performance skills taking place after radiotherapy; all performance subtests declined in comparison to baseline values (Table 1). Among the verbal subtests, only similarities and information improved after treatment. Despite the decline observed in some verbal skills, the magnitude of this impairment was lower than that affecting performance abilities.

Discussion

The results here described seem to suggest that some neuropsychological changes were present at follow-up when compared with the evaluation performed before radiotherapy. The patient's IQ decreased 22 points, from a high-average to an average classification.

Spiegler et al.⁹ found that IQ was the variable most susceptible to decline after radiotherapy in children. This decline may be related to changes in neuroplasticity that affect the maturation of brain structures and functions.⁵ Because of the patient's young age, nonverbal IQ should be considered more susceptible to decline, as a result of changes in speed and fine motor coordination. Ris et al.⁷ administered standard-dosage radiotherapy to young patients and observed more pronounced decreases in IQ when compared with older patients receiving low-dosage radiotherapy. Mulhern & Palmer⁶ found similar results in approximately 90% of children with medulloblastomas who showed decreases in IQ after radiotherapy.

Decreases in IQ occur gradually, with more rapid declines in the first year after treatment and then gradual, more stable declines for up to 10 years⁵; notwithstanding, it does not cease after this period. In this sense, our findings confirm the importance of providing follow-up for patients who undergo radiotherapy, because of the progression of deficits and the late manifestation of cognitive effects.^{9,11}

Table 1 - Intraindividual analysis

Tests	Pretreatment		Post-treatment	
	Scaled score	Intraindividual variation	Scaled score	Intraindividual Variation
Verbal tests				
Vocabulary	13	1	6	-6
Similarities	10	-2	15	3
Arithmetic	10	-2	9	-3
Digit span	18	6	13	1
Information	6	-6	10	-2
Performance tests				
Picture completion	12	1	8	-5
Coding	13	0	5	-8
Block design	18	5	13	0
Picture arrangement	8	-5	3	-10

Table 2 - WISC-III indices

	Pretreatment		Post-treatment	
	Index	Classification	Index	Classification
Global IQ	115	High average	93	Average
Verbal IQ	106	Average	99	Average
Performance IQ	123	Superior	87	Low average
Verbal comprehension	-	-	100	Average
Perceptual organization	122	Superior	93	Average
Distractibility	118	High average	106	Average
Processing speed	-	-	93	Average

IQ = intelligence quotient; WISC-III = Wechsler Intelligence Scale for Children, 3rd Edition.

Our patient showed a reversal of the predominance of verbal and nonverbal skills, with nonverbal skills prevailing at the first assessment and decreasing at the second assessment (Table 2 and Figure 1). These findings are consistent with other studies reporting that nonverbal skills are more likely to decline after radiotherapy,^{2,5} associated with neuronal death, myelin degeneration, and white matter reductions.⁵

Myelin degeneration and white matter damage affect functions associated with the right hemisphere (nondominant side), which work in an integrated network, with major reliance on connections between different regions. Even though the left hemisphere (dominant side) also has different areas of integration, it functions based on more specialized centers.¹⁸

The superiority of the patient’s nonverbal skills as observed in the first assessment may have played a “protective role” during radiotherapy. Conversely,

the subtests showing the greatest decline were coding and picture arrangement. Both tests are dependent of processing speed and demand different functions to work together – e.g., visual perceptual skills and visuomotor dexterity. As explained above, tests that demand a more integrated network are more prone to be disrupted.

The decline observed in nonverbal IQ scores appears to be related to slowness in visuomotor dexterity and visual attention tasks. Mulhern & Palmer⁶ have suggested that psychomotor slowing and decreases in processing speed were mainly responsible for IQ alterations after radiotherapy.

Our patient’s performance in attention tasks differed before and after radiotherapy (Table 3), with less impulsive responses to stimuli at the second assessment.

Notably, in our patient, cognitive profile alterations were associated with academic difficulties that required educational support. At the time of the initial evaluation, no complaints of poor academic performance had been reported.

Previous studies have reported learning problems associated with radiotherapy treatment in children with medulloblastomas.^{5,12} Psychosocial and educational interventions are being sought to reduce the impact of these deficits through rehabilitation.^{5,12} Neuropsychological evaluation is essential for rehabilitation planning and for providing more sensitive measures of the difficulties faced by children who undergo radiotherapy.^{5,10}

The current study should be understood in light of some limitations. First of all, the absence of a basal neuropsychological profile, obtained prior to the patient’s neurosurgery, is important, as the surgery may have been associated with the deficits observed.⁵ Also, pre- and post-treatment batteries were not exactly the same, making it difficult to draw some conclusions. No patient data are available after the second assessment. Finally, because this is a case report, our findings cannot be generalized to general population.

From a different standpoint, however, our findings can be considered important, especially for clinical

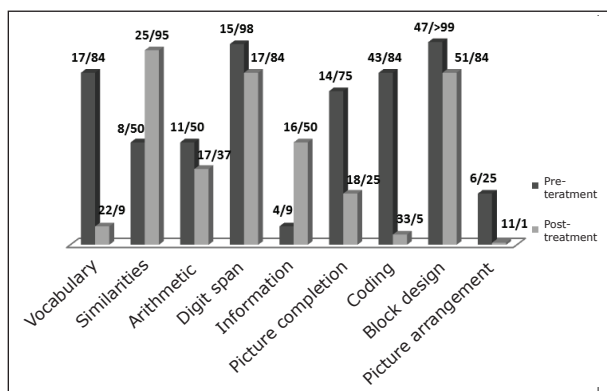


Figure 1 - Performance scores obtained before and after radiotherapy on the subtests of the Wechsler Intelligence Scale for Children, 3rd Edition (WISC-III): raw score/percentile. The subtests assessed the following skills: vocabulary - expressive language; similarities - verbal abstraction; arithmetic - mathematics skills; digit span - auditory-verbal working memory; information - general knowledge; picture completion - visual perception; coding - visuomotor dexterity; block design - visuoconstructive ability; picture arrangement - logical sequence.

Table 3 - Performance on the Test of Visual Attention (TAVIS-3)

	Pretreatment		Post-treatment	
	Index	Classification	Index	Classification
Reaction time				
Task 1	0.757	Normal	0.618	Impaired
Task 2	-	-	0.594	Normal
Task 3	0.715	Normal	0.625	Impaired
Omission errors				
Task 1	3	Impaired	0	Normal
Task 2	-	-	1	Impaired
Task 3	0	Normal	0	Normal
Commission errors				
Task 1	3	Impaired	1	Normal
Task 2	-	-	2	Normal
Task 3	4	Impaired	0	Normal

practitioners, as the results highlight the importance of performing a neuropsychological assessment before and after radiation treatment. It is noteworthy that pre-treatment data *per se* do not allow the clinician to identify the neuropsychological decline that may be present in some patients, as was the case here. Comparison of pre- and post-treatment neuropsychological results may be important to understand academic difficulties and to help in the development of rehabilitation strategies.

Future studies should investigate rehabilitation strategies to compensate for or prevent cognitive deficits and promote better quality of life for cancer patients and their families.^{5,12} The present case highlights the importance of evaluating patients who undergo radiotherapy both before and after treatment, as well as of understanding neuropsychological scores in association with the subjects' complaints, rather than relying on standard classifications only. Even though the post-treatment evaluation of our patient showed scores within average ranges, a negative impact of radiotherapy was demonstrated.

References

- Argollo N, Lessa I. Associação de sinais e sintomas com neoplasias cerebrais na infância. *J Pediatr (Rio J)*. 2000;76:361-7.
- Schmidt AT, Martin RB, Ozturk A, Kates WR, Wharam MD, Mahone EM, et al. Neuroimaging and neuropsychological follow-up study in a pediatric brain tumor patient treated with surgery and radiation. *Neurocase*. 2010;16:74-90.
- Argollo N, Lessa I. Aspectos clínico-epidemiológicos das neoplasias cerebrais na faixa etária pediátrica no Estado da Bahia, Brasil. *Arq Neuropsiquiatr*. 1999;57:442-51.
- Sabino AD. Enfrentamento do câncer infantil: vivências de pacientes em tratamento [thesis]. Ribeirão Preto: Universidade de São Paulo; 2008.
- Oliveira M, Almeida S, Silva E. Sequelas neurocognitivas em

- crianças com tumores cerebrais: uma revisão da literatura. *Psicol Saude Doencas*. 2010;11:83-99.
- Mulhern RK, Palmer SL. Neurocognitive late effects in pediatric cancer. *Curr Probl Cancer*. 2003;27:177-97.
- Ris MD, Packer R, Goldwein J, Jones-Wallace D, Boyett JM. Intellectual outcome after reduced-dose radiation therapy plus adjuvant chemotherapy for medulloblastoma: a Children's Cancer Group study. *J Clin Oncol*. 2001;19:3470-6.
- Reddick WE, White HA, Glass JO, Wheeler GC, Thompson SJ, Gajjar A, et al. Developmental model relating white matter volume to neurocognitive deficits in pediatric brain tumor survivors. *Cancer*. 2003;97:2512-9.
- Spiegler BJ, Bouffet E, Greenberg ML, Rutka JT, Mabbott DJ. Change in neurocognitive functioning after treatment with cranial radiation in childhood. *J Clin Oncol*. 2004;22:706-13.
- Papazoglou A, King TZ, Morris RD, Morris MK, Krawiecki NS. Attention mediates radiation's impact on daily living skills in children treated for brain tumors. *Pediatr Blood Cancer*. 2008;50:1253-7.
- Bernabeu J, Cañete A, Fournier C, López B, Barahona T, Grau C, et al. Evaluación y rehabilitación neuropsicológica en oncología pediátrica. *Psicooncología*. 2003;0:117-34.
- Penkman L, Scott-Lane L. Prophylactic academic intervention for children treated with cranial radiation therapy. *Dev Neurorehabil*. 2007;10:19-26.
- Figueiredo VL. Adaptação e padronização brasileira da Escala de Inteligência Wechsler para Crianças - 3ª edição (WISC-III). São Paulo: Casa do Psicólogo; 2002.
- Coutinho G, Mattos P, Araújo C, Borges M, Alfano A. Standardization of the normative group for the third version of the test of visual attention - TAVIS. *Dement Neuropsychol*. 2008;2:20-5.
- Adams W, Sheslom D. Wide Range Assessment of Memory and Learning (WRAML). Wilmington: Jastak Associates; 1990.
- Baddeley AD, Hitch GJ. Working memory. In: Bower GA, editor. *The psychology of learning and motivation*. New York: Academic Press; 1979.
- American Psychiatric Association. *Diagnostic and Statistical Manual of Mental Disorders - 4th edition (DSM-IV)*. Washington: APA; 1994.
- Haase VG, Pinheiro-Chagas P, Gonzaga DM, da Mata FG, Silva JB, Géio LA, et al. Um sistema nervoso conceitual para o diagnóstico neuropsicológico. *Contextos Clin*. 2008;1:125-38.

Correspondence:

Alessandra Lopes
 Centro de Neuropsicologia Aplicada
 Rua Diniz Cordeiro, 30, 2º andar
 22281-100 - Rio de Janeiro, RJ - Brazil
 E-mail: alessandra.perlopes@gmail.com