

and cavitations in the plate that correspond to the projections arising from the matrix.<sup>1,2,4</sup> It may also present itself as a nodule in the proximal nail fold or with hyperchromia. One of the clinical variants of OM is the giant or exuberant form, which is usually related to recurrent trauma and late diagnosis.<sup>2,4,5</sup>

Giant OMs are rarely reported in the literature. In 2016,<sup>4</sup> Fierro-Arias *et al.* reported the case of a 53-year-old male patient with a one-year posttraumatic lesion on the right third toe, whose dermatological examination showed onychodystrophy, pachyonychia, and a yellowish-brown nail color. Prevezas *et al.*, in 2016,<sup>5</sup> also described an asymptomatic case of giant OM in a 73-year-old male patient with a lesion on the left first toe, with more than 10 years of evolution and a history of repeated local traumas. Examination revealed almost total dystrophy of the nail, pachyonychia, nail plate cavities, hemorrhagic spots, and yellowish color. As in the present case, both patients were men with toenail involvement and with similarities in the clinical findings. However, these cases were related to previous traumas, different from the patient described here. It is also worth noting the importance of dermoscopy in the diagnosis of this variant, since nail dystrophy distorts the morphological characteristics usually seen in the traditional clinical examination. Finally, all patients had a slow-growing lesion and delayed seeking a dermatologist.

OM diagnosis is based on clinical and histological examinations and may be complemented by imaging tests such as ultrasonography and nuclear magnetic resonance.<sup>2</sup> Histology reveals a fibroepithelial neoplasm composed of a proximal and a distal zone. The proximal zone is characterized by invagination of the keratinized V-shaped epithelium; the distal zone is located in the region of the lunula and is characterized by digitiform projections that provoke perforations in the nail plate. The yellowish coloration seen at the clinical examination is caused by the thickening of the nail plate.<sup>2,4</sup>

The present case also had PAS positive septate hyphae on the histology of the excised lesion and clinical signs of onychomycosis in the nails of the other toes. It is known that there are several differential diagnoses of benign and malignant affections that affect the nail. Among them, onychomycosis is highlighted, since there is a discussion in the literature whether this is a predisposing factor for the development of OM or if OM is a predisposing factor for onychomycosis.<sup>2</sup> In many cases, there is coexistence between the two conditions, as demonstrated in the literature by Kallis and Tosti in 2015.<sup>3</sup>

Finally, this report highlights important issues regarding an unusual giant clinical variant of onychomatricoma in concomitance with onychomycosis, and draws attention to dermoscopy as an ally for differential diagnosis.

#### REFERENCES

1. Baran R, Kint A. Onychomatricoma. Filamentous tufted tumour in the matrix of a funnel-shaped nail: a new entity (report of three cases). *Br J Dermatol.* 1992;126:510-5.
2. Di Chiacchio N, Tavares GT, Padoveze EH, Bet DL, Di Chiacchio NG. Onychomatricoma. *Surg Cosmet Dermatol.* 2013;5:10-4.
3. Kallis P, Tosti A. Onychomycosis and Onychomatricoma. *Skin Appendage Disord.* 2015;1:209-212.
4. Fierro-Arias L, Corrales-Rosas B, Mercadillo-Pérez P, Medina-Castillo D, Peniche-

Castellanos A. Giant onychomatricoma in third toe: exceptional condition with surgical resolution. *J Eur Acad Dermatol Venereol.* 2016;30:525-7.

5. Prevezas C, Triantafyllopoulou I, Belyayeva H, Sgouros D, Konstantoudakis S, Panayiotides I, et al. Giant onychomatricoma of the toenail: case report and review focusing on less common variants. *Skin Appendage Disord.* 2016;1:202-8.

**How to cite this article:** Luce MCA, Lobo-Jardim MM, Kakizaki P, Valente NYS. Giant onychomatricoma. *An Bras Dermatol.* 2018;93(1):160-1.

#### Fox-Fordyce disease\*

Chaoyang Miao<sup>1,2</sup>  
Miao Zhang<sup>1,3</sup>

He Zhang<sup>1,3</sup>  
Xiaoyan Zhang<sup>1,2</sup>

DOI: <http://dx.doi.org/10.1590/abd1806-4841.20187348>

Dear editors,

Here we report a case of Fox-Fordyce disease (FFD). The patient is a 26-year-old woman with complaints of skin lesions in the bilateral axillae and vulva areas for 7 years. Seven years ago, some pruritic skin-colored papules began to appear in the bilateral axillae and vulva areas. The number of skin lesions increased gradually from then on. The lesions were intermittently pruritic, particularly in higher temperature during mental strain. She was well before, and both medical history and family history of the patient were unremarkable. The physical examination revealed numerous round (2-4mm), skin-colored to reddish papules (Figure 1). The hair in both axillae were sparse, and there was hair growth throughout from the center of some papules. The surrounding skin was normal.

Incision biopsy of the armpit showed hyperkeratosis and irregular acanthosis. The spongiosis involved the epidermis as well as the hair follicle. The dermis had a mild, superficial, perivascular and perifollicular lymphocytic infiltrate as well as some histocytes

Received on 13.06.2017.

Approved by the Advisory Board and accepted for publication on 03.08.2017.

\* Work performed at the China-Japan Friendship Hospital - Beijing, China.

Financial support: None.

Conflict of interests: None.

<sup>1</sup> Department of Dermatology, China-Japan Friendship Hospital - Beijing, China.

<sup>2</sup> Department of Dermatology, Peking University China-Japan Friendship School of Clinical Medicine, Beijing, China.

<sup>3</sup> Graduate School, Beijing University of Chinese Medicine, Beijing, China.

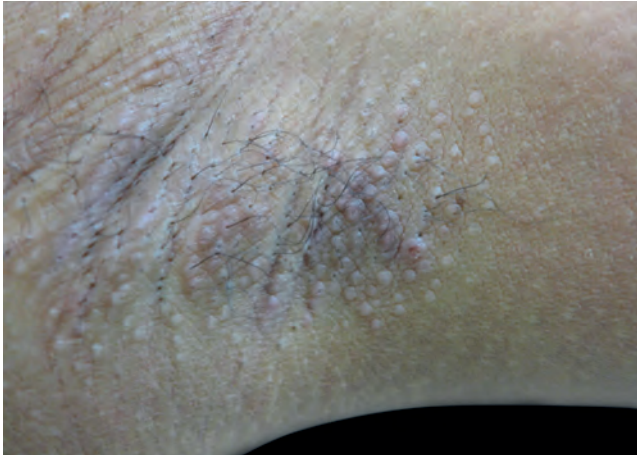
MAILING ADDRESS:

Xiaoyan Zhang

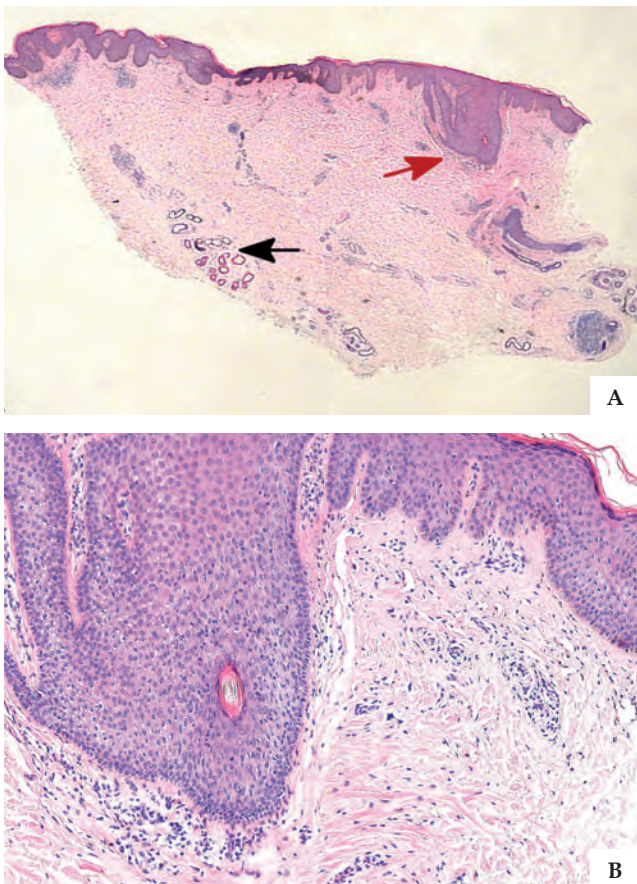
E-mail: [superfawn@aliyun.com](mailto:superfawn@aliyun.com)

©2018 by Anais Brasileiros de Dermatologia





**FIGURE 1:** Clinical appearance of Fox-Fordyce disease. Multiple skin-colored or reddish, hair follicle-centered papules (2-4mm) in the axillae



**FIGURE 2:** **A** - Hematoxylin & eosin, X10. Hyperkeratosis and irregular acanthosis, some mononuclear cells (indicated by red arrow) forming an infiltrate around hair follicle; dilation of sweat gland ducts (indicated by black arrow) in the lower-mid dermis. **B** - Hematoxylin-eosin, X100. Follicular spongiosis, some lymphocytes and a few histiocytes and eosinophils

and eosinophils. We could find some dilated sweat gland ducts in the deep dermis (Figure 2). We diagnosed the patient with FFD based on the typical clinical parameters and histopathological characteristics.

Fox-Fordyce disease was first described in 1902 by George Henry Fox and John Addison Fordyce.<sup>1</sup> It is a rare inflammatory disease of the apocrine sweat glands characterized by severely pruritic follicular papules confined to apocrine gland-bearing areas such as the axillae, groins, pubic region, perineum, labia majora, areola mammae, and umbilicus. It is predominantly seen in women. The disease occurs mostly in postpubertal women between 13 and 35 years old. It has rarely been reported before puberty, after menopause, or in men. Itching is aggravated by emotional, physical, or pharmacological stimulations that cause apocrine sweating. The exact etiopathogenesis of the disease remains elusive. Some case reports revealed that laser hair removal therapy may cause the disease.<sup>2</sup>

Histopathological examination is characterized by keratin plugging, resulting in dilatation and rupture of the apocrine duct. Rupture results in spongiosis of the follicular wall. Perifollicular and perivascular inflammatory infiltrate is also observed. Perifollicular foamy cells could be the histopathologic hallmark of this disease.

There is no definitive treatment for Fox-Fordyce disease. However, many different therapeutic modalities have shown variable efficacy in small subsets of patients. Previously, many therapies have been applied to this disease, including topical and intralesional application of corticosteroids, topical or systemic retinoid, clindamycin, benzoyl peroxide, oral contraceptives, isotretinoin, and phototherapy, but the efficacy was unsatisfactory. However, some case reports revealed that topical pimecrolimus and tacrolimus, excision-liposuction and curettage, fractional carbon dioxide laser, pulsed dye laser and so on may be proposed to remove the cutaneous lesions.<sup>3-5</sup> For this patient, we chose the topical treatment with corticosteroids as well as oral antihistamines for 1 month. Although there was no change in lesions, the pruritus improved slightly.

In conclusion, although Fox-Fordyce disease is uncommon, it is not difficult to diagnose based on clinical and histopathologic manifestations. When we encounter similar cases in clinical work, we shall try to search for pathogenesis and effective treatments for the disease. □

#### REFERENCES

1. Helfman RJ. A new treatment of Fox-Fordyce disease. *South Med J.* 1962;55:681-4.
2. Yazganoğlu KD, Yazici S, Büyükbabani N, Ozkaya E. Axillary Fox-Fordyce-like disease induced by laser hair removal therapy. *J Am Acad Dermatol.* 2012;67:e139-40.
3. Kaya Erdoğan H, Bulur I, Kaya Z. Clinical Effects of Topical Tacrolimus on Fox-Fordyce Disease. *Case Rep Dermatol Med.* 2015;2015:205418.
4. Ahmed Al-Qarqaz F, Al-Shannag R. Fox-Fordyce disease treatment with fractional CO2 laser. *Int J Dermatol.* 2013;52:1571-2.
5. Uzuncakmak TK, Karadag AS, Ozlu E, Akdeniz N, Cobanoglu Simsek B. Effective treatment of Fox-Fordyce disease with pulsed dye laser. *Photodermatol Photoimmunol Photomed.* 2016;32:311-3.

*How to cite this article:* Miao CY, Zhang H, Zhang M, Zhang XY. Fox-Fordyce disease. *An Bras Dermatol.* 2018;93(1):161-2.