





REFERENCES

1. Mercado JOC, Lopez LEB, Wolosky OC, Ordiales LL, Caire ST. Follicular psoriasis: A forgotten entity. *J Am Acad Dermatol*. 2017;76(Suppl 1):AB141.
2. Stankler L, Ewent SWB. Follicular psoriasis. *Br J Dermatol*. 1981;104:153-6.
3. Nguyen CV, Farah RS, Maguiness SM, Miller DD. Follicular Psoriasis: Differentiation from Pityriasis Rubra Pilaris-An Illustrative Case and Review of the Literature. *Pediatr Dermatol* 2017;34:65-8.
4. Babino G, Moscarella E, Longo C, Lallas A, Ferrara G, Cusano F, et al. Follicular psoriasis: an under-recognized condition. *J Eur Acad Dermatol Venereol*. 2016;30:1397-9.
5. Arps DP, Chow C, Lowe L, Chan MP. Follicular Psoriasis. *J Cutan Pathol*. 2013;40:859-62.

AUTHORS' CONTRIBUTIONS

Bruno de Castro e Souza	 ORCID 0000-0001-7140-3462
Elaboration and writing of the manuscript; Obtaining, analyzing and interpreting the data; Critical review of the literature	
Luisa Groba Bandeira	 ORCID 0000-0003-0602-1016
Elaboration and writing of the manuscript; Obtaining, analyzing and interpreting the data; Critical review of the literature	
Thais do Amaral Carneiro Cunha	 ORCID 0000-0002-8092-1277
Approval of the final version of the manuscript; Conception and planning of the study; Intellectual participation in propaedeutic and/or therapeutic conduct of the cases studied; Critical review of the manuscript	
Neusa Yuriko Sakai Valente	 ORCID 0000-0002-8065-2695
Approval of the final version of the manuscript; Conception and planning of the study; Effective participation in research orientation; Intellectual participation in propaedeutic and/or therapeutic conduct of the cases studied; Critical review of the manuscript	

How to cite this article: Souza BC, Bandeira LG, Cunha TAC, Valente NYS. Follicular psoriasis: an underdiagnosed entity? *An Bras Dermatol*. 2018;94(1):116-8.

Successful management of chronic refractory onycholysis by partial nail avulsion followed by topical tretinoin*

Pedro Colli Rocha Dias¹
Anna Carolina Miola¹
Helio Amante Miot¹

DOI: <http://dx.doi.org/10.1590/abd1806-4841.20198009>

Received 19 December 2017.

Accepted 02 April 2018.

* Work conducted at the Department of Dermatology and Radiotherapy, Faculdade de Medicina de Botucatu, Universidade Estadual Paulista, Botucatu (SP), Brazil.
Financial support: None.
Conflict of interest: None.

¹ Department of Dermatology and Radiotherapy, Faculdade de Medicina de Botucatu, Universidade Estadual Paulista, Botucatu (SP), Brazil.

MAILING ADDRESS:

Anna Carolina Miola
E-mail: anna_fmrip@yahoo.com.br

©2019 by Anais Brasileiros de Dermatologia



Dear Editor,

Onycholysis is a common complaint in dermatologic clinics and consists of the separation of the nail plate from its distal bed. Due to its several etiologies (e.g. onychomycosis, neoplasia, trauma, contact dermatitis, psoriasis, lichen planus, and medications), it requires an intensive semiological practice and clinical suspicion prior to the definition of its therapeutic strategy.¹

Chronic onycholysis leads to keratinization of the nail bed and may cause a disappearing nail bed, defined as the shortening of the nail plate by more than 20% compared to an unaffected contralateral finger. In addition, subclinical bacterial proliferation may occur (e.g. *Pseudomonas sp.*), which makes chronic onycholysis even more challenging.^{2,3}

This is the first report of successful treatment of chronic onycholysis by surgical avulsion of the onycholytic portion of the nail, followed by the application of topical tretinoin on the nail bed.

A 49-year-old female patient, without comorbidities or use of medications, presented with yellow-greenish fingernail discoloration of the right third finger, and shortening of the nail plate of the right first finger six years ago (Figure 1). The patient showed no improvement after successive previous oral (fluconazole) and topical (ketoconazole 2% cream and ciprofloxacin 0.3% eye drops) treatments. Mycological examination, culture, and nail clipping were all negative, leading to the hypothesis of chronic onycholysis and disappearing nail bed. Our therapeutic option was avulsion of the affected area (Figure 2) and daily treatment with tretinoin 0.025% gel on both nail beds, which resulted in complete improvement of the condition at a three-month follow-up (Figure 3).

Since onychomycosis represents the main cause of onycholysis and demands a long term specific treatment with potential toxicity, diagnostic investigation of onycholysis should be conducted with direct mycological exams, culture, and nail clipping.⁴ Dermoscopy and biopsy of nail plate and nail bed are additional elements for the diagnostic investigation.

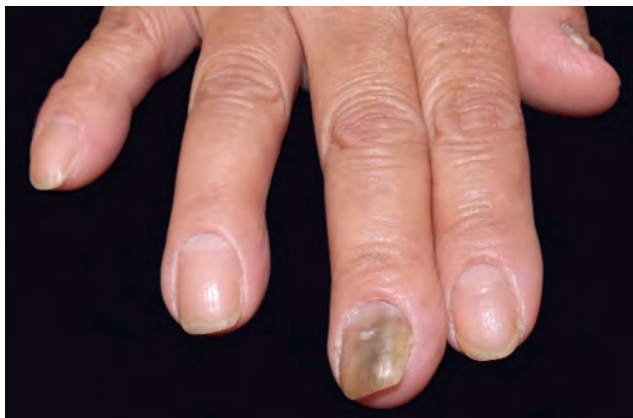

FIGURE 1: Onycholysis with yellowish-green discoloration suggesting underlying bacterial proliferation

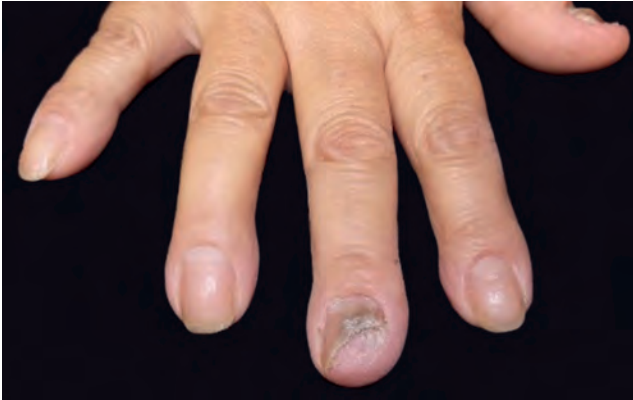

FIGURE 2: Partial nail avulsion of the onycholytic area with an intensely keratinized nail bed

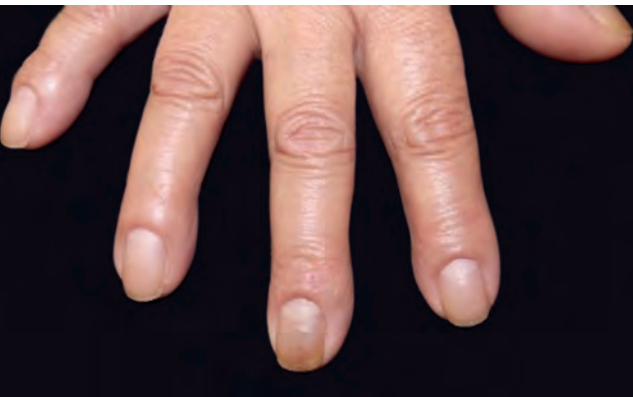

FIGURE 3: Result after three months of tretinoin 0.025% gel applied to the nail bed, with complete nail adhesion

Refractory onycholysis may also result from a long-standing onychomycosis, which, even if efficiently treated, may progress to bed keratinization and disappearing nail bed.

Partial avulsion of the onycholytic nail plate is a safe outpatient procedure under local anesthesia, which, by not manipulating the nail matrix or the lateral ligaments, does not pose a risk of posterior nail dystrophy. In addition, the clearing of the onycholytic portion of the nail favors cleaning, disinfection, and application of nail bed actives.

Retinoids have the potential to delay epithelial keratinization and increase the expression of intercellular adhesion molecules (e.g. desmosomes), which may promote the adhesion of the nail plate to the nail bed, as occurred in our case. Tazarotene is a third-generation retinoid approved for the treatment of acne and psoriasis. A double-blind, randomized, vehicle-controlled, par-

allel-group trial showed that the use of tazarotene 0.1% gel for 24 weeks was efficient in the treatment of onycholysis caused by psoriasis, in addition to a significant reduction in pitting in occluded nails. According to the authors, its effect on epithelial proliferation and nail bed keratinization rate would have led to the reversal of the onycholytic psoriasis phenotype, also acting on the nail matrix, reversing the pitting.⁵




The present case report aims to reinforce the need for the systematization of diagnostic investigation in patients with onycholysis and to demonstrate the effectiveness of the combination of surgical approach and keratinization modifiers to recover adhesion of the nail plate to the bed.

However, controlled clinical trials and other clinical and/or surgical approaches to the nail bed should be studied in order to establish effective strategies in the treatment of refractory onycholysis. Since there are only case reports published and the possibility of therapeutic failure, the need for alternative therapies is justified. □

REFERENCES

1. Velez NF, Jellinek NJ. Simple onycholysis: a diagnosis of exclusion. *J Am Acad Dermatol.* 2014;70:793-4.
2. Daniel CR 3rd, Tosti A, Iorizzo M, Piraccini BM. The disappearing nail bed: a possible outcome of onycholysis. *Cutis.* 2005;76:325-7.
3. Tosti A, Piraccini BM. Treatment of common nail disorders. *Dermatol Clin.* 2000;18:339-48.
4. Bertanha L, Chiacchio ND. Nail clipping in onychomycosis. *An Bras Dermatol.* 2016;91:688-90.
5. Scher RK, Stiller M, Zhu YI. Tazarotene 0.1% gel in the treatment of fingernail psoriasis: a double-blind, randomized, vehicle-controlled study. *Cutis.* 2001;68:355-8.

AUTHORS' CONTRIBUTIONS

Pedro Colli Rocha Dias	 ORCID 0000-0002-6987-5177
Elaboration and writing of the manuscript; Intellectual participation in propaedeutic and / or therapeutic of cases studied	
Anna Carolina Miola	 ORCID 0000-0001-8926-734X
Elaboration and writing of the manuscript; Critical review of the literature	
Helio Amante Miot	 ORCID 0000-0002-2596-9294
Approval of the final version of the manuscript; Elaboration and writing of the manuscript; Critical review of the literature; Critical review of the manuscript	

How to cite this article: Dias PCR, Miola AC, Miot HA. Successful management of chronic refractory onycholysis by partial nail avulsion followed by topical tretinoin. *An Bras Dermatol.* 2019;94(1):118-9.