

## BASIC RESEARCH

# Histomorphometric changes in the perirenal adipocytes of adrenalectomized rats treated with dexamethasone

Fairus Ahmad,<sup>1</sup> Ima Nirwana Soelaiman,<sup>2</sup> Elvy Suhana Mohd Ramli,<sup>1</sup> Tan Ming Hooi,<sup>3</sup> Fariyah H. Suhaimi<sup>1</sup>

<sup>1</sup>Anatomy, Universiti Kebangsaan Malaysia, Kuala Lumpur, Malaysia. <sup>2</sup>Pharmacology, Universiti Kebangsaan Malaysia, Kuala Lumpur, Malaysia.

<sup>3</sup>Biomedical Science, Universiti Tunku Abdul Rahman, Kampar Perak, Malaysia.

**INTRODUCTION:** Prolonged steroid treatment administered to any patient can cause visceral obesity, which is associated with metabolic disease and Cushing's syndrome. Glucocorticoids have a profound negative effect on adipose tissue mass, giving rise to obesity, which in turn is regulated by the 11 $\beta$ -hydroxysteroid dehydrogenase type 1 enzyme. Adrenalectomized rats treated with dexamethasone exhibited an increase in visceral fat deposition but not in body weight.

**OBJECTIVES:** The main aim of this study was to determine the effect of dexamethasone on the histomorphometric characteristics of perirenal adipocytes of adrenalectomized, dexamethasone-treated rats (ADR+Dexa) and the association of dexamethasone treatment with the expression and activity of 11 $\beta$ -hydroxysteroid dehydrogenase type 1 (11 $\beta$ -hydroxysteroid dehydrogenase type 1).

**METHODS:** A total of 20 male Sprague Dawley rats were divided into 3 groups: a baseline control group (n=6), a sham-operated group (n=7) and an adrenalectomized group (n=7). The adrenalectomized group was given intramuscular dexamethasone (ADR+Dexa) 2 weeks post adrenalectomy, and the rats from the sham-operated group were administered intramuscular vehicle (olive oil).

**RESULTS:** Treatment with 120  $\mu$ g/kg intramuscular dexamethasone for 8 weeks resulted in a significant decrease in the diameter of the perirenal adipocytes ( $p<0.05$ ) and a significant increase in the number of perirenal adipocytes ( $p<0.05$ ). There was minimal weight gain but pronounced fat deposition in the dexamethasone-treated rats. These changes in the perirenal adipocytes were associated with high expression and dehydrogenase activity of 11 $\beta$ -hydroxysteroid dehydrogenase type 1.

**CONCLUSIONS:** In conclusion, dexamethasone increased the deposition of perirenal fat by hyperplasia, which causes increases in the expression and dehydrogenase activity of 11 $\beta$ -hydroxysteroid dehydrogenase type 1 in adrenalectomized rats.

**KEYWORDS:** Dexamethasone; Adrenalectomized rat; Perirenal fat; Hyperplasia; 11 $\beta$ -hydroxysteroid dehydrogenase type 1.

Ahmad F, Soelaiman IN, Ramli ESM, Hoo TM, Suhaimi F. Histomorphometric changes in the perirenal adipocytes of adrenalectomized rats treated with dexamethasone. Clinics. 2011;66(5):849-853.

Received for publication on January 14, 2011; First review completed on January 30, 2011; Accepted for publication on January 30, 2011

E-mail: fariyah@medic.ukm.my

Tel.: 603-9289 7263

## INTRODUCTION

Prolonged steroid treatment causes visceral obesity. Visceral obesity is associated with metabolic diseases, which increase the risk of cardiovascular disease and diabetes mellitus.<sup>1</sup> The deposition of visceral adipocytes is the result of an increase in the intake of dietary fat and a decrease in the demand for energy.<sup>2</sup> This positive energy balance is

stored as adipose tissue, causing the adipose mass to expand. The expansion of adipose mass can occur because of an increase in adipocyte size (hypertrophy) or number (hyperplasia) or both. Different adipose tissues have different tendencies to undergo hypertrophy and hyperplasia. Mesenteric and epididymal adipose tissue depots have a tendency to undergo hypertrophy, whereas retroperitoneal and inguinal adipocytes have a tendency to undergo hyperplasia during the development of obesity.<sup>3</sup> Additionally, fat cells with different mean adipocyte diameters have been obtained from biopsies from different locations and donors.<sup>4</sup>

Glucocorticoids are essential for the differentiation of adipocytes, and they play an important role in the

pathogenesis of visceral obesity.<sup>5</sup> The enzyme 11 $\beta$ -hydroxysteroid dehydrogenase type 1 (11 $\beta$ -HSD1) catalyzes the interconversion of the active glucocorticoid, cortisol in humans and corticosterone in rodents, to the inactive glucocorticoid, cortisone and 11-dehydrocorticosterone, respectively. In rat adipose tissue, 11 $\beta$ -HSD1 acts predominantly as a reductase enzyme; it catalyzes the conversion of 11-dehydrocorticosterone to corticosterone, which results in hypertrophy of adipocytes.<sup>6</sup> The dehydrogenase activity of 11 $\beta$ -HSD1 converts corticosterone to 11-dehydrocorticosterone, which results in hyperplasia of adipocytes.<sup>7</sup>

Body weight was noted to be reduced in several animal models of obesity after removal of glucocorticoids by adrenalectomy.<sup>8</sup> There was pronounced fat deposition in adrenalectomized rats after treatment with glucocorticoids, but no significant increase in weight was observed.<sup>9,10</sup> However, the activity of 11 $\beta$ -HSD1 in omental fat was noted to decrease in adrenalectomized obese rats.<sup>11</sup> Therefore, in this study, we aimed to investigate the histomorphometric effects on perirenal adipocytes and the associated increase in fat deposition following glucocorticoid treatment. We also aimed to investigate the relationship of fat deposition with the activity and expression of 11 $\beta$ -HSD1.

## MATERIALS AND METHODS

### Animals and surgery

Male Sprague Dawley rats weighing between 200 and 250 g were housed in a temperature-controlled (20–22°C) environment with a 12-hour light-darkness cycle. All animals were housed in groups of 2 for 2 weeks before adrenalectomy. The rats were given a normal rat chow diet (Gold Coin, Malaysia) and normal saline ad libitum. Prior ethical approval was obtained from the Animal Ethics Committee of Universiti Kebangsaan Malaysia (UKMAEC No: PP/ANAT/2008/FARIHAH/21-AUGUST/240-OCT-2008-JUNE-2009).

Bilateral adrenalectomy was performed through a mid-line dorsal incision followed by a small incision through the muscle layer under 1:1 Xylazil (Ilium, Australia) and Ketapex (Troy, Australia) anesthesia at 0.1 ml/100 g of body weight. After removal of the adrenal glands, the incision was sutured, and a topical antiseptic, Povidern (Hoe, Malaysia), was applied over the wound. For the sham-operated rats, the adrenals were left in place.

A total of 20 male Sprague Dawley rats were divided into 3 groups: a baseline control group (n=6), a sham-operated group (n=7) and an adrenalectomized group (n=7). The adrenalectomized group was given intramuscular dexamethasone (Sigma, USA) (ADR+Dexa) at a dose of 120  $\mu$ g/kg 2 weeks post adrenalectomy.<sup>12</sup> The dexamethasone was started 2 weeks after adrenalectomy to reduce the risk of infection and to allow full recovery of the rats. The rats from the sham-operated group were given intramuscular vehicle (olive oil). The intramuscular treatment and vehicle were given to the rats for 8 weeks before sacrifice. All of the rats in the baseline group were sacrificed after 2 weeks of acclimatization in the Animal Unit. The animals were weighed regularly to allow accurate dosing and to monitor the weight gain.

The rats were given diethyl ether (BDH, England) before being sacrificed by cervical dislocation. Pictures of visceral adipose tissue were taken, and perirenal adipose tissues were dissected bilaterally. Some of the adipose tissues were kept at -70°C, and others were fixed in 10 % formalin.

### Histological analysis

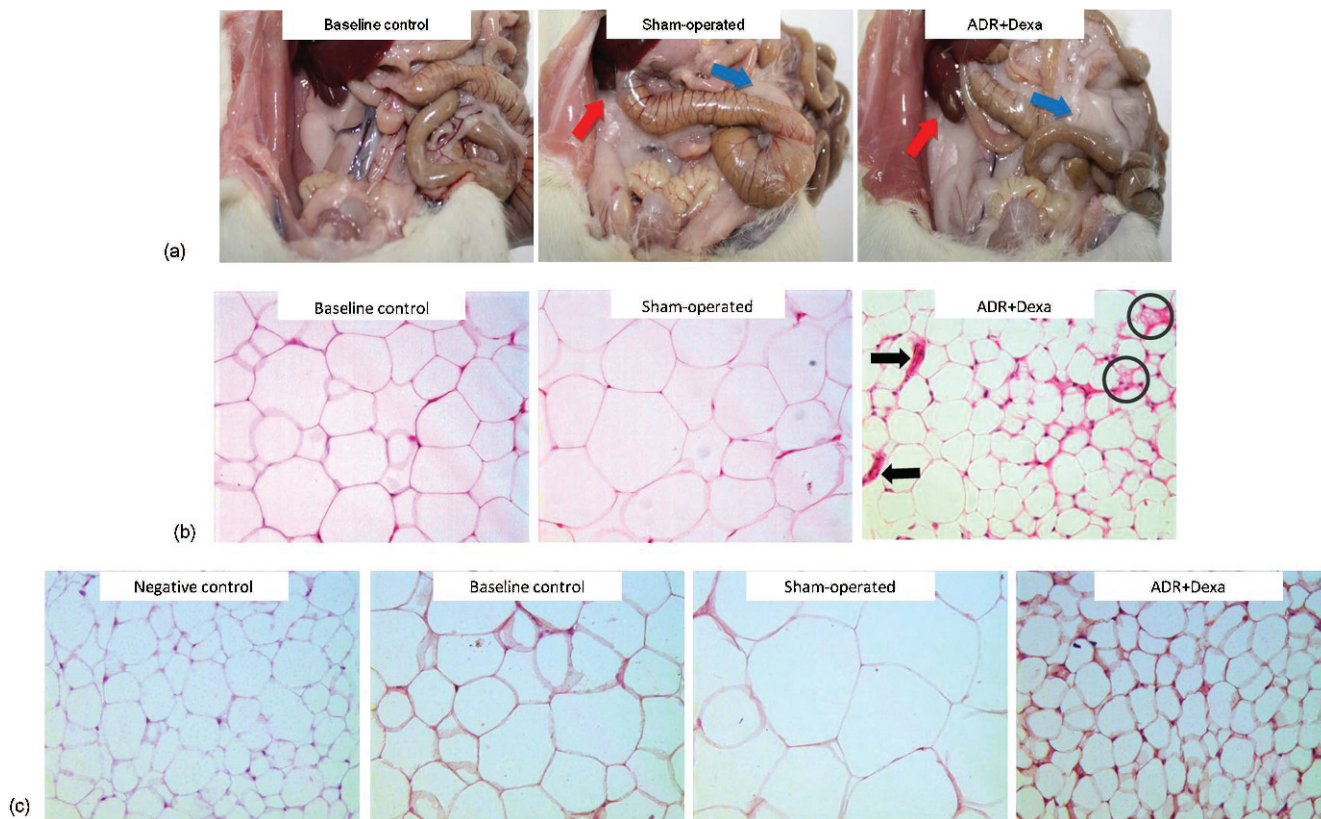
Samples of perirenal adipose tissue were immediately fixed in 10 % formalin, and after 24 hours, the samples were processed using an automatic tissue-processing machine (Microm, Germany). The samples were then embedded in paraffin, and 5  $\mu$ m sections were obtained. Approximately 25 sections were obtained, and every fifth section was taken for staining. Sections were stained with hematoxylin (Sigma Chemical, USA) and eosin (BDH, England) (H&E) using an automatic staining machine (Leica, Germany). Finally, sections were mounted on dibutyl phthalate in xylene (DPX). Photomicrographs of adipocytes were taken using a camera (CTRMIC from Leica, Germany) and were analyzed with Video T-Test Morphology 5.1 software from Russia. The diameter and the total number of adipocytes were determined.

### Immunohistochemistry

After samples were fixed in 10 % formalin and processed, 5  $\mu$ m sections were cut and placed on polysine slides (Thermo Scientific, Germany) for immunohistochemistry. Slides were dewaxed in xylene and dehydrated in a series of alcohol to water. For antigen retrieval, the slides were treated with citrate-buffered solution (200 ml; 0.01 M; pH 6) and rinsed with phosphate-buffered solution (PBS). The slides were then treated with hydrogen peroxide before being incubated with normal goat serum at a dilution of 1:50. Next, the slides were rinsed with PBS and incubated with primary antibody (Cayman Chemical, USA) at a dilution of 1:1000 for 1 hour. Negative-control sections were incubated in PBS without primary antibody. After rinsing with PBS, the tissue-bound primary antibody was detected using biotinylated secondary antibody and the avidin-biotin-peroxidase complex method (Vectastain Elite ABC kit, USA) with diaminobenzidine tetrahydrochloride (DAB) (Vector Laboratories, USA) as the chromogen. Finally, the slides were counterstained with Meyer's Hematoxylin (Richard-Allan Scientific, USA) for 45 seconds and mounted with DPX. Two blinded observers analyzed the slides, and the slides were graded according to the intensity of the immunoreactive stained area. The intensity grading was as follows: no staining was '0'; weak staining was '1'; mild staining was '2'; and strong staining was '3'.

### Assay for 11 $\beta$ -HSD1 enzyme activity

The level of 11 $\beta$ -HSD1 dehydrogenase activity in adipose tissue homogenates was determined by measuring the rate of conversion of corticosterone to 11-dehydrocorticosterone, as described by Moison et al., with some modifications.<sup>13</sup> Perirenal adipose tissue was homogenized in Krebs-Ringer bicarbonate buffer, and the total protein content was estimated calorimetrically using aliquots of each homogenate. Tissue homogenates containing 0.5 mg of protein were added to a solution of 200  $\mu$ M NADP (Sigma, Germany), 12 nM [1,2,6,7-<sup>3</sup>H] corticosterone (American Radioactive Chemicals, USA) and Krebs-Ringer bicarbonate buffer (containing 0.2 % glucose and 0.2 % BSA); the total reaction volume was 250  $\mu$ l. After incubation in a shaking water bath at 37°C for 1 hour, the reaction was arrested by the addition of 1 ml of ethyl acetate, and the steroids were extracted by centrifugation at 4°C and 3000 rpm for 10 minute. The top layer was then transferred and evaporated to dryness at 55°C before being dissolved in ethanol containing corticosterone and 11-dehydrocorticosterone. The steroid residue was



**Figure 1 -** (a) An adrenalectomized rat treated with dexamethasone (ADR+Dexa) and a rat from the sham-operated group had more visceral fat deposition (perirenal fat—red arrows; mesenteric fat—blue arrows) compared with the rat from the baseline control group. (b) The number of adipocytes per slide (H&E staining) was greater in the adrenalectomized rats treated with dexamethasone (ADR+Dexa), but the diameters of these cells were smaller than those seen in rats from the sham-operated and baseline control groups. The circles show hyperplasia of adipocytes, and the arrows show blood vessels. Magnification X 20. (c) Immunoreactive staining of 11β-HSD1 in adrenalectomized rats treated with dexamethasone (ADR+Dexa) showed stronger immunoreactive staining compared with that of the baseline control and sham-operated rats. Magnification X 20.

separated using thin-layer chromatography (Whatman, Germany) in chloroform and 95 % ethanol at a ratio of 92:8. The bands containing the labeled corticosterone and 11-dehydrocorticosterone were identified by UV light at 240 nm, scraped and transferred into scintillation vials containing scintillation fluid before being counted with a β-counter (Wallac 1409, Finland). The percentage conversion of corticosterone to 11-dehydrocorticosterone was calculated.

**Data analysis**

The results are expressed as mean ± standard error mean (SEM). The means were compared using one-way analysis-of-variance (ANOVA) followed by Tukey’s *post hoc* test and a t-test. All of the statistical analyses were performed using the Statistical Package for Social Sciences (SPSS) software.

**RESULTS**

**Body weight**

Adrenalectomized rats treated with dexamethasone (ADR+Dexa) showed less weight gain compared with rats from the sham-operated group following 8 weeks of treatment (Fig. 2(a)).

**Observation of visceral adipose tissue**

Adrenalectomized rats treated with dexamethasone (ADR+Dexa) and rats from sham-operated groups showed more visceral fat deposition compared with the baseline control group (Fig. 1(a)).

**Adipocyte histomorphometry**

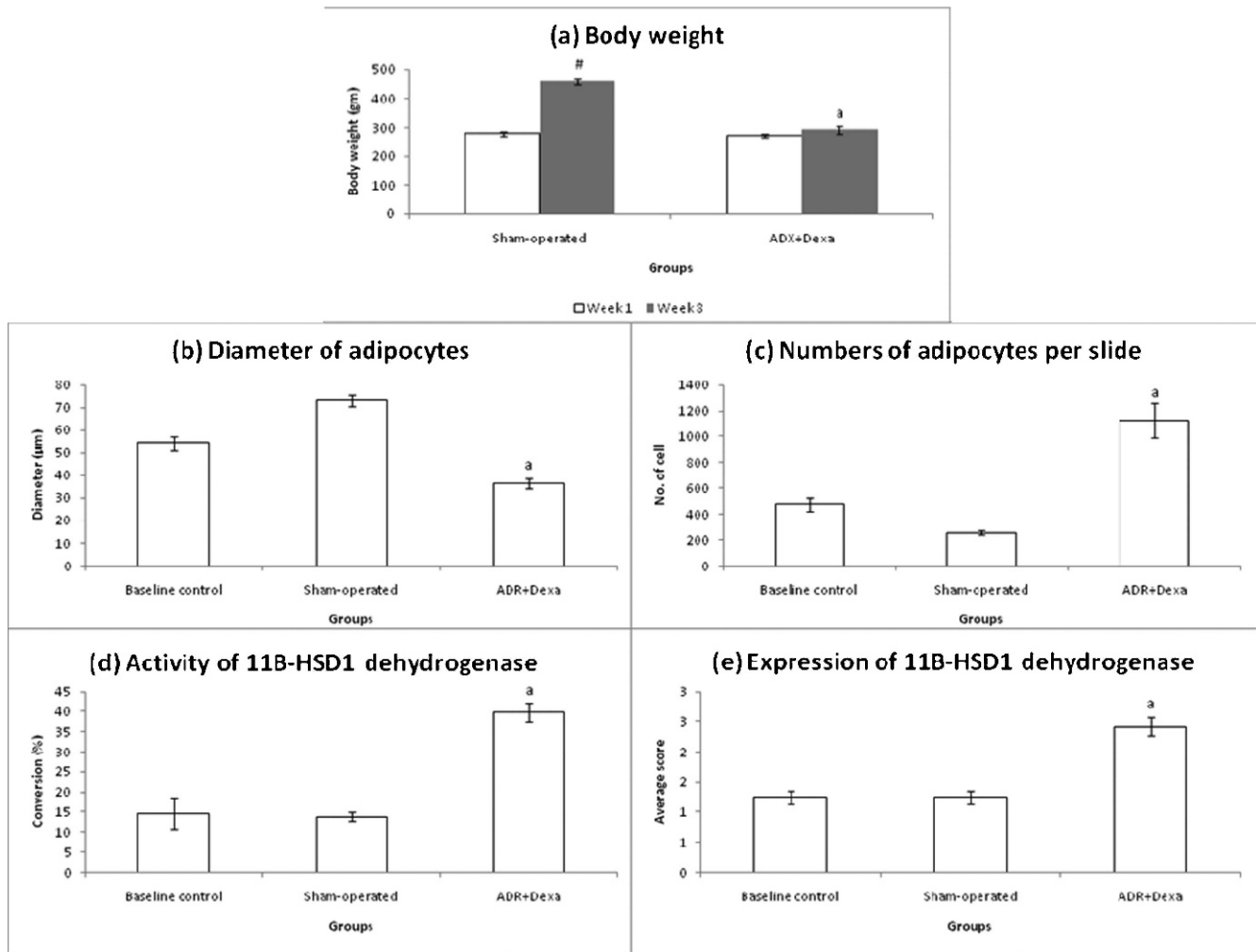
Individual adipocytes in adrenalectomized rats treated with dexamethasone (ADR+Dexa) had significantly smaller diameters than the sham-operated and baseline control groups (Figs. 1(b) and 2(b)). The average number of adipocytes on one slide for adrenalectomized rats treated with dexamethasone was significantly greater than that of sham-operated and baseline control rats (Figs. 1(b) and 2(c)).

**Expression of 11β-HSD1**

Expression of 11β-HSD1 was greater in adrenalectomized rats treated with dexamethasone (ADR+Dexa) than in sham-operated and baseline control groups (Figs. 1(c) and 2(d)).

**Activity of enzyme 11β-HSD1 dehydrogenase**

The dehydrogenase activity of 11β-HSD1 in adrenalectomized rats treated with dexamethasone (ADR+Dexa) was



**Figure 2** - (a) Average body weight of the adrenalectomized rats treated with dexamethasone (ADR+Dexa) revealed that these rats gained less weight than the sham-operated rats after 8 weeks. <sup>a</sup>  $p < 0.05$  indicates a significant difference between the ADR+Dexa group and the sham-operated group. <sup>#</sup>  $p < 0.05$  indicates a significant difference between week 1 and week 8 for the sham-operated rats. (b) The diameter of adipocytes of the adrenalectomized rats treated with dexamethasone (ADR+Dexa) was smaller than that of adipocytes from baseline control and sham-operated rats. (c) The number of adipocytes per slide was greater for adrenalectomized rats treated with dexamethasone (ADR+Dexa) than for baseline control and sham-operated rats. (d) The expression level of 11 $\beta$ -HSD1 in adrenalectomized rats treated with dexamethasone (ADR+Dexa) was significantly higher than that in baseline control and sham-operated rats. (e) The dehydrogenase activity of 11 $\beta$ -HSD1 of the adrenalectomized rats treated with dexamethasone (ADR+Dexa) was significantly greater than that of the baseline control and sham-operated rats. <sup>a</sup>  $p < 0.05$  indicates a significant difference between the ADR+Dexa group and the baseline control and sham-operated groups.

significantly higher than that in the sham-operated and baseline control rats (Fig. 2(e)).

## DISCUSSION

The present study produced results similar to those of other studies, whereby adrenalectomized rats treated with dexamethasone had increased fat deposition with minimal weight gain.<sup>10</sup> Another study showed that after 2 weeks of adrenalectomy without supplementation of glucocorticoids, the amount of perirenal fat was found to be decreased compared with that of rats with intact adrenal glands.<sup>9</sup> However, in this study, we found that the weight gain of the adrenalectomized rats had increased after 2 weeks of adrenalectomy. Therefore, the removal of endogenous glucocorticoids by adrenalectomy may lead to a decrease in appetite and food intake, causing a minimal increase in body weight.<sup>8</sup>

The increase in fat deposition in adrenalectomized rats treated with dexamethasone appeared to be similar to that of rats in the control group; however, there was a significant difference in total body weight.<sup>14</sup> Indeed, studies have shown that excessive doses and prolonged administration of dexamethasone in adrenalectomized rats does not increase the body weight, a result that might be due to the generalized wasting of all body components.<sup>15,16</sup> Therefore, prolonged administration of dexamethasone in the adrenalectomized rats increased their visceral obesity without increasing their total body weight.<sup>17</sup>

The administration of dexamethasone may lead to the onset of the development of adipocytes. The perirenal adipocytes have a tendency to undergo hyperplasia followed by hypertrophy, as seen in the control rats.<sup>18</sup> The photomicrograph in Fig. 1(b) shows clusters of smaller adipocytes (circles) that formed with the presence of blood

vessels (arrows) close to the adipocytes that underwent hyperplasia. The increases in the numbers of adipocytes (hyperplasia) and blood vessels are characteristics of a metabolically active state, which is seen in the development of adipocytes.<sup>19</sup>

These findings were supported by an increase in the expression and dehydrogenase activity of 11 $\beta$ -HSD1 in adrenalectomized rats treated with dexamethasone. Balanchandran and colleagues showed that dexamethasone stimulates the dehydrogenase activity of 11 $\beta$ -HSD1, and this increased activity caused an increase in perirenal fat deposition as a result of hyperplasia in the adrenalectomized rats.<sup>20</sup> However, the inhibition of the activity of the reductase activity of 11 $\beta$ -HSD1 by dexamethasone may be due to a negative feedback effect of glucocorticoid.<sup>20</sup> Therefore, we suggest that the perirenal adipocytes did not undergo hypertrophy, and as a result, the body weight of the adrenalectomized rats treated with dexamethasone did not increase significantly.

Recently, a study showed that the reductase activity was at its maximum if the dehydrogenase activity of the enzyme was at its minimum as the result of the bidirectional capacity of 11 $\beta$ -HSD1.<sup>21</sup> We therefore suggest that an increase in the reductase activity of 11 $\beta$ -HSD1 caused the increase in the diameter of the adipocytes as a result of hypertrophy. This is because the expression and dehydrogenase activity of 11 $\beta$ -HSD1 was decreased in the control rats compared with adrenalectomized rats treated with dexamethasone, as shown in our study. This result suggests that the reductase activity of 11 $\beta$ -HSD1 may have caused the adipocytes to undergo hypertrophy and, therefore, played an important role in the weight gain of the rats.

## CONCLUSION

In conclusion, long-term glucocorticoid treatment increased the expression and dehydrogenase activity of the 11 $\beta$ -HSD1 enzyme. This increased expression and activity was associated with hyperplasia of the perirenal adipocytes but not with weight gain. Therefore, the dehydrogenase activity of 11 $\beta$ -HSD1 plays an important role in the onset of the development of obesity. However, elucidating the underlying mechanism requires further study.

## ACKNOWLEDGMENTS

This work was supported by Universiti Kebangsaan Malaysia research grant FF-239-2008. The authors gratefully acknowledge the staff of the Department of Anatomy and Pharmacology, Faculty of Medicine, Universiti Kebangsaan Malaysia, Kuala Lumpur, Malaysia. The authors declare that there are no conflicts of interest.

## REFERENCES

1. Reaven G. Metabolic syndrome: pathophysiology and implications for management of cardiovascular disease. *Circulation*. 2002;106:286-8, doi: 10.1161/01.CIR.0000019884.36724.D9.

2. Roberts SR, Mayer J, Heyman MB, editors. Dietary fat intake and regulation of energy balance: implications for obesity. *Proceeding of the Dietary Composition and Obesity: Do We Need to Look Beyond Dietary Fat?*; 2000 April 17 - 21; Washington, DC. J. Nutr. 2000;130:284-8.
3. Cinti S. The adipose organ. In: Fantuzzi G, Mazzone T, editors. *Nutrition and health: adipose tissue and adipokines in health and disease*. Totowa: Human Press Inc; 2007. p. 3-19.
4. Jernas M, Palming J, Sjöholm K, Jennische E, Svensson PA, Gabrielsson BG, et al. Separation of human adipocytes by sizes: hypertrophic fat cells display distinct gene expression. *FASEB J*. 2006;20:832-9.
5. Stimson RH, Walker BR. 11 $\beta$ -hydroxysteroid dehydrogenase Type 1 and obesity. In: Donohoue PA, editor. *Contemporary endocrinology: energy metabolism and obesity: research and clinical applications*. Totowa: Human Press Inc; 2007. p. 175-96.
6. Tomlinson JW, Walker EA, Bujalska IJ, Draper N, Lavery GG, Cooper MS, et al. 11 $\beta$ -hydroxysteroid dehydrogenase type 1: tissue specific regulator of glucocorticoid response. *Endocr Rev*. 2004;25:831-66, doi: 10.1210/er.2003-0031.
7. Stulnig TM, Waldhausl W. Review: 11 $\beta$ -Hydroxysteroid dehydrogenase type 1 obesity and type 2 diabetes. *Diabetologia*. 2004;47:1-11, doi: 10.1007/s00125-003-1284-4.
8. Makimura H, Mizuno TM, Roberts J, Silverstein J, Beasley J, Mobbs CV. Adrenalectomy reverses obese phenotype and restores hypothalamic melanocortin tone in leptin-deficient ob/ob mice. *Diabetes*. 2000;49:1917-23, doi: 10.2337/diabetes.49.11.1917.
9. Tung YL, Hewson AK, Dickson SL. Glucocorticoid-dependent stimulation of adiposity and appetite by a ghrelin mimetic in the rat. *Eur J Endocrinol*. 2004;150:905-11.
10. Ima-Nirwana S, Suhainiza S. Effects of tocopherols and tocotrienols on body composition and bone calcium content in adrenalectomized rats replaced with Dexamethasone. *J Med Food*. 2004;7:45-51, doi: 10.1089/109662004322984699.
11. Livingstone DEW, Kenyon CJ, Walker BR. Mechanisms of dysregulation of 11 $\beta$ -hydroxysteroid dehydrogenase type 1 in obese Zucker rats. *J Endocrinol*. 2000;167:533-9, doi: 10.1677/joe.0.1670533.
12. Ima-Nirwana S, Fakhruddin H. Palm vitamin E protects bone against Dexamethasone-induced osteoporosis in male rats. *Med J Malaysia*. 2002;57:136-43.
13. Moison MP, Seckl JR, Edwards CRW. 11 $\beta$ -hydroxysteroid dehydrogenase bioactivity and messenger RNA expression in rat forebrain: localization in hypothalamus, hippocampus and cortex. *Endocrinology*. 1990;127:1450-5, doi: 10.1210/endo-127-3-1450.
14. Archer ZO, Rayner DV, Rozman J, Klingenspor M, Mercer JG. Normal distribution of body weight gain in male Sprague-Dawley rats fed a high-energy diet. *Obes Res*. 2003;11:1376-83, doi: 10.1038/oby.2003.186.
15. Ma K, Mallidis C, Bhasin S, Mahabadi V, Artaza J, Gonzalez-Cadavid N, et al. Glucocorticoid-induced skeletal muscle atrophy is associated with upregulation of myostatin gene expression. *Am J Physiol Endocrinol Metab*. 2003;285:363-71.
16. Rooman K, Koster JG, Bloemen R, Gresnigt R, van Buul-Offers SC. The effect of dexamethasone on body and organ growth of normal and IGF-II-transgenic mice. *J Endocrinol*. 1999;163:543-52, doi: 10.1677/joe.0.1630543.
17. Freedman MR, Horwitz BA, Stern JS. Effect of adrenalectomy and glucocorticoid replacement on development of obesity. *Am J Physiol*. 1986;250:595-607.
18. DiGirolamo M, Fine JB, Tagra K, Rossmanith R. Qualitative regional differences in adipose tissue growth and cellularity in male Wistar rat fed ad libitum. *Am J Physiol Regul Integr Comp Physiol*. 1998;274:1460-7.
19. Ayida AW, Wan Nazaimoon WM, Fariyah HS, Azian AL. Effect of ovariectomy, *Labisia pumila* var *alata* treatment and estrogen replacement therapy on the morphology of adipose tissue in ovariectomized Sprague Dawley rats. *J Med*. 2007;1:1.
20. Balachandran A, Guan H, Sellan M, van Uum S, Yang K. Insulin and Dexamethasone dynamically regulate adipocyte 11 $\beta$ -hydroxysteroid dehydrogenase type 1. *Endocrinology*. 2008;149:4069-79, doi: 10.1210/en.2008-0088.
21. Bujalska IJ, Durrani OM, Abbott J, Onyimba CU, Khosla P, Moosavi AH, et al. Characterisation of 11 $\beta$ -hydroxysteroid dehydrogenase 1 in human orbital adipose tissue: a comparison with subcutaneous and omental fat. *J Endocrinol*. 2007;192:279-88, doi: 10.1677/JOE-06-0042.