

## CASE REPORT

# Heart Transplantation in Becker Muscular Dystrophy Patient: Case-Report of a 15-Year Follow-up

Marcio Madeira, Sara Ranchordás, Tiago Nolasco, Marta Marques, Maria José Rebocho, José Neves

Hospital de Santa Cruz, Centro Hospitalar de Lisboa Ocidental, Carnaxide – Portugal

### Introduction

Becker muscular dystrophy is a rare genetic disease with a birth incidence of approximately 1:30000 in males.<sup>1</sup> The disease results from a X-linked recessive mutation on the gene located at Xp21, which encodes the dystrophin protein.<sup>1</sup> Clinical manifestations include progressive skeletal muscle weakness and dilated cardiomyopathy which can lead to refractory heart failure.<sup>2</sup> There is no correlation between the severity of cardiac manifestations and the genetic abnormalities.<sup>2</sup>

### Case report

We present a clinical report of a patient with dilated cardiomyopathy by Becker muscular dystrophy that underwent cardiac transplantation and has a 15 years' follow-up.

Idiopathic dilated cardiomyopathy was diagnosed in a 20-year-old man with a family history of two cousins with dilated cardiomyopathy, asthenia, dyspnea and orthopnea with progressive worsening. The patient got progressively worse and at 31-years-old he was classified as NYHA (New York Heart Association) class IV.

At the age of 34 years, the patient became refractory to optimal medical therapy, with a maximal oxygen consumption of 13 mL/Kg/min. Transplantation was indicated, which was an uneventful surgery with 200 minutes of ischemic time. The donor was a 33-year-old female with traumatic brain death and negative crossmatch. Pathologic exam revealed dilated cardiomyopathy and a

type III lesion according to the American Heart Association classification of atherosclerotic lesions.

The immunosuppression included induction with anti-thymocyte globulin and subsequently triple therapy with cyclosporine, mycophenolic acid and prednisone.

Several complications occurred during postoperative period including complete atrioventricular block and mechanical ventilation for three days due to a pulmonary infection with *Aspergillus fumigatus* isolated from a bronchoalveolar lavage.

There were two episodes of severe acute rejection: acute rejection grade 3R two months after transplantation, treated with muromonab-CD3, and a grade 2R rejection one year after transplantation that was treated with high-dose corticoid therapy.

Allograft vasculopathy was diagnosed by intravascular ultrasound on the anterior descending coronary artery and a 60% lesion on right coronary artery, four years after transplant. Six years after transplant, he had a 1.2 mm intimal hyperplasia on the left anterior descending artery (LAD) that was classified as ISHLTCav 2 and the right coronary artery (RCA) was stable. Seven years after transplant, the LAD lesion had improved and a stent angioplasty was performed on the RCA.

After seven years due to mild renal dysfunction and allograft vasculopathy, cyclosporine was replaced by everolimus.

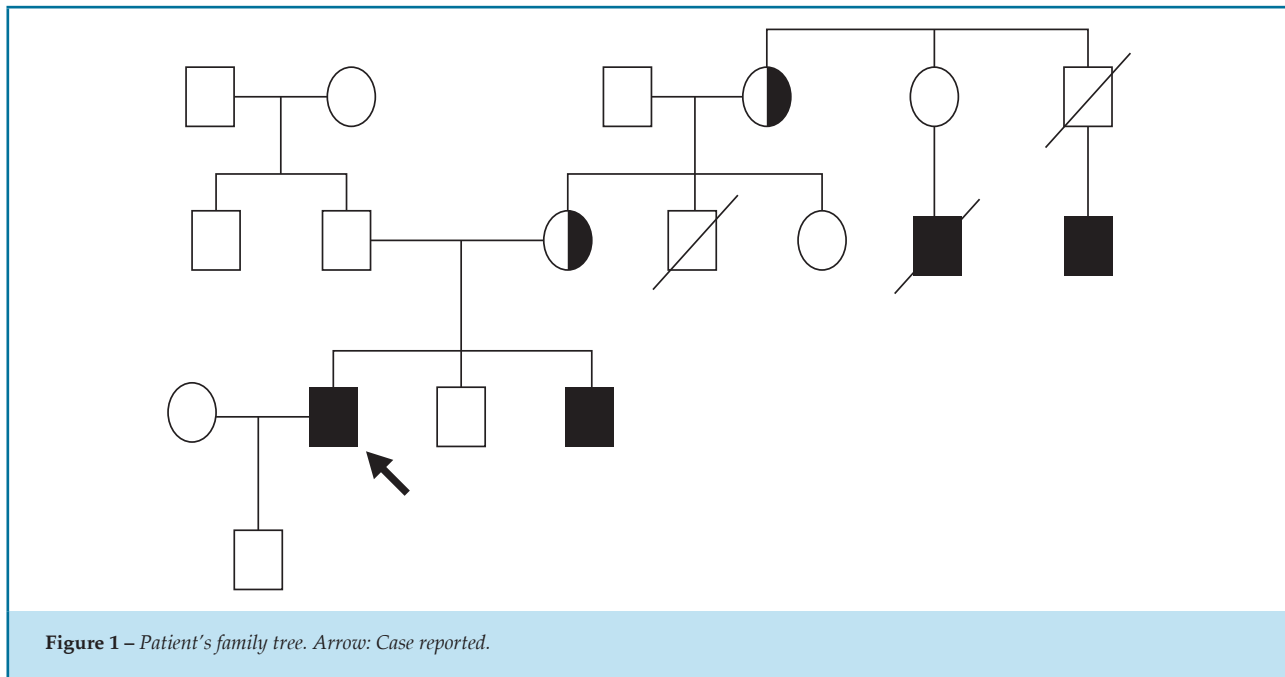
Eleven years after discharge, progressive muscular weakness in the lower limbs and myopathic gait were apparent. Study of neuromuscular diseases was performed. The genetic exam found deletion of 48 and 49 exons on the dystrophin gene, which confirmed the diagnosis of Becker muscular dystrophy. A family study was done leading to the identification of a brother and two uncles with the disease and his mother and grandmother as carriers (Figure 1).

### Keywords

Muscular Dystrophy Duchenne/genetics; Myotonia Congenita, Heart Transplantation; Aftercare.

#### Mailing Address: Marcio Madeira

Hospital de Santa Cruz, Cirurgia Cardiorácica. Av. Prof. Dr. Reinaldo dos Santos 27-29, Postal Code: 2790-134. Carnaxide – Portugal  
E-mail: madeira.marcio@gmail.com



Currently, after 15 years of follow-up, he continues to be completely autonomous and works actively at his job. He has a good quality of life showing only mild weakness of his lower limbs.

No abnormalities were found in the coronary angiography or in the myocardial perfusion scintigraphy. Magnetic resonance imaging revealed moderate left ventricular hypertrophy and a delayed subendocardial enhancement of the interventricular septum of ischemic etiology (Figure 2).

## Discussion

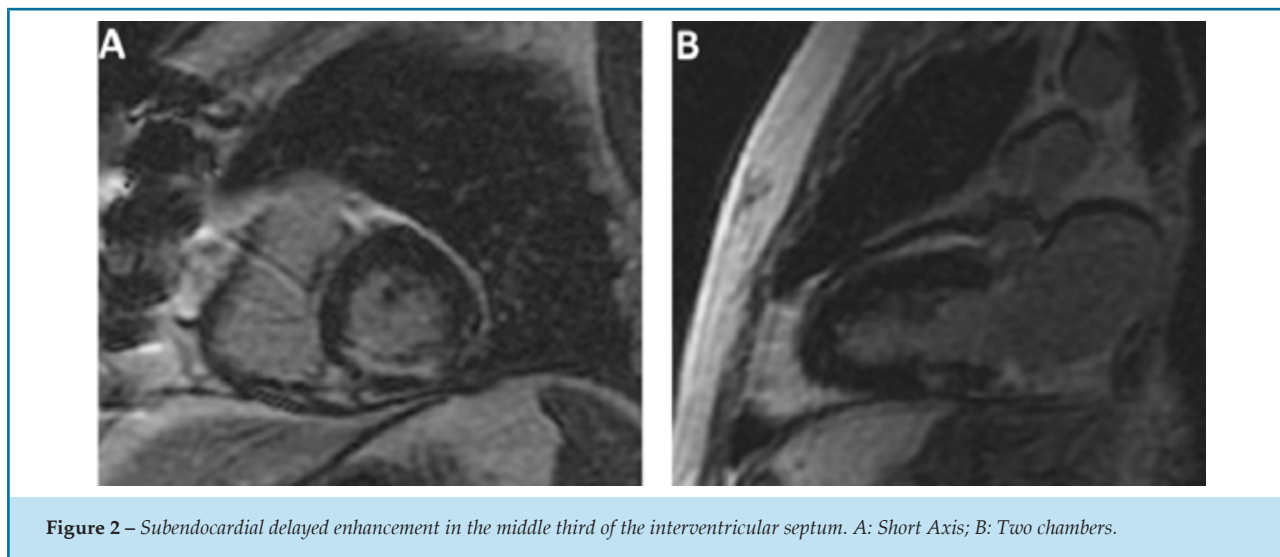
Becker muscular dystrophy is a heterogeneous disease with slow progression.<sup>3</sup> During the first decade of life, patients are usually asymptomatic and become symptomatic after the second decade usually with difficulties in climbing stairs after the third decade.<sup>2</sup> Cardiac involvement in Becker muscular dystrophy is usually present throughout life. The majority of patients have an asymptomatic cardiac involvement, but up to one third of patients develop dilated cardiomyopathy with variable degrees of heart failure.<sup>2</sup> In some cases, severe heart failure symptoms can precede muscular symptoms for years.<sup>4</sup>

In the present case, the patient remained asymptomatic until the second decade of life, and was

initially diagnosed with idiopathic cardiomyopathy. Muscular dystrophy was diagnosed through genetic tests after the onset of muscular weakness on the fourth decade of life.

Therapy for cardiac involvement in Becker muscular dystrophy is symptomatic and similar to cardiac diseases due to other causes.<sup>2</sup> Intractable chronic heart failure, classified as NYHA class III or IV, may be the indication for heart transplantation.<sup>2</sup> Corticosteroid therapy can have a beneficial impact in preventing muscular dystrophy progression and are recommended as a therapeutic option in these diseases.<sup>5</sup> In the current report, the orthotopic heart transplantation was performed when heart failure became refractory to the optimal medical therapeutic. The progressive muscular weakness was apparent eleven years after the transplant, maybe due to the effect of long term corticoid therapy.

Similar outcomes have been reported between muscular dystrophy patients with heart transplant and matched non-ischemic patients in terms of survival, infection, rejection and allograft vasculopathy.<sup>5</sup> These findings support the indication for transplantation on patients with muscular dystrophy, despite the possible progressive muscular weakness and the limited functional capacity.<sup>5</sup>



## Conclusion

This report presents a 15-year follow-up of a Becker muscular dystrophy patient submitted to heart transplantation. The patient is classified as NYHA class I and currently has a good quality of life. To our knowledge, this is the longest reported follow-up of a Becker muscular dystrophy patient with heart transplant.

## Author contributions

Conception and design of the research: Madeira M, Rebocho MJ. Acquisition of data: Madeira M, Ranchordás S. Analysis and interpretation of the data: Madeira M, Ranchordás S. Writing of the manuscript:

Madeira M, Ranchordás S, Nolasco T, Rebocho MJ, Neves J. Critical revision of the manuscript for intellectual content: Madeira M, Nolasco T, Marques M, Rebocho MJ, Neves J.

## Potential Conflict of Interest

No potential conflict of interest relevant to this article was reported.

## Sources of Funding

There were no external funding sources for this study.

## Study Association

This study is not associated with any thesis or dissertation work.

## References

1. American Academy of Pediatrics Section on Cardiology and Cardiac Surgery. Cardiovascular health supervision for individuals affected by Duchenne or Becker muscular dystrophy. *Pediatrics*. 2005;116(6):1569-73. Doi: 10.1542/peds.2005-2448.
2. Finsterer J, Stöllberger C. Cardiac involvement in Becker muscular dystrophy. *The Can J Cardiol*. 2008;24(10):786-92. PMID: 18841259.
3. Melacini P, Fanin M, Danieli GA, Fasoli G, Villanova C, Angelini C, et al. Cardiac involvement in Becker muscular dystrophy. *J Am Coll Cardiol*. 1993;22(7):1927-34.
4. Finsterer J, Bittner RE, Grimm M. Cardiac involvement in Becker's muscular dystrophy, necessitating heart transplantation, 6 years before apparent skeletal muscle involvement. *Neuromuscul Disord*. 1999;9(8):598-600. PMID: 10619719
5. Wu RS, Gupta S, Brown RN, Yancy CW, Wald JW, Kaiser P, et al. Clinical outcomes after cardiac transplantation in muscular dystrophy patients. *J Heart Lung Transplant*. 2010;29(4):432-8. Doi: 10.1016/j.healun.2009.08.030.

