

Oral cavity lipoma: a study of 101 cases in a Brazilian population

Lipoma de cavidade oral: um estudo de 101 casos em uma população brasileira

Rafael L. V. Osterne¹; Renata M. B. Lima-Verde²; Eveline Turatti¹; Cassiano Francisco W. Nonaka³; Roberta B. Cavalcante¹

1. Universidade de Fortaleza (Unifor), Fortaleza, Ceará, Brazil. 2. Centro Universitário Christus (Unichristus), Fortaleza, Ceará, Brazil.
3. Universidade Estadual da Paraíba (UEPB), Campina Grande, Paraíba, Brazil.

ABSTRACT

Introduction: Lipomas are benign soft tissue tumors commonly found in the human body. Although common in the head and neck region, in the oral cavity region they are uncommon, accounting for only 1% to 4% of benign oral cavity lesions. **Objective:** This study aims to identify the clinical and histopathological characteristics of oral cavity lipomas subjected to histopathological analysis at a pathology laboratory in the city of Fortaleza, Ceará, Brazil. **Methods:** Data from all cases of oral lesions diagnosed as lipoma and confirmed by histopathological examination over a period of 10 years were collected, including: gender, age, anatomical location, clinical diagnosis and histopathological subtypes. **Results:** During the period evaluated, 101 cases were diagnosed as lipomas, representing 1.01% of oral cavity biopsies. Females were more affected, with a male/female ratio of 1: 1.8, and with a peak of incidence between 50 and 70 years of age. The buccal mucosa was the most affected anatomical region, followed by the lower lip. Classic lipoma and fibrolipoma were the histological variants of lipoma most commonly found in the oral cavity, with 64 cases of classic lipoma and 29 cases of fibrolipoma. Other histological variants were: sialolipoma, angioliipoma, chondrolipoma, myxolipoma and intramuscular lipoma. **Conclusion:** Lipomas are uncommon lesions in the oral cavity, which present a higher prevalence in the buccal mucosa of adults, aged between 50 and 70 years, and with higher female preference.

Key words: lipoma; pathology; mouth neoplasms.

RESUMO

Introdução: Lipomas são tumores benignos de tecido mole comumente encontrados no corpo humano. Embora comuns na região de cabeça e pescoço, são raros na região da cavidade oral, representando apenas 1% a 4% das lesões benignas manifestadas nessa cavidade. **Objetivo:** O presente trabalho tem como objetivo identificar as características clínicas e histopatológicas de lipomas de cavidade oral; os materiais coletados foram submetidos a análise histopatológica em um laboratório de patologia da cidade de Fortaleza, Ceará, Brasil. **Métodos:** Dados referentes aos últimos 10 anos, como gênero, idade, localização anatômica, diagnóstico clínico e subtipos histopatológicos, foram coletados de todos os casos de lesões orais diagnosticados como lipoma e confirmados através de exames histopatológicos. **Resultados:** Durante o período avaliado, 101 casos foram diagnosticados como lipomas, representando 1,01% das biópsias de cavidade oral. O sexo feminino foi o mais acometido, com proporção homem/mulher de 1:1,8, e pico de incidência entre 50 e 70 anos de vida. A mucosa jugal foi a região anatômica mais afetada, seguida do lábio inferior. Lipoma clássico e fibrolipoma foram as variantes histológicas de lipoma mais encontradas na cavidade oral, com 64 casos de lipoma clássico e 29 de fibrolipoma. Outras variantes histológicas encontradas foram sialolipoma, angioliipoma, condrolipoma, mixolipoma e lipoma intramuscular. **Conclusão:** Os lipomas são lesões incomuns em cavidade oral e apresentam maior prevalência em mucosa jugal de adultos, com idades entre 50 e 70 anos, além de manifestarem predileção pelo sexo feminino.

Unitermos: lipoma; patologia; neoplasias bucais.

RESUMEN

Introducción: Lipomas son tumores benignos del tejido blando comúnmente encontrados en el cuerpo humano. Aunque comunes en la región de la cabeza y cuello, son raros en la cavidad oral, representando solo del 1% al 4% de las lesiones benignas en esa cavidad. **Objetivo:** El presente estudio pretende identificar las características clínicas e histopatológicas de lipomas de la cavidad oral; los materiales recolectados fueron analizados en un laboratorio de patología de la ciudad de Fortaleza, Ceará, Brasil. **Métodos:** Datos relativos a los últimos 10 años, como género, edad, localización anatómica, diagnóstico clínico y subtipos histopatológicos, se recolectaron de todos los casos de lesiones orales con el diagnóstico de lipoma confirmado mediante exámenes histopatológicos. **Resultados:** A lo largo del período evaluado, 101 casos fueron diagnosticados como lipomas, representando el 1,01% de las biopsias de la cavidad oral. El sexo femenino fue lo más afectado, con proporción hombre/mujer de 1:1,8, y pico de incidencia entre 50 y 70 años de vida. La mucosa yugal fue la región anatómica más afectada, seguida del labio inferior. Lipoma clásico y fibrolipoma fueron las variantes histológicas de lipoma más encontradas en la cavidad oral, con 64 casos de lipoma clásico y 29 de fibrolipoma. Otras variantes histológicas encontradas fueron sialolipoma, angioliipoma, condrolipoma, mixolipoma y lipoma intramuscular. **Conclusión:** Los lipomas son lesiones poco frecuentes en la cavidad oral y presentan mayor prevalencia en mucosa yugal de adultos con edades entre los 50 y los 70 años de vida, además de manifestaren preferencia por el sexo femenino.

Palabras clave: lipoma; patología; neoplasias bucales.

INTRODUCTION

Lipomas are the most common benign soft tissue tumors, composed of mature adipocytes⁽¹⁻³⁾. Although 20% of all cases occur in the head and neck area, the oral cavity is an uncommon site, and only 1% to 4% appears at this location^(1,2). Several studies have demonstrated that lipomas represent 0.1% to 5% of oral cavity tumors^(1,4), and Juliase *et al.* (2010)⁽⁵⁾ reported that lipomas represented 0.4% of all oral cavity lesions in an oral pathology service. In a previous study in Fortaleza, Ceará, Brazil, this benign neoplasm accounts for 2% of all oral cavity benign neoplasms⁽⁶⁾.

In the oral cavity, lipomas typically present as a well-circumscribed, slow-growing, solitary, painless submucosal nodule. Clinical diagnosis is usually apparent, but they can be confused with other neoplasms of oral cavity⁽⁷⁾. The buccal mucosa is the most affected site, although the lipoma can appear in several locations^(5,7,8). This neoplasm can occur in all ages, despite being uncommon at young ages^(5,9). Some case series have demonstrated a slight female predilection^(1,3,7).

According to histopathology aspects, lipomas can be classified in simple lipoma and variants, such as fibrolipoma, chondrolipoma, osteolipoma, intermuscular and intramuscular lipoma, angioliipoma, myolipoma, myelolipoma, benign lipoblastoma, chondroid lipoma, spindle-cell lipoma, pleomorphic lipoma and sialolipoma⁽⁸⁾. The simple lipoma and the fibrolipoma are the most common histopathological variants^(1,5).

As most of cases of lipoma variants are described in literature as case reports, case series are useful in knowing the real prevalence

of these histopathological variants of oral cavity lipomas. This study analyzed the clinicopathological features of benign oral cavity lipomas in a Brazilian population.

METHODS

The files from 2000 to 2015 of the Oral Pathology Department, University of Fortaleza (Unifor), were reviewed and all cases with histopathological diagnosis of lipoma of the oral cavity were retrieved. Information regarding patients' gender and age, site, size and duration of the lesions before diagnosis and clinical diagnosis were obtained from the patients' records.

All hematoxylin-eosin (HE)-stained slides were reviewed and classified as proposed by Gnepp (2009)⁽¹⁰⁾, and Weiss and Goldblum (2014)⁽¹¹⁾, and included lipoma, fibrolipoma, chondrolipoma, osteolipoma, intermuscular and intramuscular lipoma, angioliipoma, myolipoma, myelolipoma, benign lipoblastoma, chondroid lipoma, spindle-cell lipoma, pleomorphic lipoma and salivary gland lipoma.

The research was developed in accordance with Resolution 466/12 of the National Committee for Ethics in Research (CONEP)/National Health Council, which deals with researches involving humans, and the Code of Medical Ethics (1998). This cross-sectional study was approved by the Institutional Ethics Committee (ethics approval number 1104619). The data was collected and the results obtained in the SPSS Statistics 20.0 software were described by using simple descriptive statistics.

RESULTS

One hundred and six cases of lipoma were identified during the study, but five cases were excluded because they affected the maxillofacial region (four in parotid region, one in submandibular region), resulting in 101 cases of oral cavity lipoma, representing 1.01% of all biopsy specimens stored in the files of the Oral and Maxillofacial Pathology Service of Unifor. Females were affected in 64.3% of cases, with a female/male ratio of 1.8:1. Patients' age ranged from 10 to 84 years, with a peak of incidence between the fifth and sixth decades of life, presenting 56.4% of all cases (age distribution is shown in the **Table** and the **Figure**). The buccal mucosa was the most common location ($n = 45$; 44.5%), followed by the lower lip ($n = 12$; 11.8%), the retromolar area ($n = 10$; 9.9%), and the tongue ($n = 7$; 6.9%). All sites are presented in the Table.

Fibroma/fibroepithelial hyperplasia was the most cited clinical diagnosis in 43 cases; lipoma was cited in 35 cases; inflammatory fibrous hyperplasia was cited in five cases; mucocele, in four cases; neural tumors, in two cases (encapsulated neuroma and neurofibroma); diagnosis has not been informed in eight cases; and hemangioma, condyloma, gingival hyperplasia and others were cited once each.

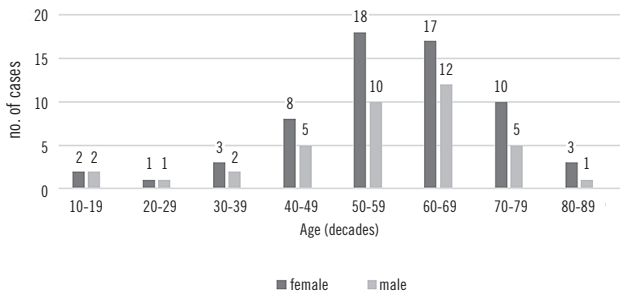


FIGURE – Age and sex distribution of the oral cavity lipomas

Classic lipomas, followed by fibrolipoma, were the most frequent histological variants of lipoma found in the oral cavity, with 64 and 29 cases each. The mean age for classic lipoma was 56.2 years; and for fibrolipoma, 49 years. A female preference was found for both lipoma and fibrolipoma, with a male/female ratio of 1:1.3 for classic lipomas and 2.2:1 for fibrolipomas. The other histological variants found were sialolipoma, with three cases: a 31-year-old, a 38-year-old and a 70-year-old, all females; angioliipoma, with two cases: a 54-year-old and an 81-year-old, both females; chondrolipoma, with one case: a 68-year-old female; myxolipoma, with one case: a 66-year-old male; and intramuscular lipoma, with also one case: a 24-year-old male.

DISCUSSION

Lipomas and lipoma variants are common soft tissue tumors in humans, but are infrequently lesions in the oral cavity, with an overall incidence between 1% and 4.4% of all benign oral lesions^(1,2,5); just a single study report higher incidence (7.5%)⁽³⁾. An earlier study in Fortaleza, Ceará, Brazil, showed that this benign neoplasm is responsible for 2% of benign neoplasms in the oral cavity⁽⁶⁾. In the present study, oral lipomas represented 1.01% of all oral lesions stored in the files of the Oral and Maxillofacial Pathology Service of Unifor.

The etiology of lipomas remains unknown. Although some authors suggest that lipomas are more common in obese individuals⁽²⁾, the metabolism of lipomas is completely independent of the body fat⁽³⁾. Some authors reported no gender difference⁽⁴⁾, but oral and maxillofacial lipomas are more common in men^(8,9). When considering only oral cavity lipomas, this benign neoplasm affect more females than males^(1,3,5,7), with a female:male ratio of 1.8:1 in the present study.

TABLE – Anatomical sites of oral cavity lipomas; Fortaleza, Brazil, 2015

	Classic lipoma	Fibrolipoma	Sialolipoma	Angioliipoma	Chondrolipoma	Myxolipoma	Intramuscular lipoma	Total
Buccal mucosa	32	11	-	1	-	-	1	45 (44.5%)
Lower lip	10	2	-	-	-	-	-	12 (11.8%)
Retromolar area	4	5	1	-	-	-	-	10 (9.9%)
Tongue	4	2	-	-	1	-	-	7 (6.93%)
Floor of mouth	4	1	-	-	-	-	-	5 (4.95%)
Palate	-	3	1	1	-	-	-	5 (4.95%)
Upper lip	-	-	-	-	-	1	-	1 (0.99%)
Others	8	2	1	-	-	-	-	11 (10.8%)
Unknown	2	3	-	-	-	-	-	5 (4.95%)

Lipomas can occur in all ages, but are lesions frequently diagnosed in adults^(3, 5, 7), with few cases being diagnosed in pediatric patients^(1, 8). Avelar *et al.* (2008)⁽⁹⁾ reported a case of lipoma in a 7-month-old patient. In the present series, lipomas occurred in a wide age range, from 10 to 84-year-olds, and four cases of classic lipoma were diagnosed under the age of 19: two cases in a 10-year-old and a 13-year-old, both males, and two cases in 17-year-old females. Of all cases diagnosed in this study, 86.27% occurred in patients older than 40 years old, with a median age of 56.8 years. In the literature, the median age for diagnosis ranges from 50.2 to 60 years^(1, 3, 4, 8).

Intraoral lipomas can occur in any location of the oral cavity^(1, 7, 9, 12), but the buccal mucosa is the most affected single intraoral site^(7, 8). Coherently, in this research, the buccal mucosa was the most frequent site for lipomas (44.1%), followed by lower lip area, retromolar, tongue, floor of the mouth and palate. The palate is an unusual location for a lipoma. In a study on 126 cases of oral and maxillofacial lipomas, only six cases involved the palate, three cases being classic lipomas and three cases being spindle-cell lipomas⁽⁸⁾. In the present study, five lipomas affected the palate: two of the cases were diagnosed as fibrolipoma; lipoma, sialolipoma and angiolipoma presented one case each.

Oral cavity lipomas are usually not a diagnostic challenge for the clinician when the tumor is in a superficial location and presents a yellowish color; and it is mainly represented as a solitary and asymptomatic, smooth-surfaced nodular mass, that can be sessile or pedunculated⁽¹⁾. Deep infiltrating lesions, or lesions without the typical yellowish color may represent a diagnostic challenge, and may have as differential diagnosis many other lesions, such as fibroma, granular cell tumor, salivary gland neoplasm and other benign soft tissue tumors; also dermoid cyst and oral lymphoepithelial cyst can be included in the differential diagnosis. In the present study, the most quoted clinical diagnosis was fibroma/fibroepithelial hyperplasia (42.2%), followed by lipoma (33.3%). In agreement with a study of de Freitas *et al.* (2009)⁽⁷⁾, also in a Brazilian population, lipoma was mentioned in the clinical diagnosis in 65.8% of cases, and fibroma in only 19.23% of cases. Intraoral lipomas can also be confused with herniated adipose tissue^(1, 5).

Classic lipomas, followed by fibrolipoma are the most common histological variants of lipoma found in the oral cavity. The prevalence of the classic lipoma can range from 41.5% to 92.86% of all oral cavity lipomas^(1, 3, 5, 7, 9). In this study, classic lipoma represented 63.3% of all histological variants. This large difference in prevalence of histological variants of lipomas may be due to geographic and racial differences, or may represent differences in diagnostic criteria⁽¹⁾. Classic lipoma is a well-delimited lesion

composed of lobules of mature adipocytes, which can show a slight variation in size and shape. Thin septa of connective tissue separate the lobules^(2, 3). Fibrolipomas are characterized by the presence of mature adipocytes interspersed with broad bands or fascicles of dense connective tissue⁽¹⁾. Features such as being well circumscribed and thinly encapsulated help differing lipoma and fibrolipoma from herniated adipose tissue and fibrous polyp with fat entrapment, respectively^(10, 11).

Lipoma and fibrolipoma occurred more in buccal mucosa. Although some authors reported male/female ratio of 1:1 for fibrolipomas⁽¹⁾, in the current survey a female predilection for both lipoma and fibrolipoma was found (male/female ratio of 1:1.3 for classic lipomas and 2.2:1 for fibrolipomas). A higher female predominance of fibrolipomas (3.6:1) was found by Juliasse *et al.* (2010)⁽⁵⁾. In this article, the average age for classic lipoma was 56.2 years and for fibrolipomas, 49 years.

Sialolipoma was first described by Nagao *et al.* (2001)⁽¹³⁾, and was recognized by the World Health Organization (WHO) in 2005, and only few cases were described^(5, 14-16). This variant of lipoma is characterized by a lipomatous proliferation containing glandular structures with varying degrees of acinar atrophy and ductal ectasia, surrounded by a thin fibrous tissue^(13, 16). This lesion has been described to affect all ages, from 7 weeks to 84 years⁽¹⁶⁾. In this research, three cases were found: one case occurred in a 70-year-old female, diagnosed in the retromolar area. The other ones were in a 31-year-old female, diagnosed in the palate area, and a 38-year-old female, diagnosed in the lower alveolar ridge. A male predominance of sialolipoma was described by some^(14, 17), but Jang *et al.* (2009)⁽¹⁵⁾, in a review of 28 cases found no gender predilection. Controversially, all cases of sialolipoma reported by Juliasse *et al.* (2010)⁽⁵⁾ were observed in female patients. Sialolipomas are more common in major salivary glands: the parotid gland is the single most affected site^(14, 16). No anatomical site predilection was described for oral sialolipomas⁽¹⁴⁾.

A vascular variant of lipoma, angiolipoma, usually appears as subcutaneous nodules consisting in mature adipocytes, intermingled with small thin-walled vessels, which can contain fibrin thrombi⁽²⁾. First described as a distinct entity by Bowen (1912)⁽¹⁸⁾, angiolipoma is frequently diagnosed in trunk and extremities^(2, 19), and is a rare oral cavity lesion⁽¹⁹⁻²¹⁾. Oral angiolipoma seems to affect more males than females, with a male/female ratio of 1.5:1. This variant of lipoma has been described to affect patients from 4 to 81 years old, with a mean age of 37 years, and the buccal mucosa is the most involved site⁽¹⁹⁾. In the present study, one case occurred in the buccal mucosa of an 81-year-old female; and the other case, in the palate of a 54-year-old female.

Chondrolipoma is a rare variant of lipoma in the oral cavity⁽²²⁾, and is characterized by the proliferation of mature adipocytes associated with deposition of mature cartilaginous tissue^(23, 24). It has been reported to affect mainly the tongue and lips, with no gender predilection, occurring in patients from 2 to 72 years⁽²²⁻²⁶⁾. The case in the present study occurred in the tongue of a 68-year-old female. There is no consensus whether the cartilaginous tissue is a metaplastic process in a lipoma or if the cartilaginous components are derived from undifferentiated pluripotent mesenchymal cells^(8, 11, 24). This unique variant of lipoma must not be confused with chondroid lipoma, a rare lesion in oral cavity⁽⁸⁾, characterized by the presence of lipoblasts, mature fat and chondroid matrix, which can resemble a myxoid liposarcoma or an extraskeletal myxoid chondrosarcoma⁽²⁾.

Other variants of lipoma, such as osteolipoma, spindle-cell lipoma, chondroid lipoma, benign lipoblastoma, that can appear in oral cavity^(1, 3, 5), are extremely rare lesions and were not found in the present series. Although the growth of oral lipomas is usually limited, they can reach great dimension, interfering with speech and mastication⁽²⁷⁾. The treatment for

oral cavity lipomas, including all the histologic variants, is simple conservative surgical excision, and recurrence is rare^(4, 9).

One limitation of this research was the fact that some of the histopathological request forms were not completely fulfilled, leaving some important information like age, gender, clinical and anatomic diagnosis with no answer, resulting in missing data. The information about race was not added in the results because the WHO recommends that patients have to categorize their race by themselves, what could create a false result in the study of the Brazilian population, which is mixed.

CONCLUSION

The results of this research found that there are a lot of similarities with other studies previously described in the literature. They confirmed that the oral cavity lipoma is uncommon and it affects more the buccal mucosa of adults between the 50th and the 70th decades of life. A gender predilection for females was found, with a male/female ratio of 1:1,8. The most common histological subtypes found were classic fibroma and fibrolipoma.

REFERENCES

1. Fregnani ER, Pires FR, Falzoni R, Lopes MA, Vargas PA. Lipomas of the oral cavity: clinical findings, histological classification and proliferative activity of 46 cases. *Int J Oral Maxillofac Surg*. 2003 Feb; 32(1): 49-53. PubMed PMID: 12653233.
2. Nielsen GP, Mandahl N. Lipoma. In: Fletcher CDM, Unni KK, Mertens F, editors. *World Health Organization Classification of Tumours. Pathology and genetics of tumours of soft tissue and bone*. IARC Press: Lyon; 2002. p. 20-2.
3. Epivations A, Markopoulos AK, Papayanatu P. Benign tumors of adipose tissue of the oral cavity: a clinicopathologic study of 13 cases. *J Oral Maxillofac Surg*. 2000 Oct; 58(10): 1113-7. PubMed PMID: 11021705.
4. Bandéca MC, de Pádua JM, Nadalin MR, Ozório JE, Silva-Sousa YT, da Cruz Perez DE. Oral soft tissue lipomas: a case series. *J Can Dent Assoc*. 2007 Jun; 73(5): 431-4. PubMed PMID: 17555654.
5. Juliassé LE, Nonaka CF, Pinto LP, de Freitas AR, Miguel MC. Lipomas of the oral cavity: clinical and histopathologic study of 41 cases in Brazilian population. *Eur Arch Otorhinolaryngol*. 2010 Mar; 267(3): 459-65. PubMed PMID: 19562364.
6. Studart-Soares EC, Costa FW, Sousa FB, Alves AP, Osterne RL. Oral lipomas in a Brazilian population: a 10-year study and analysis of 450 cases reported in the literature. *Med Oral Patol Oral Cir Bucal*. 2010 Sep 1; 15(5): e691-6. PubMed PMID: 20383107.
7. de Freitas MA, Freitas VS, de Lima AA, Pereira Jr. FB, dos Santos JN. Intraoral lipomas: a study of 26 cases in a Brazilian population. *Quintessence Int*. 2009 Jan; 40(1): 79-85. PubMed PMID: 19159027.
8. Furlong MA, Fanburg-Smith JC, Childers EL. Lipoma of the oral and maxillofacial region: site and subclassification of 125 cases. *Oral Surg Oral Med Oral Pathol Oral Radiol Endod*. 2004 Oct; 98(4): 441-50. PubMed PMID: 15472660.
9. Avelar RL, Carvalho RWF, Falcão PGCB, Antunes AA, Andrade ESS. Lipomas da região oral e maxilofacial: estudo retrospectivo de 16 anos no Brasil. *Rev Port Estomatol Cir Maxilofac*. 2008 Oct-Dec; 49: 207-11.
10. Gnepp DR. *Diagnostic surgical pathology of the head and neck*. WB Saunders. 2nd ed. Philadelphia: WB Saunders; 2009.
11. Weiss SW, Goldblum JR. *Enzinger and Weiss's soft tissue tumors*. 6th ed. St Louis: Mosby.
12. Seldin HM, Seldin SD, Rakower W, Jarrett WJ. Lipomas of the oral cavity: report of 26 cases. *J Oral Surg*. 1967 May; 25(3): 270-4. PubMed PMID: 5227949.
13. Nagao T, Sugano I, Ishida Y, et al. Sialolipoma: a report of seven cases of a new variant of salivary gland lipoma. *Histopathology*. 2001 Jan; 38(1): 30-6. PubMed PMID: 11135044.
14. Okada H, Yokoyama M, Hara M, Akimoto Y, Kaneda T, Yamamoto H. Sialolipoma of the palate: a rare case and review of the literature. *Oral Surg Oral Med Oral Pathol Oral Radiol Endod*. 2009 Oct; 108: 571-6. PubMed PMID: 19699118.
15. Jang YW, Kim SG, Pai H, Park JW, Lee YC, Rotaru H. Sialolipoma: case report and review of 27 cases. *Oral Maxillofac Surg*. 2009 Jun; 13(2): 109-13. PubMed PMID: 19347375.
16. Ponniah I, Lavanya N, Suresh KP. Island of salivary gland in adipose tissue: a report of three cases. *J Oral Pathol Med*. 2007 Oct; 36(9): 558-62. PubMed PMID: 17850441.

17. Ramer N, Lumerman S, Ramer Y. Sialolipoma: report of two cases and review of the literature. *Oral Surg Oral Med Oral Pathol Oral Radiol Endod.* 2007 Dec; 104(6): 809-13. PubMed PMID: 17482843.
18. Bowen JT. Multiple subcutaneous hemangiomas, together with multiple lipomas, occurring in enormous numbers in an otherwise healthy, muscular subject. *Am J Med Sci.* 1912; 144: 189-92.
19. Ida-Yonemochi H, Swelam W, Saito C, Saku T. Angiolipoma of the buccal mucosa: a possible role of mast cell derived VEGF in its enhanced vascularity. *J Oral Pathol Med.* 2005 Jan; 34(1): 59-61. PubMed PMID: 15610409.
20. Dalambiras S, Tilaveridis I, Iordaninidis S, Zaraboukas T, Epivatianos A. Infiltrating angiolipoma of a the oral cavity: report of a case and literature review. *J Oral Maxillofac Surg.* 2010 Mar; 68(3): 681-3. PubMed PMID: 19944512.
21. Altug HA, Sahin S, Sencimen M, Dogan N, Erdogan O. Non-infiltrating angiolipoma of the cheek: a case report and review of the literature. *J Oral Science.* 2009 Mar; 51(1): 137-9. PubMed PMID: 19325211.
22. Nonaka CF, Pereira KM, de Andrade Santos PP, de Almeida Freitas R, da Costa Miguel MC. Sialolipoma of minor salivary glands. *Ann Diag Pathol.* 2011 Feb; 15(1): 6-11. PubMed PMID: 20952301.
23. Hietanen J, Mäkinen J. Chondrolipoma of the tongue. A case report. *Int J Oral Maxillofac.* 1997 Apr; 26(2): 127-8. PubMed PMID: 9151169.
24. Goel G, Khadilkar UN, Kumar S. Chondrolipoma of tongue. *Kathmandu Univ Med J.* 2008 Oct-Dec; 6(24): 505-7. PubMed PMID: 19483434.
25. McAndrew PG, Greenspan JS. Lipoma of lip with cartilage formation. *Br Dent J.* 1976 Apr; 140(7): 239-40. PubMed PMID: 1063011.
26. Vázquez RF, Salas MJ, Perez SR, Ocaña JM. Chondrolipoma of the tongue in an infant: a case report. *An Esp Pediatr.* 1993 Dec; 39(6): 553-4. PubMed PMID: 8166417.
27. Chidzonga MM, Mahomva L, Marimo C. Gigantic tongue lipoma: a case report. *Med Oral Patol Oral Cir Bucal.* 2006 Aug 1; 11(5): E437-9. PubMed MID: 16878062.

CORRESPONDING AUTHOR

Rafael Lima Verde Osterne  0000-0002-7196-7628
e-mail: rlimaverde@unifor.br



This is an open-access article distributed under the terms of the Creative Commons Attribution License.