



## Review Article

# Congenital abnormalities and anatomical variations of the vermiform appendix and mesoappendix



Elciana de Paiva Lima Vieira <sup>a,b,\*</sup>, Larissa Milton Bonato<sup>c</sup>,  
Gabriela Gonçalves Pereira da Silva<sup>d</sup>, Jonas Lírio Gurgel<sup>d</sup>

<sup>a</sup> Universidade Federal Fluminense (UFF), Departamento de Educação Física, Niterói, RJ, Brazil

<sup>b</sup> Universidade Salgado de Oliveira, Departamento de Nutrição, Niterói, RJ, Brazil

<sup>c</sup> Universidade Salgado de Oliveira, São Gonçalo, RJ, Brazil

<sup>d</sup> Universidade Federal Fluminense (UFF), Niterói, RJ, Brazil

### ARTICLE INFO

#### Article history:

Received 11 December 2018

Accepted 21 April 2019

Available online 27 May 2019

#### Keywords:

Vermiform appendix

Anatomical variation

Congenital abnormalities

### ABSTRACT

**Aim:** The purpose of this review was to present and discuss the anatomical variations and congenital abnormalities of the vermiform appendix and mesoappendix reported in recent years, and their associations with acute appendicitis and other associated pathologies.

**Methods:** The search was carried out in the following databases: PubMed, Science Direct, and SciELO.

**Results:** Thirty-seven studies were included in this review. Among the abnormalities of the vermiform appendix identified are agenesis and duplicity, and anatomical variations were related to length and positioning. Appendicular duplicity was a more frequent abnormality, mainly Type B2, associated with acute appendicitis, followed by agenesis, Type III. The first case of agenesis associated with acute appendicitis and volvulus-type duplicity of the appendix was identified. The most frequent position was retrocecal in adults and pelvic in children. In the mesoappendix, anatomical variations in its positioning, shape, absence, and length were identified.

**Conclusion:** This review sought to present and discuss the anatomical variations and congenital abnormalities of the vermiform appendix and mesoappendix reported in recent years, and their associations with acute appendicitis and other associated pathologies, contributing to aid in clinical diagnosis and surgical interventions in patients with suspected acute appendicitis.

© 2019 Sociedade Brasileira de Coloproctologia. Published by Elsevier Editora Ltda. This is an open access article under the CC BY-NC-ND license (<http://creativecommons.org/licenses/by-nc-nd/4.0/>).

\* Corresponding author.

E-mail: [elcianavieira@yahoo.com.br](mailto:elcianavieira@yahoo.com.br) (E.P. Vieira).

<https://doi.org/10.1016/j.jcol.2019.04.003>

2237-9363/© 2019 Sociedade Brasileira de Coloproctologia. Published by Elsevier Editora Ltda. This is an open access article under the CC BY-NC-ND license (<http://creativecommons.org/licenses/by-nc-nd/4.0/>).

## Anomalias congênitas e variações anatômicas do apêndice vermiforme e mesoapêndice

### R E S U M O

#### Palavras-chave:

Apêndice vermiforme

Variação anatômica

Anomalias congênitas

**Objetivo:** O objetivo desta revisão foi apresentar e discutir as variações anatômicas e anomalias congênitas do apêndice vermiforme e mesoapêndice relatados nos últimos anos e suas associações com apendicite aguda e outras patologias associadas.

**Métodos:** A busca foi realizada nas seguintes bases de dados: Pubmed, Science Direct e Scielo.

**Resultados:** Trinta e sete estudos foram incluídos nesta revisão. Entre as anormalidades do apêndice vermiforme identificadas estão agenesia e duplicidade e, variações anatômicas relacionadas ao comprimento e posicionamento. A duplicidade apendicular foi a anormalidade mais incidente, principalmente do Tipo B2, associada à apendicite aguda, seguida de agenesia do Tipo III. O primeiro caso de agenesia associada à apendicite aguda e à duplicidade de apêndice do tipo vólculo foi identificado. A posição mais frequente foi a retrocecal em adultos e a pélvica em crianças. No mesoapêndice, foram identificadas variações anatômicas em seu posicionamento, formato, ausência e comprimento.

**Conclusão:** Esta revisão procurou apresentar e discutir as variações anatômicas e anomalias congênitas do apêndice vermiforme e mesoapêndice relatados nos últimos anos e suas associações com apendicite aguda e outras patologias associadas contribuindo para o auxílio no diagnóstico clínico e intervenções cirúrgicas em pacientes com suspeita apendicite aguda.

© 2019 Sociedade Brasileira de Coloproctologia. Publicado por Elsevier Editora Ltda. Este é um artigo Open Access sob uma licença CC BY-NC-ND (<http://creativecommons.org/licenses/by-nc-nd/4.0/>).

## Introduction

The study of abnormalities and anatomical variations is essential in to the foundation of health sciences; it represents fundamental knowledge for medical and surgical disciplines. The macroscopic and microscopic structures of the human body and their characteristics follow a pattern of normality established by statistically significant criteria. Thus, a change in this pattern may give rise to an anatomical variation or abnormality that may be congenital or acquired.

The vermiform appendix is characterized by anatomical variations and congenital abnormalities, as well as the mesoappendix; said variations may be associated with acute appendicitis. Acute appendicitis is considered the most frequent cause of abdominal pain and emergency surgery, with a mortality risk of 6%–7% from its onset.<sup>1</sup> Appendectomy is the most frequent emergency surgery, presenting rates of 12% for men and 25% for women.<sup>2</sup>

However, as atypical deviations in these structures are rare, they can lead to diagnosis confusion and increase the risk of worsening of the patient's clinical picture.<sup>3</sup> The incidence of agenesia of the vermiform appendix is 1 per 100,000 laparotomies performed due to acute appendicitis suspicion.<sup>4</sup> Appendix duplication is associated not only with cases of acute appendicitis, but also with gastrointestinal, genitourinary, and bone disorders.<sup>5</sup> The location of the vermiform appendix is also associated with cases of acute appendicitis, varying according to the age group.<sup>6</sup> Few studies on the anatomical variations and congenital abnormalities of the vermiform appendix and mesoappendix have been retrieved in the literature. Thus, a discussion on the anatomical variations

and congenital abnormalities of these structures could help in the clinical diagnosis of acute appendicitis.

This review aimed to present and discuss the congenital abnormalities and anatomical variations of the vermiform appendix and mesoappendix described in the scientific literature over the last six years.

## Methods

This was a review of scientific articles that addressed the congenital abnormalities and anatomical variations of the vermiform appendix and mesoappendix. Anatomical variation can be conceptualized as a morphological deviation of an organ that does not hinder its function. Small deviations in anatomical structures should be treated as modifications, as they are within normal limits. However, cases in which there is a deviation in the normal pattern, followed by malfunction, may be considered as congenital or acquired abnormality. A search was performed in three electronic databases: SciELO (Scientific Electronic Library Online), Science Direct (Elsevier), and PubMed. The initial selection of the key terms was conducted in the Health Sciences Descriptors portal (DeCS/BIREME) and in Medical Subject Headings portal (MeSH/PubMed). The following descriptors were used in the Portuguese, French, English, and Spanish languages, respectively: apêndice vermiforme, appendice vermiforme, vermiform appendix, apêndice; variação anatômica, variation anatomique, anatomical variation, variación anatómica; anormalidades congênitas, anomalies congénitales, congenital abnormalities, anomalías congénitas. Furthermore, the following keywords were used in Portuguese, French, and

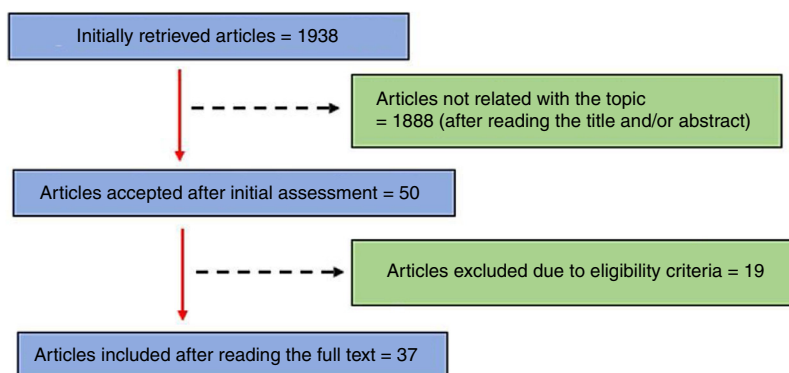


Fig. 1 – Summary of literature research.

English, respectively: agenesia, agénésie, agenesis; duplicidade, duplicité, duplicity; comprimento, longueur, length; mesoapêndice, mesoappendix. The “AND” and “OR” operators were used to combine descriptors and keywords to track publications. The descriptor combinations were obtained in the following order, in Portuguese, French, English, and Spanish, respectively:

1. Apêndice OR apêndice vermiforme OR apêndice cecal AND anormalidades congênicas OR anomalia congênita OR malformação OR malformação congênita AND variação anatômica;
2. Appendice OR appendice vermiforme OR annexe calcule AND anomalies congénitales OR anomalie congénitale OR mauvaise formation AND variation anatomique;
3. Appendix AND congenital abnormalities OR comorbidity;
4. Apêndice AND variación anatômica OR anomalias congênicas.

The combinations of keywords were obtained in the following order in the languages of Portuguese, French, English, and Spanish, respectively.

1. Apêndice vermiforme OR apêndice AND anomalia congênita AND variação anatômica AND mesoapêndice AND agenesia AND duplicidade AND tamanho;
2. Appendice vermiforme OR appendice AND anomalie congénitale AND variation anatomique AND mesoappendix AND agénésie AND duplicité AND longueur;
3. Vermiform appendix OR appendix AND congenital abnormality AND anatomical variation AND mesoappendix AND agenesia AND duplicity AND length;
4. Appendice vermiforme OR appendice AND anomalia congênita AND variación anatômica AND mesoapêndice AND agenesia AND duplicidad AND tamaño.

The following inclusion criteria were considered: (1) articles that involved congenital abnormalities or anatomical variations of the vermiform appendix and mesoappendix; (2) articles published in the last six years; (3) original articles; and (4) studies in human beings that addressed the ethical aspects in the text. Articles repeated in the databases were excluded. The database search was conducted until June 15, 2018.

## Results and discussion

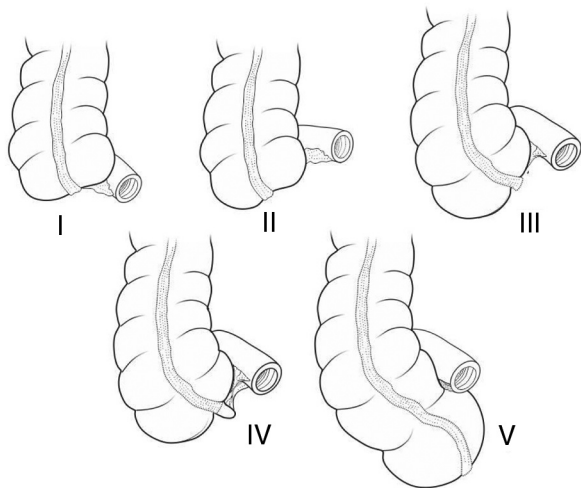
The methodology used in the electronic search is presented in Fig. 1. In summary, 1935 articles (1172 in PubMed, 646 in Science Direct, and 118 in SciELO) were retrieved. Subsequently, the articles were assessed regarding the inclusion criteria, and 37 studies were included in this review (seven articles on agenesia of the vermiform appendix, 11 on duplicity of the appendix, seven on the mesoappendix and the length of the appendix, and 12 on positioning of the appendix).

The present review found studies that reported some anatomical variations and congenital anomalies of the vermiform appendix and mesoappendix, associated not only to cases of acute appendicitis, but also to other pathologies. In relation to the vermiform appendix and its congenital anomalies, some studies indicated differences according to the number: agenesia and appendicular duplicity. The anatomical variations identified involved the length and position of the appendix. As for the mesoappendix, its anatomical variations involved positioning, absence, shape, and length.

### Agenesia of the vermiform appendix

One of the congenital anomalies of the vermiform appendix is agenesia, which refers to complete or partial absence. This is a rare finding: the first case was described by Morgagni in 1719. It has an incidence of 1 per 100,000 laparotomies performed due to suspicion of acute appendicitis<sup>4</sup> or confusion in the diagnosis due to appendix positioning, resulting in treatment delay. When investigating the vermiform appendix, Collins<sup>7</sup> observed eight malformations (four cases of agenesia and four of duplications) in 50,000 laparotomies, giving rise to a specific classification for these cases. Thus, malformations of the vermiform appendix can be classified as follows: Type I – absence of appendix and cecum; Type II – rudimentary cecum and absence of appendix; Type III – normal cecum and absence of appendix; Type IV – normal cecum and rudimentary appendix; Type V – giant cecum and absence of appendix (Fig. 2).

The present review identified six case studies (Table 1). A prevalence of type III cases was observed; in turn, only one study reported type IV. These results are not in agreement with the literature, in which type II has a higher incidence.<sup>8</sup>



**Fig. 2 – Classification of the agenesis of the vermiform appendix.**

**Table 1 – Studies on agenesis of the vermiform appendix.**

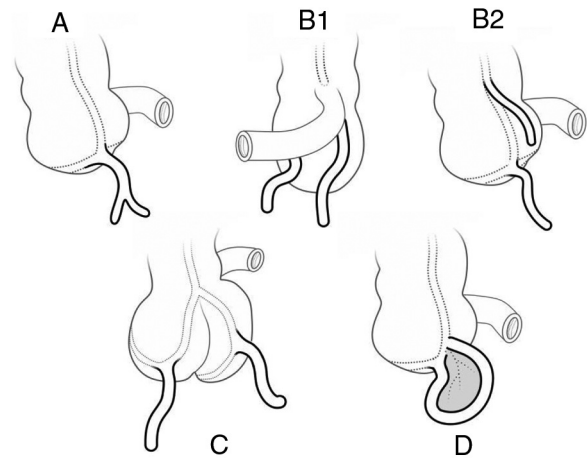
Authors	Sex	Age (years)	Type
Maitra et al. <sup>9</sup>	Female	45	III
Vicent et al. <sup>10</sup>	Male	14	III
Shah <sup>11</sup>	Male	25	III
Andrade <sup>8</sup>	Female	4	III
Tripathy <sup>12</sup>	Male	5	III
Loli et al. <sup>13</sup>	Male	24	IV

Type I, absence of appendix and cecum; Type II, rudimentary cecum and absence of appendix; Type III, normal cecum and absence of appendix; Type IV, normal cecum and rudimentary appendix.

The most prevalent population was adult, followed by infants, young, and finally the elderly. Regarding sex, most cases were observed in men.

Although the cause of agenesis of the vermiform appendix is unknown, some assumptions are described in the literature. Based on pediatric cases of intestinal atresia, it may be considered a result of intrauterine strokes.<sup>14</sup> Furthermore, reports of the presence of cord-like fibrous structures within the peritoneal cavity were found in some cases in which there was no vermiform appendix associated with ileocecal atresia.<sup>15</sup> The absence of the vermiform appendix is also associated with other malformations, such as ileocecal valve agenesis<sup>4</sup> and jejunoileal atresia.<sup>16</sup> Andrade<sup>8</sup> identified an acute appendagitis associated with agenesis of the appendix, considered the first reported case. However, autoamputations appear to be the focus of chronic inflammation in the appendix<sup>13</sup> or within the peritoneal cavity.<sup>10</sup>

Regarding the surgical procedure, some authors suggest that, in cases where the vermiform appendix is not present, the entire cecum should be mobilized immediately and the taenia coli must be traced to the junction where they are found. In addition, the ileus and retrocecal areas should be explored prior to the diagnosis of agenesis.<sup>9</sup>



**Fig. 3 – Modified Cave-Wallbridge classification. Type A, partial duplication of the appendix; Type B1 (bird type), two appendices are placed symmetrically on both sides of the ileocecal valve; Type B2 (taenia coli type), one appendix is in the usual place and the other is far along the taenia coli; Type C, duplication of cecum and appendix; Type D (horseshoe type), one appendix has two openings in the cecum; Bulut et al. (2016).<sup>6</sup>**

#### Duplication of vermiform appendix

Albeit rare, partial or complete duplication of the vermiform appendix is among the most frequently found congenital anomalies, with 100 cases already reported worldwide.<sup>17</sup> The term “alimentary tract duplication” comprises a set of congenital anomalies characterized by the presence of a well developed smooth muscle lining, epithelial lining, and association between duplicate structure and part of the gastrointestinal tract. A case of appendix duplication was reported in 1892 by Piccoli.<sup>18</sup> Cave<sup>19</sup> was the first to classify appendix duplication: Type A – appendices originate from only one cecum. In this category, the lumen of the appendix is juxtaposed to the fibrous submucosal communication that occurs in various lengths of the cecal base; Type B – each appendix is located on distinct sides of the ileocecal valve; Type C – one appendix originates from the normal anatomical point and the second originates from the distal point along the taenia coli. Wallbridge<sup>20</sup> updated the Cave classification, now called the Cave-Wallbridge classification, which includes the Type B subdivision. Bierman et al.<sup>21</sup> updated the classification cited, including Type D and subdivisions B3 and B4<sup>22</sup> (Fig. 3):

- Two appendices coming from only one cecum, with one appendix smaller than the other, called a partial appendix. It presents several degrees of incomplete duplication;
- Two complete appendices are described, coming from only one cecum. This category has been subdivided according to the location of the second appendix: B1 – the second appendix appears symmetrically on the other side of the ileocecal valve; B2 – the appendix appears anywhere along the line of the taenia coli, away from the first appendix; B3

- it originates in the hepatic flexure<sup>23</sup>; B4 – it originates in the splenic flexure.<sup>24</sup>
- c) Used to categorize two appendices along two ceca, each emerging from its respective cecum, although this category is rare;
- d) Refers to the horseshoe appendix, a single appendix with two openings for the cecum.<sup>25</sup>

Analyzing the histological features of the duplicate appendix, Cave<sup>19</sup> found that its lumen remained blind, but the respective layers of smooth muscle, lymphoid tissue, and mucous membrane were the same as those of a normal appendix. The author suggests that the presence of the transient appendix would be a vestige of an old duplication of the cecum in mammals.

In the present review, 11 case studies and a review study were retrieved. Table 2 presents the results of the studies on appendix duplication. Type B2 presented a higher incidence, corroborating the literature review study, in which there was a prevalence of Type B2, followed by Type A.<sup>26</sup> According to Nazir et al.,<sup>22</sup> Type B2 is the most frequent duplication reported, originating from the development of transient cecal protuberance during the sixth embryonic week.<sup>27</sup> Vermiform appendix duplicity was more prevalent in women (54.5%).

Regarding the age group, 54.5% of the patients with double appendix were adults, followed by young people (18%) and the elderly (9%).

Severe complications of the rupture of the second appendix can lead to peritonitis.<sup>27</sup> In addition, appendix duplication requires further investigation because of its association not only with acute appendicitis, but also with gastrointestinal,<sup>34</sup> genitourinary,<sup>35</sup> or bone disorders,<sup>36</sup> especially in cases of Types B1 and C. In type B2, duplication is not known to be associated with other congenital anomalies.<sup>31</sup> Clinical manifestations occur according to the location, size, and presence of ectopic mucosa in cases of appendix duplication. In the studies retrieved for this review, all patients reported pain in the lower right quadrant, fever, nausea, and loss of appetite. Thus, vermiform appendix duplication should be considered in all cases of abdominal pain in the lower right quadrant, even if the patient has already undergone appendectomy. In cases where acute appendicitis is suspected, the histopathological examination should show a complete and separate external

circular muscle layer with lymphoid tissue to differentiate appendix duplication from a solitary cecal diverticulum.<sup>27</sup>

Regarding the surgical procedure, in all studies retrieved for this review, both appendices were removed, except for the study by Mahmood et al.,<sup>5</sup> in which no inflammatory picture was identified in the region. Appendectomy of the two appendices is recommended even when only one is compromised, in order to avoid any ambiguity in the evaluation of future abdominal pain.<sup>22</sup>

Because it is a rarity, vermiform appendix duplication requires more attention from surgeons, despite the fact that exploration of the second appendix is not a routine procedure. Type B duplication require extra care, because the base of the appendix can be anywhere along the colon. Inadequate surgical evaluation of the cecum can trigger future perforation, causing fatal consequences.

In addition, cases of loss in laparoscopy or non-verification of the possibility of duplicity of the appendix in the assessment of the cecum may have medicolegal consequences resulting from malpractice. With regard to the complications of the appendices, the studies included in the present review indicated involvement of only one of the appendices. In two cases, the appendix was gangrenous<sup>23,28</sup> (Table 2). The study by Alves et al.<sup>17</sup> reported inflammation in both appendices, while Bulut et al.<sup>6</sup> observed inflammation of the cecal region. This review also retrieved the first records of cases of Type A appendix duplication with removal of 35.56 cm of necrotic intestine<sup>32</sup> and another case of appendix duplication associated with diverticulitis in the Meckel's diverticulum, suggesting complete exploration of the cecum.<sup>33</sup>

#### **Anatomical variations of the vermiform appendix and the mesoappendix**

Regarding length, the present review included studies that discussed the length of the vermiform appendix and the mesoappendix, totaling seven studies, which are listed in Table 3. In this review, the highest recorded mean was 10.21 cm for men and 8.03 cm for women. Age is a factor that is significantly correlated with the length of this structure; its gradual decrease is identified as a function of the advancing age, thus justifying the greater length in children and adolescents.<sup>37</sup> Thus, age group is a variable that may be related to the higher

**Table 2 – Studies on the duplication of vermiform appendix.**

Authors	Sex	Age (years)	Type	State of the appendices
Mahmood et al. <sup>5</sup>	Female	15	A	No inflammation of the appendices.
Rashid et al. <sup>28</sup>	Male	10	A	One of the appendices gangrened.
Muhstaque et al. <sup>23</sup>	Male	16	B2	One of the appendices gangrened.
Oruç et al. <sup>29</sup>	Female	64	D	Presence of adhesions that hinder the mobilization of the appendix.
Bulut et al. <sup>30</sup>	Male	52	D	Local inflammation.
Dubbashi et al. <sup>18</sup>	Female	24	B2	Only one inflamed appendix.
Christodoulidis et al. <sup>31</sup>	Female	23	–	Only one inflamed appendix.
González et al. <sup>32</sup>	Female	7	A	Volvulus of the appendix Necrosis of the intestine.
Alves et al. <sup>17</sup>	Male	36	B	Both appendices were swollen.
Nazir et al. <sup>22</sup>	Female	33	B2	Only one inflamed appendix.
Panda et al. <sup>33</sup>	Male	24	B1	Only one inflamed appendix, associated with diverticulitis in the Meckel's diverticulum.

Source: Authorized by the authors.

**Table 3 – Data on appendix and mesoappendix.**

Authors	n	Age (years)	Length (cm)/sex	State of the appendix and mesoappendix
Bakar et al. <sup>39</sup>	56	18–67	10.2 ± 2.5 (M)	In 62.5% of cases, the mesoappendix did not reach the end of the appendix.
Ghorbani et al. <sup>37</sup>	200	39.3	9.1 (H)/8.0 (F)	In 79.5% of cases, there was complete mesoappendix. Incomplete mesoappendix was more observed in the 10-year-old group.
Willekens et al. <sup>1</sup>	186	61.6	8.1 ± 2.8	–
Mwachaka et al. <sup>40</sup>	48	–	7.6 ± 2.3	–
Méndez et al. <sup>41</sup>	236	28.1	9.3 ± 3.3	68.2% triangular shape and 31.7% oval shape. The most frequent insertion point was the middle third, 75.8%. 1.2% did not present mesoappendix.
Souza et al. <sup>6</sup>	377	33.6	11.4	–
Mohammad et al. <sup>42</sup>	693	40.6	8.0 (F)/8.6 (M)	–

Source: Authorized by the authors.

M, male; F, female.

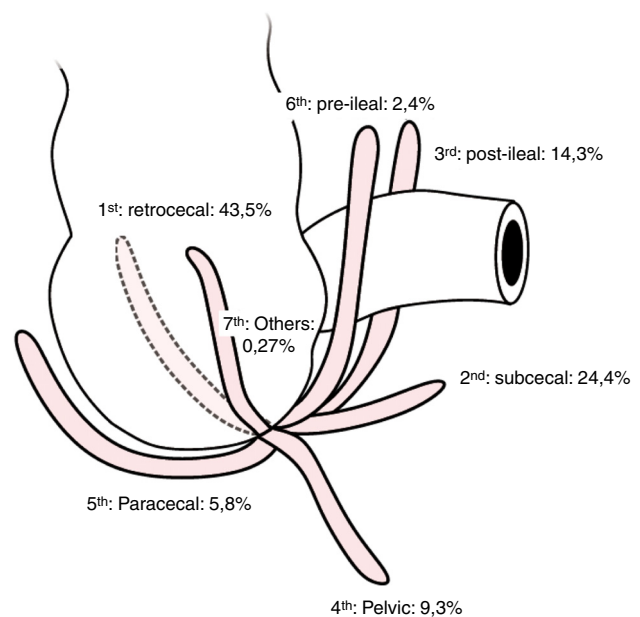
incidence of cases of acute appendicitis in schoolchildren and young adults, being rare in individuals older than 50 years.<sup>38</sup>

Sex may also influence the length of the appendix, being longer in men than in women.<sup>2,37,43</sup> However, these data do not corroborate the findings of Verdugo and Olave,<sup>44</sup> who observed a higher appendix length in women rather than men, with a mean of  $7.6 \pm 1.81$  cm for women and  $7.54 \pm 1.52$  cm for men, although this difference was not statistically significant.

The vermiform appendix presents a triangular peritoneal fold, derived from the posterior and terminal layer of the ileal mesentery, called the mesoappendix. It can be said that the mesoappendix extends almost to the end of the appendix along its entire length, presenting a free border, ensuring a blood supply to that organ from the appendicular branch of the ileocolic artery. Thus, if the mesoappendix does not reach the end of the appendix, this will probably lead to a reduction in the vascularization of this organ, making it more susceptible to gangrene and early perforation during an inflammatory condition.<sup>39</sup> The anatomical variations of the mesoappendix found in the present review are related to positioning, shape, and size. The absence of this structure has been pointed out by some authors; however, it was not considered an abnormality, since there was no impairment of appendix retention.

Some studies included in this review have identified that, in part of the samples, the mesoappendix failed to reach the end of the appendix, which may justify the incidence of cases of inflammation in adults and children<sup>39,43</sup> (Table 3). Gotalipour et al.<sup>45</sup> report that such a failure probably reduces the vascularization of the appendix extremity, being more prone to gangrene and perforation early during inflammation, becoming another risk factor in cases of acute appendicitis.

Regarding the shape of the mesoappendix, Verdugo and Olave<sup>44</sup> identified an oval shape of this structure in 6.2% of the children in their sample, which differs from the majority of triangular form. Méndez et al.<sup>41</sup> found an oval shape in 31.78%



**Fig. 4 – Positions of the vermiform appendix.**

of the adults in their sample; this finding was more common in men than in women (Table 3).

It can be said that the vermiform appendix is the only organ of the human body that does not have a fixed anatomy. It is subject to changes in its positioning as the proximal part of the large intestine lengthens, while the appendix is displaced into the right iliac fossa. During this process, the appendix may pass behind the cecum (retrocecal), reach the pelvic (pelvic or descending) borders, reach an anterior-superior (pre-ileal) or postero-superior (post-ileal) position in the ileum, be lateral to the cecum and ascending colon (paracecal), or be located under the cecum (subcecal)<sup>46</sup> (Fig. 4).

**Table 4 – Frequency of positions of the vermiform appendix.**

Authors	n	Age (years)	Sex	Retro	Pelv	Sub	Pre-ileal	Post-ileal	Parace
Iqbal et al. <sup>48</sup>	500	1–60	M/F	57%	28.6%	–	4%	9.4%	5%
Setty e Katikireddi <sup>47</sup>	90	Adults/Fetuses	M/F	50%	15%	10%	–	–	–
Bakar et al. <sup>39</sup>	56	18–67	M	53.5%	30.3%	3.5%	–	12.5%	–
Tofighi et al. <sup>27</sup>	400	–	M/F	7%	55.8%	19%	1.5%	12.5%	–
Ghorbani et al. <sup>37</sup>	200	–	M/F	7%	55.8%	19%	1.5%	12.5%	–
Mwachaka et al. <sup>40</sup>	48	–	M/F	27.1%	25%	4.2%	18.8%	18.8%	2.1%
Willekens et al. <sup>1</sup>	94	27–88	M/F	7.5%	66%	–	–	12%	8.5%
Salwe et al. <sup>38</sup>	60	–	M/F	56.6%	25%	–	15%	3.3%	–
Souza et al. <sup>6</sup>	377	18–89	M/F	43.5%	9.3%	24.4%	2.4%	14.3%	5.8%
Rao et al. <sup>43</sup>	50	Adults	M/F	66%	26%	4%	2%	2%	–
Patel e Naik <sup>49</sup>	50	40–50	M/F	64%	30%	2%	–	4%	–
Mohammad et al. <sup>42</sup>	693	0–99	M/F	71.7%	14.7%	3.5%	1.2%	1.2%	–

Source: Authorized by the authors.

M, male; F, female; Retro, retrocecal; Pelv, pelvic; Sub, subcecal; Parace, paracecal.

This review found 12 studies on the vermiform appendix position; the data are presented in Table 4. The most frequent position of the vermiform appendix was the retrocecal, followed by the pelvic position. Although all studies were cadaveric, with the exception of the work of Willekens et al.,<sup>1</sup> the different definitions and methodologies of data collection justify the contradiction in the results. The interpretation of data relating to comparisons between reports is thus hampered by the lack of uniformity of methodological criteria. In this review, in studies involving adults, most authors indicated the retrocecal position as the most common, followed by pelvic position. No samples composed only of the elderly were found. The study by Mohammad et al.<sup>42</sup> divided the sample by age group, identifying the prevalence of retrocecal position in 10-year-old children, young adults, and the elderly. In children aged from 0 to 9 years, the retroileal position was the most prevalent. Setty and Katikireddi<sup>47</sup> analyzed 50 dead fetuses, finding the retrocecal position more frequently (13.5%). However, in the study by Iqbal et al.,<sup>48</sup> the sample analyzed consisted of children aged 1–10 years; those authors found the pelvic position to be the most prevalent, corroborating the findings by Verdugo and Olave,<sup>44</sup> whose mean age was 9.7 years (47%).

Most of the studies included the present review were performed in both sexes, and the retrocecal position was the most prevalent in both. However, according to Ghorbani et al.,<sup>37</sup> the pelvic position was considered to be more frequent in women than in men. The study by Verdugo and Olave<sup>44</sup> of children with acute appendicitis indicated the prevalence of pelvic position only for girls from one region. Thus, there is a lack of studies that associate the position of the appendix with sex.

It is relevant to discuss the position of the appendix because of the significant relationship between its location and cases of acute appendicitis. Furthermore, depending on the position, the signs and symptoms can be diverse, affecting systems in the human body other than the digestive. For example, a pelvic appendicitis can trigger urinary symptoms, since retrocecal appendicitis can lead to inflammation of the main psoas muscle, causing lumbar pain and alterations in hip extension; perineal appendicitis may cause a diarrheal condition indistinguishable from that caused by

gastroenteritis.<sup>46</sup> In the present review, the position that most caused inflammation was the retrocecal position,<sup>37,48</sup> followed by the pelvic position.<sup>12,47</sup> According to some authors, the retrocecal position in adults is the result of previous cases of acute appendicitis, in which the appendix can be fixated by fibroses. In this position, the blood vessels can be compressed and flexed by the cecum, causing appendix inflammation. However, other positions, such as pelvic, post-ileal, and retroperitoneal, are also associated with advanced appendicitis, with a high incidence of granulation and perforation.<sup>6</sup> Therefore, knowledge of the relationship between appendiceal positions and their complications may aid in diagnosis, allowing early treatment.

Clinical complications caused by abnormalities or anatomical variations of the vermiform appendix, such as acute appendicitis, can be minimized through non-invasive surgical interventions, such as laparoscopic appendectomy. Ahmed et al.<sup>50</sup> assessed the frequency of appendix position change in adult patients through laparoscopy. This procedure has shown great promise, resulting in reduction of diagnostic errors, better orientation in the elaboration of treatments, and reduction of patient exposure to invasive intervention.

## Conclusion

This article aimed to present and discuss the abnormalities and anatomical variations of the vermiform appendix and mesoappendix described in scientific studies published over the last six years.

The congenital abnormalities of the vermiform appendix found include agenesis and duplication. The most common is duplication, which has a specific classification; Type B2 was more frequent, being associated with acute appendicitis. Types B1 and C are characterized by disorders of the gastrointestinal and genitourinary tract, as well as in the skeletal system. Thus, it is recommended to consider the chance of appendix duplication in all cases of abdominal pain in the lower right quadrant, even if the patient has undergone appendectomy.

Agenesis is the second most common congenital anomaly found in patients with suspected acute appendicitis; it also

has a specific classification. Type III was the most frequently observed in this review; this finding is in disagreement with the literature, which indicates Type II as more frequent. Other abnormalities were associated with agenesis, such as intestinal atresia and appendagitis.

Regarding length and diameter, both presented variation and tended to decrease with the advancement of age, justifying the higher incidence of acute appendicitis in adults and young adults. In adults of both sexes, the retrocecal position was the most commonly observed, while in children the pelvic position was the most identified. A retrocecal position was more associated with inflammation of the appendix and increase in the psoas muscle, generating pain in the lumbar region of the spine. Regarding the pelvic position, it may compromise the genitourinary tract. The anatomical variations of the mesoappendix are related to its absence, but no involvement in the blood supply of the appendix was reported. Moreover, some studies have demonstrated that, when the mesoappendix fails to reach the end of the vermiform appendix, this can trigger acute appendicitis in adults and children. The variation of the shape found was oval, which differs from the triangular shape considered to be standard.

Therefore, discussion of congenital abnormalities and anatomical variations of the appendix and mesoappendix is necessary in order to aid in the clinical diagnosis and surgical intervention in patients with suspected acute appendicitis or other associated pathologies, as well as to assist in the training of healthcare professionals.

## Conflicts of interest

The authors declare no conflicts of interest.

## REFERENCES

- Willekens I, Peeters E, Maeseneer MD, Mey J. The normal appendix on CT: does size matter? *PLoS ONE*. 2014;9, e:96476.
- Rocha JJR, Aprilli F, Féres O. Apêndice crônica e apêndice recorrente. *Artigo de revisão e apresentação de casuística. Medicina*. 2001;34:292–6.
- Travis J, Weppner J, Paugh JC. Duplex vermiform appendix: case report of a ruptured second appendix. *J Pediatr Surg*. 2008;43:1726–8.
- Martínez DG, Sánchez AW, Rivera FV, Romano RC, Torreblanca CB. Agenesia apendicular. *Acta Med Grup Áng*. 2010;8:167–71.
- Mahmood A, Mahmood NF, Willians JL. Acute abdominal pain presenting as a rare appendiceal duplication: a case report. *J Med Case Rep*. 2012;6:79.
- Souza SC, Costa SRMR, Souza IGS. Vermiform appendix: positions and length – a study of 377 cases and literature review. *J Coloproctol*. 2015;35:212–6.
- Collins DC. A study of 50,000 specimens of the human vermiform appendix. *Am J Surg*. 1955;101:437–45.
- Andrade L. A very rare association: acute apendagitis and appendicular agenesis, case report. *MOJ Clin Med Case Rep*. 2016;4:00095.
- Maitra TK, Roy S, Mondal SK, Mahjabin S. Absent appendix. *Bangladesh Crit Care J*. 2013;1:109–10.
- Vicent MV, Doyle A, Bernstein S, Jackman S. Absence of the appendix discovered during childhood. *Springer Plus*. 2014;3:522–5.
- Shah TA. A 25-year-old male with appendicular agenesis: a case report and literature review. *J Taibah Univ Sci*. 2017;12:75–7.
- Tripathy BB. Congenital absence of appendix: a Surgeon's dilemma during surgery for acute appendicitis. *J Indian Assoc Pediatr Surg*. 2016;21:199–220.
- Loli YT, Contreras CC, Cabanillas J. Apêndice crônica en un apêndice atrófico: reporte de um caso. *Horiz Med*. 2016;16:71–5.
- Greenberg SLL, Evers AA, Mackay S. Congenital absence of the vermiform appendix. *ANZ J Surg*. 2003;73:166–7.
- Iuchtman M. Autoamputation of appendix and the absent appendix. *Arch Surg*. 1993;128:600.
- Cserni T, Magyar A, Nemeth T, Paran TS, Csízy I, Józsa T. Atresia of the ileocecal junction with agenesis of the ileocecal valve and vermiform appendix: report of a case. *Surg Today*. 2006;36:1126–8.
- Alves JR, Maranhão IGO, Oliveira PVV. Appendicitis in double cecal appendix: case report. *World J Clin Cases*. 2014;2:391–4.
- Dubhashi SP, Dubhashi UP, Kumar H, Patil C. Double appendix. *Indian J Surg*. 2015;77:1389–90.
- Cave AJE. Appendix vermiformis duplex. *J Anat*. 1936;70:283–92.
- Wallbridge PH. Double appendix. *Br J Surg*. 1962;50:346–7.
- Biemann R, Borsk'y D, Gogora M. Double appendicitis – a rare pathologic entity. *Chirurg*. 1993;64:1059–61.
- Nazir S, Bulanov A, Ilyas M, Jabbour I, Griffith L. Duplicate appendix with acute ruptured appendicitis: a case report. *Int Surg*. 2015;100:662–5.
- Mushtaque M, Mehraj A, Khanday SA, Dar RA. Double appendicitis. *Int J Clin Med*. 2015;3:60–1.
- Kjossev KT, Losanoff JE. Duplicated vermiform appendix. *Br J Surg*. 1996;83:1259.
- Mesko TW, Lugo R, Breitholtz T. Horseshoe abnormality of the appendix: a previously undescribed entity. *Surgery*. 1989;106:563–6.
- Nageswaran H, Hikhan U, Hill F, Maw A. Appendiceal duplication: a comprehensive review of published cases and clinical recommendations. *World J Surg*. 2017;42:574–81.
- Tofighi H, Taghadosi-nejad F, Abbaspour A, Benhoush B, Salimi A, Dabiran S, et al. The anatomical position of appendix in iranian cadavers. *Int J Med Toxicol Forensic Med*. 2013;3:126–30.
- Rashid A, Younus U, Kakroo SM, Wani AH. Appendicular duplication with gangrenous appendicitis in a 10-year-old child: a case report. *J Park Med Stud*. 2012;2:98–100.
- Oruç C, Isik O, Üreyen O, Kahyaoglu OS, Kö Seoglu A. An extremely rare appendiceal abnormality: horseshoe appendicitis. *Ullus Travma Acil Cerrahi Derg*. 2013;19:385–6.
- Bulut SP, Cabioglu N, Akinci M. Perforated double appendicitis: horseshoes type. *Ullus Cerrahi Derg*. 2016;32:134–6.
- Christodoulidis G, Symeonidis D, Spyridakis M, Koukolis G, Manolakis A, Triantafylidis G, et al. Acute appendicitis in a duplicated appendix. *Int J Surg Case Rep*. 2012;3:559–62.
- González GH, Vega AFM, Delgado CTC, Talamantes LAC, Sánchez CNA. First case of a vermiform appendix duplication type A volvulus: a very rare cause of acute abdomen. *J Ped Surg Case Rep*. 2015;3:374–6.
- Panda SK, Tirkey CPR, Rajesh V, Mishra J, Dora RK. Unusual association of Meckel's diverticulum with double appendix – a rare finding. *Int J Surg Case Rep*. 2014;5:879–81.
- Gilchrist FB, Scriven R, Nguyen M, Nguyen V, Klotz D, Ramenofsky M. Duplication of the vermiform appendix in gastroschisis. *J Am Coll Surg*. 1999;189:426.
- Jianhong L, Xuewu J, Xianliang H. An exceptional combined malformation: duplication of the urinary and intestinal tracts and the vulva (04-80CR). *J Pediatr Surg*. 2005;40:E5–9.



36. Dutta T, George V, Meenakshi PK, Das G. Rare combination of duplication of genito-urinary tract, hindgut, vertebral column and other associated anomalies. *Br J Urol.* 1974;46:577-82.
37. Ghorbani A, Forouzes M, Kazemifar AM. Variation in anatomical position of vermiform appendix among Iranian population: an old issue which has not its importance. *Anat Res Int.* 2014;313575.
38. Salwe N, Kulkarni PG, Sinha RS. Study of morphological variations of vermiform appendix and caecum in cadavers of western maharashtra region. *Int J Adv Physiol Allied Sci.* 2014;2:31-41.
39. Bakar S, Shamim M, Ala G, Sarwar M. Negative correlation between age of subjects and length of the appendix in Bangladeshi males. *Arch Med Sci.* 2013;9:55-67.
40. Mwachaka P, El-Busaidy H, Sinkeet S, Ogeng' O. Variations in the position and length of the vermiform appendix in a black kenyan population. *ISRN Anat.* 2014;2014:871048.
41. Méndez PRC, Arzuaga RLG, Macadán CEF, González DL. Variantes morfométricas del apéndice cecal em el vivo. *Rev Med Electrón.* 2014;36:49-59.
42. Mohammad S, Hedjazi A, Sajjadian M, Rahmani M, Mohammadi M, Moghadam MD. Morphological variations of the vermiform appendix in Iranian cadavers: a study from developing countries. *Folia Morphol.* 2017;76:695-701.
43. Rao S, Narasamma K, Shahajeer B. Vermiform appendix in adults. *J Evidence Based Med Healthcare.* 2015;2:2174-9.
44. Verdugo R, Olave E. Características anatómicas y biométricas del apéndice vermiforme em niños chilenos operados por apendicitis aguda. *Int J Morphol.* 2010;28:615-22.
45. Golalipour MJ, Aray B, Azarhoosh R, Jahanshahi M. Anatomical variations of vermiform appendix in South East Caspian Sea (Gorgan Iran). *J Anat Soc India.* 2003;52: 141-3.
46. Ojeifo JO, Ejiwunmi AB, Iklaki J. The position of the vermiform appendix in Nigerians with a review of the literature. *West Afr J Med.* 1989;8:198-204.
47. Setty S, Katikireddi R. Morphometric study of human cadaveric caecum and vermiform appendix. *Int J Health Sci Res.* 2013;3:48-55.
48. Iqbal T, Amanullah A, Nawaz R. Pattern and positions of vermiform appendix in people of bannu district. *Gomal J Med Sci.* 2012;10:100-3.
49. Patel S, Naik A. Anatomical variations in the positions of the vermiform appendix. *IOSR-JDMS.* 2016;15:106-9.
50. Ahemed I, Asgeirsson KS, Beckingham IJ, Lobo DN. The position of the vermiform appendix at laparoscopy. *Surg Radiol Anat.* 2007;29:165-8.