

# Treatment of conjunctival cysts in anophthalmic socket with intralesional injection of trichloroacetic acid (ATA) 25%

## *Tratamento de cistos conjuntivais em cavidade anoftálmica com injeção intralesional de ácido tricloroacético (ATA) a 25%*

Fabricio Lopes da Fonseca<sup>1</sup>, Renata de Iracema Pulcheri Ramos<sup>2</sup>, Suzana Matayoshi<sup>3</sup>

### ABSTRACT

*Conjunctival cysts in anophthalmic socket may have functional and aesthetic implications for the patients. Among the available treatment options, the use of trichloroacetic acid is relatively recent. Our reported cases showed a good outcome after 30 days of treatment, that was well tolerated by patients, with greater conjunctival tissue preservation.*

**Keywords:** *Conjunctival diseases/drug therapy; Orbit; Trichloroacetic acid/therapeutic use; Trichloroacetic acid/administration & dosage; Eye, artificial; Case reports*

### RESUMO

Cistos conjuntivais em cavidades anoftálmicas podem ter implicações funcionais e estéticas negativas para os pacientes. Dentre as opções terapêuticas disponíveis, o uso do ácido tricloroacético é relativamente recente. Os casos relatados apresentaram boa evolução após 30 dias do tratamento, sendo bem tolerado pelos pacientes e possibilitando maior preservação de tecido conjuntival.

**Descritores:** *Doenças da túnica conjuntiva/quimioterapia; Órbita; Ácido tricloroacético/uso terapêutico; Ácido tricloroacético/administração & dosagem; Prótese ocular; Relatos de casos*

<sup>1</sup>Ophthalmologist, Fellow at the Oculoplastic Surgery Unit, Department of Clinical Ophthalmology, University Hospital of the São Paulo University (USP), São Paulo/SP, Brazil.

<sup>2</sup>Ophthalmologist and Supervisor at the Department of Clinical Ophthalmology, University Hospital of the São Paulo University (USP), São Paulo/SP, Brazil.

<sup>3</sup>Associate Professor and Head of the Oculoplastic Surgery Unit, Department of Clinical Ophthalmology, University Hospital of the São Paulo University (USP), São Paulo/SP, Brazil.

**Institution:** University Hospital of the São Paulo University.

**Study conducted at:** Oculoplastic Surgery Unit, Department of Clinical Ophthalmology, University Hospital of the São Paulo University (USP), São Paulo/SP, Brazil.

**The authors declare no conflicts of interest**

Received for publication: 14/10/2011 - Accepted for publication: 21/12/2011

## INTRODUCTION

Conjunctival cysts are complications occurring in anophthalmic sockets which may cause local discomfort and difficulty fitting an ocular prosthesis on the anterior surface of the socket.

Therapeutic options include excision, marsupialisation and alcoholisation<sup>(1,2)</sup>. The use of trichloroacetic acid (TCA) is a relatively new alternative<sup>(3,4)</sup>.

This article reports on the use of 25% TCA in three cases of conjunctival cysts.

## METHODS

Patients were placed in the supine position. One eye drop of 0.5% proxymethacaine was instilled 5 minutes and immediately before the procedure. After antisepsis, asepsis and placement of a blepharostat, the cyst was punctured with a 31×4 mm needle connected to a 3 ml syringe containing 1 ml of 25% TCA aqueous solution. The aspirated contents were then reinjected until the cyst acquired a whitish appearance. The contents were then reaspirated until the cyst walls collapsed.

Patients were then prescribed 0.3% ofloxacin and 1% prednisolone eye drops, one drop every 6 hours for 7 days. They were reassessed 7 days and 30 days after the procedure.

### Case reports

**Case 1.** A 54-year-old male underwent evisceration of the left eye after having his eye pierced 2 years ago. He was referred to the Oculoplastic Surgery Unit of the University Hospital of the São Paulo University (HCFMUSP) with a conjunctival lesion that had been gradually increasing for 3 months and caused him to have difficulty using an ocular prosthesis.

The patient received a 1 ml intralesional injection of 25% TCA (Figure 1), but did not return for follow-up.

**Case 2.** A 56-year-old female underwent two tectonic corneal grafts in the left eye, the most recent 1 year ago. The case progressed to phthisis bulbi. She was referred to the Oculoplastic Surgery Unit of HCFMUSP with a conjunctival lesion that had been gradually increasing for 6 months. She reported discomfort on blinking.

The patient received a 1 ml intralesional injection of 25% TCA. She returned for follow-up 1 month after the procedure with no complaints (Figure 2).

**Case 3.** A 78-year-old female patient underwent evisceration of the left eye three years ago due to postoperative endophthalmitis. She was referred to the Oculoplastic Surgery Unit of HCFMUSP with a conjunctival lesion that had been gradually increasing for 9 months, causing discomfort while using an ocular prosthesis.

The patient received a 1 ml intralesional injection of 25% TCA. She returned for follow-up 1 month after the procedure with no complaints (Figure 3).

## DISCUSSION

The procedure was well tolerated by all patients, who reported mild discomfort during the injection of 25% TCA. There were no complications during the study period, with adequate conjunctival regeneration and no relapse in the 2 patients who returned for follow-up.

The treatment of conjunctival cysts in anophthalmic sockets

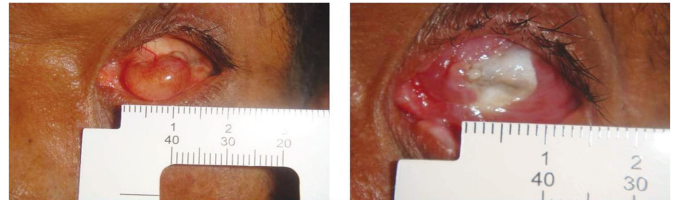


Figure 1: Appearance before (left) and after (right) the injection of 25% TCA

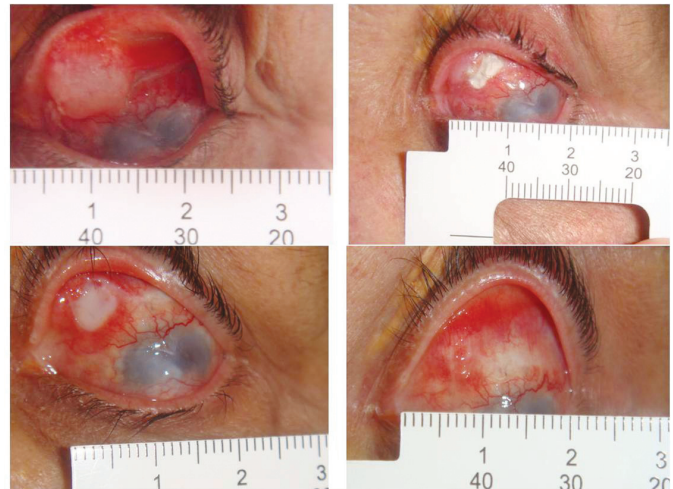


Figure 2: Clockwise, starting from the top left image: Appearance before, immediately after, 7 days after, and 30 days after the injection of 25% TCA

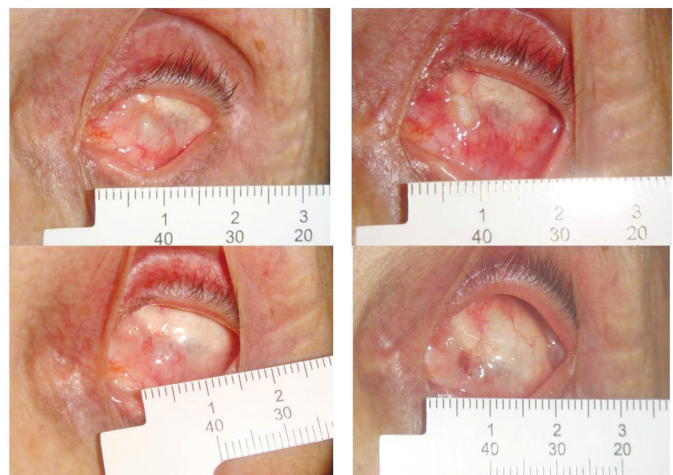


Figure 3: Clockwise, starting from the top left image: Appearance before, immediately after, 7 days after, and 30 days after the injection of 25% TCA

is required when it interferes with an ocular prosthesis, causes discomfort or has cosmetic implications for the patient.

Of the therapeutic options, the most common are excision and marsupialisation<sup>(1)</sup>. However, these require a new surgical procedure, and complete resection of the cyst may be difficult, thus increasing the risk of relapse.

Hornblass et al.<sup>(2)</sup> described a series of 4 cases treated with intralesional injection of absolute alcohol. Resolution was observed in 2 cases, but the follow-up time was not reported. The

use of TCA is described by Owji et al.<sup>(3)</sup> in 4 patients with giant anterior conjunctival cysts in anophthalmic sockets. All patients were treated with intralesional injection of 20% TCA. The mean follow-up time was 16 months (range 8-33 months). No relapses were observed during this period.

Sánchez et al.<sup>(4)</sup> used a TCA solution to treat a posterior conjunctival cyst in an anophthalmic socket; the lesion resolved and no relapse was observed during a follow-up period of 10 months.

In the cases reported here, the use of 25% TCA was simple, safe and effective for the duration of the follow-up period. Further studies are needed to assess its long-term effectiveness in a larger number of patients.

## **REFERÊNCIAS**

1. McCarthy RW, Beyer CK, Dallow RL, Burke JF, Lessell S. Conjunctival cysts of the orbit following enucleation. *Ophthalmology*. 1981;88(1):30-5.
2. Hornblass A, Bosniak S. Orbital cysts following enucleation: the use of absolute alcohol. *Ophthalmic Surg*. 1981;12(2):123-6.
3. Owji N, Aslani A. Conjunctival cysts of the orbit after enucleation: the use of trichloroacetic acid. *Ophthal Plast Reconstr Surg*. 2005;21(4):264-6.
4. Sánchez EM, Formento NA, Pérez-López M, Jiménez AA. Role of trichloroacetic acid in treating posterior conjunctival cyst in an anophthalmic socket. *Orbit*. 2009;28(2-3):101-3.

---

### **Corresponding author:**

Fabricio Lopes da Fonseca  
Rua Xavier de Almeida, 1135 apto 121 – Ipiranga  
CEP 04211001 - São Paulo (SP), Brazil.  
E-mail: fabricio89@gmail.com