

Visual psychophysics of congenital ocular toxoplasmosis case

Psicofísica visual em caso de toxoplasmose ocular congênita

Raissa Cerveira Vieira¹, Mirian Débora Rodrigues de Sousa¹, Filipe Mycael Campos Silva¹, Cândida Helena Lopes Alves², Mauro César de Oliveira³, Givago da Silva Souza⁴, Eliza Maria da Costa Brito Lacerda²

ABSTRACT

*Congenital ocular toxoplasmosis is a manifestation of infection by the parasite *Toxoplasma gondii* that occurs through the placenta. This disease can lead to important visual sequelae. This paper describes a case report that uses visual psychophysics for the alterations of congenital ocular toxoplasmosis. The evaluation was performed in a 30-year-old man, a resident of São Luís (MA), with a history of his mother have had toxoplasmosis in the gestational period. Only at 26 years-old he did the detailed medical evaluation that described a lesion the fovea of the right eye. In the classic clinical examination and in visual psychophysical evaluation, the patient presented normal vision for the left eye. The right eye had low visual acuity (decimal value: 0.028), visual field with scotomas up to 20° of visual angle and alteration of color vision. The study offers safe and relevant medical information for the diagnosis of congenital ocular toxoplasmosis using a low-cost evaluation and with good portability, allowing a functional diagnostic alternative to be applied in places difficult to access in the interior of Brazil.*

Keywords: Ocular toxoplasmosis; Vertical transmission; Visual psychophysics

RESUMO

A toxoplasmose ocular congênita é uma manifestação da infecção pelo parasita *Toxoplasma gondii* que ocorrer por meio placentário. Essa doença pode provocar importantes sequelas visuais. Este trabalho descreve um estudo de caso que utilizou avaliação psicofísica visual para descrever alterações funcionais decorrentes da toxoplasmose ocular congênita. A avaliação foi realizada em paciente de 30 anos, sexo masculino, residente em São Luís (MA), hígido com histórico da mãe ter apresentado infecção por toxoplasmose no período gestacional. Somente aos 26 anos foi feita uma avaliação médica detalhada que descreveu lesão na fóvea do olho direito. Na avaliação clínica clássica e na avaliação psicofísica visual, o paciente apresentou visão normal para o olho esquerdo. O olho direito apresentou baixa acuidade visual (valor decimal: 0,028), campo visual com escotomas localizados até 20° de ângulo visual e alteração da visão de cor. O estudo fornece informações médicas seguras e relevantes para o diagnóstico de toxoplasmose ocular congênita utilizando testes eficazes, de baixo custo e boa portabilidade, possibilitando uma alternativa de diagnóstico funcional para ser aplicada em locais de difícil acesso pelo interior do Brasil.

Descritores: Toxoplasmose ocular; Transmissão vertical; Psicofísica visual

¹ Academic Course, Universidade do CEUMA, São Luís, MA, Brazil.

² Universidade do CEUMA, São Luís, MA, Brazil.

³ Oftalmoclínica, São Luís, MA, Brazil.

⁴ Universidade Federal do Pará, Belém, PA, Brazil.

The present study was carried out in the Laboratory of Neurosciences and Behavior of Universidade CEUMA.

The authors declare no conflicts of interests.

Received for publication 16/04/2018 - Accepted for publication 03/08/2018.

INTRODUCTION

Toxoplasmosis is an infectious disease caused by the parasite *Toxoplasma gondii* whose life cycle includes the human being as an intermediate host, and has a latent phase in which the cysts remain mainly in the skeletal muscles and in the brain.⁽¹⁾ It is prevalent in cosmopolitan regions, and can cause indistinct symptoms such as fever, muscle aches, fatigue, and swollen lymph nodes in immunocompetent individuals, some of whom may be asymptomatic.⁽¹⁾ Particularly susceptible groups are the immunocompromised and pregnant women (the latter due specifically to the high risk of placental transmission with severe progeny consequences and absence of symptoms in the progenitor).⁽²⁾ After the parasite was discovered and described by Nicolle and Manceaux (1907) in Tunisia and Splendore (1908) in Brazil, serological tests were developed and allowed the visualization of anti-*T. gondii* antibodies in several organisms, indicating that the prevalence of this infection in the human population would be higher than expected.⁽³⁾

Congenital toxoplasmosis is one of the major causes of prenatal complications due to the ability of *T. gondii* to cross the placenta and settle in developing fetal tissues.⁽⁴⁾ A variety of diseases and pathological manifestations have been attributed to fetal infection by this parasite, which is capable of triggering encephalitis, mental, psychomotor, and neurological disorders (such as epilepsy), brain malformations, myocarditis, abortion, etc.^(4,5) Parasite transfer experiments (present in the autopsy of children with encephalomyelitis) to the brains of rats, rabbits and mice by intracranial inoculation and a series of cases of newborns with neurological diseases whose mothers had positive serology for *T. gondii* demonstrated the possibility of congenital transmission.⁽⁶⁻⁸⁾

T. gondii was identified as a trigger for retinocoroiditis, cataract, anterior and posterior uveitis, and optic neuropathy⁽⁹⁾ in human adults, since many patients showed inflammations and scars in the visual system tissues after contamination.^(3,10) Today, although toxoplasmosis is known to be a disease with a broad spectrum of symptoms (which makes its definition and diagnosis challenging), it is still understood that many infected individuals have ocular symptoms.⁽¹¹⁾ Retinochoroiditis is established as a pathognomonic sign of toxoplasmosis.⁽¹¹⁾ Many children born to mothers who are primoinfected during pregnancy are asymptomatic after birth, only showing this symptom after the first years of life.⁽²⁾ Retinochoroiditis is characterized by a necrotic process and granulomatous or non-granulomatous inflammation in the tissues of the retina and choroid in active lesions (in which *T. gondii* is present in the infecting form) and by scotomas of size and location related to the formation of retinochoroiditis in inactive lesions (where the parasite is no longer present or is dormant).^(9,11)

The association between alterations and morphophysiological sequelae in visual system tissues due to exposure to *T. gondii* with possible alterations in the central nervous system is important, since the retina is an integral part of both the visual and nervous systems, where transduction mechanisms of incident light information occur.⁽¹²⁾ In addition, this tissue is extremely sensitive to poisoning by chemical agents, being useful to visualize signs of possible pathological alterations of the nervous system through the manifestation of

visual alterations.^(13,14) Este conhecimento sugere que além da lesão causada na retina pela infecção, o parasita poderia causar mudanças na massa encefálica também, as quais poderiam ser detectadas antes do aparecimento de manifestações clínicas mais graves.^(13,14) Um método útil para o estudo de alterações neurovisuais é a psicofísica visual, o qual permite avaliar a percepção de parâmetros físicos da luz, tais como cor e luminância, possibilitando examinar, qualificar e quantificar a percepção visual⁽¹⁵⁾ e ajudar no diagnóstico de enfermidades que acometem o processamento da informação visual.⁽¹⁶⁾ Estes são procedimentos não invasivos que informam o funcionamento do sistema nervoso sem causar qualquer dano tecidual⁽¹⁷⁾ que se comparados a outros métodos de avaliação visual, apresentam baixo custo uma vez que os testes podem ser aplicados por muitos anos sem causar desgaste de material ou equipamento, além disso são testes portáteis que podem ser facilmente transportados.

The aim of the present study was to describe the sequelae of visual function through the use of psychophysical tests in patients with congenital ocular toxoplasmosis. Considering the epidemiological condition of this disease in Brazil and the great relation it presents to the poorest strata of the population, this study is justified by providing safe and relevant medical information for the diagnosis of congenital ocular toxoplasmosis using tests of efficient, low cost and excellent portability. The study reports a diagnostic alternative to be applied in places difficult to access in the countryside of Brazil.

CASE REPORT

The following description represents the case study of an individual affected with ocular congenital toxoplasmosis. This description was approved by the Research Ethics Committee of the Nucleus of Tropical Medicine of Universidade Federal do Pará under protocol #076/2006-CEP/NMT, and followed the guidelines recommended by the Helsinki Declaration. The patient is 30 years old and male. He was born in Recife, Pernambuco, and currently lives in São Luís, Maranhão. The mother of the patient under study had her prenatal care, and at the time of delivery was instructed to take the baby for ophthalmologic evaluation without further instructions. Since the patient developed without apparent complications for the family, the ophthalmologist was only sought when the patient had a visual complaint at the age of 6 during the literacy period. From the age of 6, he started wearing glasses for astigmatism and myopia correction. Only when he was 10 years old did he realize that the vision of the right eye did not improve with the correction lenses, and in an ophthalmological appointment he found out he had a scar in the center of said eye. The physician pointed out that the lesion was typical of an ocular toxoplasmosis, probably developed after healing of the infectious process.

The diagnostic impression was in agreement with the medical history of the patient's mother, indicating that the patient was infected placentally (and that the mother was possibly asymptomatic with *T. gondii* and transmitted it to the fetus). Further details of the lesion were known only at age 26, when the patient underwent a retinographic exam to confirm the lesion in the right eye was related to toxoplasmosis. Currently, the patient makes use of correction of 4.5 diopters of concave lenses and 2.5

diopeters of convex lenses, respectively in the right eye and left eye. Regarding the left eye, the patient has no complaints – except for the need for correction due to the curvature of the eye. The clinical condition assessed associated to the mother’s infectious history gave a diagnostic impression of congenital ocular toxoplasmosis with sequelae in the retina of the right eye.

The patient drinks casually, is a non-smoker with no history of drug abuse. He works in a research laboratory, and informs he makes frequent use of personal protection equipment to deal with any chemical agent. He has a balanced nutrition and physical health, without complaints of other relevant infections.

Considering the diagnostic impression, the subject underwent psychophysical evaluation of the visual functions to indicate the functional losses suffered from the lesion described. The following visual psychophysical tests were used: evaluation of visual acuity by the FrACT computerized test, visual field evaluation by Goldman’s Kinetic Perimeter, evaluation of color vision by Ishihara Pseudo-isochromatic Plates (test used to evaluate genetic loss of color vision - color blindness), application of the L’Anthony’s desaturated D15 tint sorting test (tests for possible acquired or genetic loss of color vision). All tests were performed monocularly with both eyes, considering the specific protocol for each evaluation.

Visual acuity values without dioptric correction were below what would be the normal parameter in right and left eyes (Table 1). The diopter correction brought normal acuity to the left eye. However, did not completely correct the right eye.

The delimitation of the visual field did not present significant alterations in any of the eyes; however, following a central evaluation protocol we observed the presence of scotomas extending by about 20° of visual angle (Figure 1).

During the tests, when presented to the stimulus of the Ishihara Pseudo-isochromatic Plates which corresponds to

plates containing a target that differs from the fundus only by the chromaticity difference within a red-green confusion axis, the patient was not able to identify the initial “control” plates as right eye, showing that he was not able to perceive the format of the stimulus presented, therefore this test was not performed in the right eye. In the evaluation of the left eye, a normal result was observed, indicating no genetic loss of color vision in the left eye. The evaluation of L’Anthony’s desaturated D15 tint sorting test showed a diffuse color vision alteration (no error tendency for a specific axis of color confusion) for the right eye. For the left eye, a typical result of normal trichromacy was found (Figure 2).

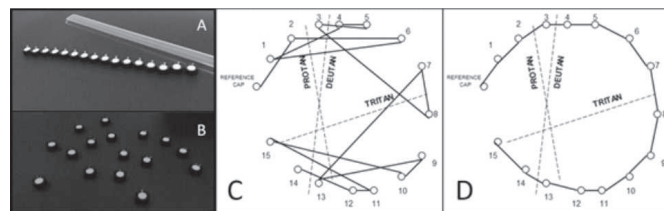


Figure 2: Result of the L’Anthony’s desaturated D15 tint sorting test A. Stimulus of the test presented in an aligned way, each piece presenting a different hue (the result is in black and white to follow the format of the magazine). B. Stimulus of the test presented in a disorganized way so that it is rearranged by the patient. C. Graph of tint sorting made by the patient with the right eye. D. Graph of tint sorting made by the patient with the left eye.

DISCUSSION

The psychophysical assessment of visual acuity, visual field, and color vision may describe functional changes in the patient’s vision. There are important functional differences between the two eyes which are characteristic of non-genetic alterations.⁽¹⁸⁾ The difference in results between the two eyes for the color vision tests indicates that the color alterations observed in the right eye are not of genetic origin, since color blindness would cause color vision loss characteristically equal to the two eyes of a person.⁽¹⁸⁾ With the manipulation of the stimulus present in Goldman’s Kinetic Perimetry we confirmed that all these lesions are concentrated in the central region of the retina, confirming the morphological alteration already obtained by the retinography. This finding explains the alterations of visual acuity and color vision, since it is in this region that there is the highest concentration of cones cells to connect to the ganglion cells that will comprise the parvocellular parallel visual pathway, the greatest responsible for the processing of fine details of the image and red-green color vision processing.⁽¹⁹⁾ As it does not cover only one foveal region of the retina, the lesion also involves the parallel koniocellular pathway, responsible for the processing of blue-yellow color vision.⁽¹⁹⁾

It is possible that the scotomas observed in the central visual field of the patient are due to inflammation around the optic nerve (Jansen’s scotoma) common in cases of ocular toxoplasmosis and which may help close the diagnosis.⁽¹⁰⁾ The literature describes that damage in color vision as observed in the patient is common in patients affected by toxoplasmic retinocoroiditis, more common than the achromatic alterations.⁽²⁰⁾

Table 1
Results of the evaluation of visual acuity by FrACT computerized test.

| | Visual acuity (in Log MAR) | | Visual acuity (in Log MAR) | |
|-----------|----------------------------|--------------------|----------------------------|--------------------|
| | With correction | Without correction | With correction | Without correction |
| Right eye | * | 0.028 | * | 1.55 |
| Left eye | 1.35 | 0.23 | -0.13 | 0.64 |

*: the result could not be computed due to the lack of response to the stimulus. LogMAR: Minimum resolution angle in logarithm.

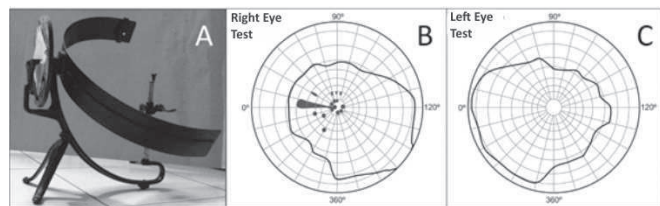


Figure 1: Result of Goldman Kinetic Perimetry. A. A manual version of the Goldman Perimeter (used in the case description). B. Visual field of the patient’s right eye studied. C. Visual field of the patient’s left eye studied.

CONCLUSION

From the present study we conclude that the psychophysical tests of evaluation of visual acuity by the FrACT computerized test, visual field evaluation by Goldman Kinetic Perimeter, evaluation of color vision by Ishihara Pseudo-isochromatic, and evaluation by the L'Anthony's desaturated D15 tint sorting test were effective to describe in detail the visual alterations due to congenital ocular toxoplasmosis, making a relation consistent with the classic clinical evaluation.

The visual damages described by the tests are: alteration of visual acuity, central scotoma in the visual field, and alteration of color vision in the right eye of the patient that is even described by the classic clinical evaluation describing the central retinal lesion. The left eye had no retinal alterations in any of the evaluations made.

REFERENCES

1. Neves DP, Kawazoe U. *Toxoplasma gondii*. In: Neves DP, editor. *Parasitologia humana*. 11ª ed. São Paulo: Atheneu; 2004.
2. Saadatnia G, Golkar M. A review on human toxoplasmosis. *Scand J Infect Dis*. 2012; 44 (11): 805–14.
3. Ferguson DJP. *Toxoplasma gondii*: 1908-2008, homage to Nicolle, Manceaux and Splendore. *Mem Inst Oswaldo Cruz*. 2009; 104 (2): 133–48.
4. Gomes AF, Barbosa HS. Congenital toxoplasmosis: in vivo impact of *Toxoplasma gondii* infection on myogenesis and neurogenesis. In: Akyar I. *Toxoplasmosis*. London: IntechOpen; 2017 [citado 2018 abr 16]. Cap. 4, p. 55-68. Disponível em: <https://www.intechopen.com/books/toxoplasmosis/congenital-toxoplasmosis-in-vivo-impact-of-toxoplasma-gondii-infection-on-myogenesis-and-neurogenesi>
5. Jones JL, Lopez A, Wilson M, Schulkin J, Gibbs R. Congenital toxoplasmosis: a review. *Obstet Gynecol Surv*. 2001; 56 (5): 296–305.
6. Dard C, Chemla C, Fricker-Hidalgo H, Brenier-Pinchart MP, Baret M, Mzabi A, et al. Late diagnosis of congenital toxoplasmosis based on serological follow-up: A case report. *Parasitol Int*. 2016; 66 (2): 186–9.
7. Wolf A, Cowen D, Paige B. Human toxoplasmosis: occurrence in infants as an Encephalomyelitis verification by transmission to animals. *Science*. 1939; 89 (2306): 226-7.
8. Wolf A, Cowen D, Paige BH. Toxoplasmic Encephalomyelitis. *J Exp Med*. 1940; 71 (2): 187–214.
9. Delair E, Latkany P, Noble AG, Rabiah P, McLeod R, Brézin A. Clinical manifestations of ocular toxoplasmosis. *Ocul Immunol Inflamm*. 2011 Apr; 19 (2): 91–102
10. Wolf A, Cowen D, Paige BH. Fetal encephalomyelitis: prenatal inception of infantile toxoplasmosis. *Science*. 1941; 93 (2423): 548-9.
11. Maenz M, Schlüter D, Liesenfeld O, Schares G, Gross U, Pleyer U. Ocular toxoplasmosis past, present and new aspects of an old disease. *Prog Retin Eye Res*. 2014; 39: 77-106.
12. Lent R. Visão das coisas: Estrutura e Função do Sistema Visual. In: *Cem bilhões de neurônios*. 2ª ed. São Paulo: Atheneu; 2001.
13. Horan JM, Kurt TL, Landrigan PJ, Melius JM, Singal M. Neurologic dysfunction from exposure to 2-t-butylazo-2-hydroxy-5-methylhexane (BHMH): a new occupational neuropathy. *Am J Public Health*. 1985; 75 (5): 513–7.
14. Lacerda EMCB, Lima MG, Rodrigues AR, Teixeira CEC, Lima LJB, Ventura DF, Silveira LCL. Psychophysical Evaluation of Achromatic and Chromatic Vision of Workers Chronically Exposed to Organic Solvents. *J Environ Public Health*. 2012; 2012 (1):1-7.
15. Silveira LC, Saito CA, Lee BB, Kremers J, da Silva Filho M, Kilavik BE, et al. Morphology and physiology of primate M- and P-cells. *Prog Brain Res*. 2004; 144: 21–46.
16. Rodrigues AR, Souza CR, Braga AM, Rodrigues PS, Silveira AT, Damin ET et al. Mercury toxicity in the Amazon: contrast sensitivity and color discrimination of subjects exposed to mercury. *Braz J Med Biol Res*. 2007; 40 (3): 415–24.
17. Schiffman HR. *Psicofísica*. In: *Sensação e Percepção*. 5ª ed. Rio de Janeiro: LTC; 2005.
18. Regan BC, Reffin JP, Mollon JD. Luminance noise and the rapid determination of discrimination ellipses in colour deficiency. *Vision Res*. 1994; 34 (10): 1279–99.
19. Masland RH. The neuronal organization of the retina. *Neuron*. 2012 Oct; 76 (2): 266–80.
20. Vingrys AJ, King-Smith PE, Benes SC. Equiluminous color deficits are greater than achromatic losses in cases of toxoplasmosis. In: Drum B, Verriest G, editors. *Colour vision deficiencies IX*. New York: Springer; 1989. (Documenta Ophthalmologica Proceedings Series, 52).

Corresponding author:

Eliza Maria da Costa Brito Lacerda
 Rua Josué Montello, nº.1- Cidade de São Luís - Maranhão,
 CEP: 65075-120
 Email: eliza_lacerda@yahoo.com.br.