

Reverse shoulder arthroplasty: Functional results in rotator cuff arthropathy*

Artroplastia reversa de ombro: Resultados funcionais na artropatia do manguito

Alexandre T. Nascimento¹ Gustavo K. Claudio¹ Pedro B. Rocha¹

¹ Shoulder and Elbow Group, Hospital Orthoservice, São José dos Campos, SP, Brazil

Address for correspondence Alexandre T. Nascimento, Av. Tívoli, 433, Vila Betânia, São José dos Campos, SP, 12245-230, Brazil (e-mail: dr.nascimento@icloud.com).

Rev Bras Ortop 2020;55(1):106–111.

Abstract

Objective To evaluate the functional results of patients submitted to reverse shoulder arthroplasty for the treatment of rotator cuff arthropathy refractory to conservative treatment.

Methods A retrospective study of 20 patients (21 shoulders), 17 women (81%) and 3 men (19%), underwent a reverse shoulder arthroplasty between October 2012 and September 2017, for a rotator cuff arthropathy treatment, operated by a single surgeon in a single center. The patients were assessed using the Disabilities of the Arm, Shoulder and Hand (DASH) score, the Short-Form (36) Health Survey (SF-36), the visual analogue scale (VAS) of pain rating, and the University of California – Los Angeles (UCLA) score. The mean age at surgery was of 66 years old (range: 55 to 83 years old). The duration of symptoms before surgery was of ~ 2.5 years (range: 12 months to 6 years). The mean follow-up was of 42.4 months (range: 19 to 56.7 months).

Results The mean postoperative scores were 18.2 points in DASH; 2 points in EVA, of which 16 (77%) corresponded to mild pain, 4 (18%) to moderate pain, and 1 (5%) to severe pain; 29 points in UCLA, of which 6 patients presented a regular result (28%), 10 patients a good result (48%), and 5 patients an excellent result (24%); and 63 points in the SF-36. The complications were four cases of notching, one case of acromial fracture due to stress, and one case of postoperative infection.

Conclusions Reverse arthroplasty of the shoulder presents good functional results in the evaluated scores, providing a significant improvement in the quality of life of the patients.

Keywords

- ▶ arthroplasty, replacement, shoulder
- ▶ rotator cuff arthropathy
- ▶ shoulder arthrosis
- ▶ rotator cuff tear
- ▶ shoulder/surgery

Resumo

Objetivo Avaliar os resultados funcionais dos pacientes submetidos a artroplastia reversa de ombro, para tratamento da artropatia do manguito refratária a tratamento conservador.

* Work performed at Hospital Orthoservice, São José dos Campos, SP, Brazil.

Métodos Estudo retrospectivo de 20 pacientes (21 ombros), 17 mulheres (81%) e 3 homens (19%), submetidos a artroplastia reversa de ombro no período de outubro de 2012 a setembro de 2017, para tratamento de artropatia de manguito rotador, operados por um único cirurgião em um único centro. Os pacientes foram avaliados pelo escore de disfunções do braço, ombro e mão (DASH, na sigla em inglês), pelo questionário genérico de avaliação de qualidade de vida SF-36 (SF-36), pela escala visual analógica de dor (EVA) e pelo escore da Universidade de Los Angeles – Califórnia (UCLA, na sigla em inglês). A média de idade na cirurgia foi de 66 anos (variação de 55 a 83 anos). O tempo de sintomas antes da realização da cirurgia foi de ~ 2,5 anos (variação de 12 meses a 6 anos). O seguimento médio foi de 42,4 meses (variação de 19 a 56,7 meses).

Resultados A média dos escores pós-operatórios foi de 18,2 pontos no DASH; de 2 pontos na EVA, sendo 16 (77%) de dores leves, 4 (18%) de dores moderadas e 1 (5%) de dor intensa; de 29 pontos no UCLA, sendo 6 pacientes com resultado regular (28%), 10 pacientes com resultado bom (48%), e 5 pacientes com resultado excelente (24%); e de 63 pontos no SF-36. Tivemos como complicações quatro casos de *notching*, um caso de fratura de acrômio por estresse, e um caso de infecção pós-operatória.

Conclusões A artroplastia reversa do ombro apresenta bons resultados funcionais nos escores avaliados, propiciando melhora significativa na qualidade de vida dos pacientes.

Palavras-chave

- ▶ artroplastia do ombro
- ▶ artropatia do manguito rotador
- ▶ artrose do ombro
- ▶ rotura de manguito
- ▶ ombro/cirurgia

Introduction

Rotator cuff arthropathy represents a spectrum of shoulder diseases characterized by rotator cuff insufficiency, decreased distance from the humeral head to the acromion, subacromial impact, and arthritic changes of the glenohumeral joint.¹ The disease affects mostly women between the 6th and 7th decades of life. The dominant limb is most commonly affected, and bilaterality occurs in between 10 and 25% of the cases.² The initial treatment should be conservative, and intervention possibilities, when needed, range from arthroscopic debridement, hemiarthroplasty, reverse arthroplasty, and arthrodesis or resection arthroplasty, both in extreme cases.¹

In the normal shoulder, the rotator cuff muscles provide a force that keeps the humeral head centered on the glenoid in all positions of the movement. With rotator cuff insufficiency, this balance is lost due to the strength of the deltoid, without opposition, which forces the humeral head to rise. Mechanically, this imbalance between the forces acting on the humeral head causes its rise, erosion of the acromion, degeneration of articular cartilage, and disuse osteopenia.³

Reverse shoulder arthroplasty has revolutionized reconstructive surgery of this joint and, due to promising clinical results, has generated a lot of enthusiasm in a short period of time.⁴ Biomechanically, reverse arthroplasty improves the functioning of the deltoid muscle by moving it distally, providing a larger lever arm with increased perpendicular distance to the center of the joint rotation, which, due to the semi-constricted shape, remains stable and compensates for the dysfunctional rotator cuff, bringing superior clinical results than other implants in the treatment of cuff arthropathy.⁵⁻⁸ Lengthening of the limb, on average 2.4 cm compared with the

contralateral side, leads to adequate deltoid muscle retention and is positively related to improvement of the function of the patient.⁹ This improved function, coupled with pain relief, is a reliable option for treating the shoulder of elderly patients with rotator cuff arthropathy refractory to the conservative treatment, allowing the patients to live with independence and quality of life.¹⁰ Reverse shoulder arthroplasty is rarely proposed for patients < 60 years old; however, there is no age limit for its indication. With this procedure, functional improvement can be achieved after days or weeks, as it allows early active mobilization without a specific rehabilitation period.¹¹ However, surgeons need to be aware not only of the potential benefits, but also of the ongoing complications and concerns about the longevity of this prosthesis.¹² The aim of our study is to evaluate the outcomes of functional and quality of life improvement in patients undergoing reverse arthroplasty after a medium-term follow-up, reporting the complications we have encountered.

Materials and methods

This was a retrospective study of 20 patients (21 shoulders), 17 women (81%) and 3 (19%) men, who underwent reverse shoulder arthroplasty from October 2012 to September 2017 to treat rotator cuff arthropathy. A total of 13 right and 8 left shoulders were operated on, and the dominant side was approached in 15 (71%) cases. One patient underwent the procedure bilaterally (– **Figure 1**). A total of 7 patients (32%) had a history of previous rotator cuff repair surgery. According to the classification of Seebauer¹³ for rotator cuff arthropathy, 7 (59%) of the shoulders were classified as 1B, 13 (59%) as 2A,

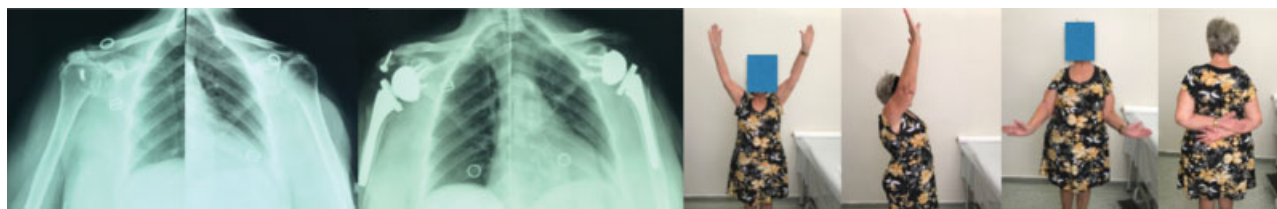

Fig. 1 Case of a 72-year-old woman with bilateral reverse prosthesis.

and 2 (8%) as 2B. The patients were assessed using the Disabilities of the Arm, Shoulder and Hand (DASH) score, the Short-Form (36) Health Survey (SF-36), the visual analogue scale (VAS) of pain rating, and the University of California – Los Angeles (UCLA) score. The average age at the time of the surgery was 66 years old (range: 55 to 83 years old). The duration of symptoms prior to the surgery was ~ 2.5 years (range: 12 months to 6 years). The mean follow-up was of 42.4 months (range: 19 to 56.7 months).

The present study included patients diagnosed with rotator cuff arthropathy who showed no or unsatisfactory improvement after conservative treatment, which consisted of 6 months of physical therapy.

Surgical technique

All of the patients underwent surgery by a single surgeon with experience of 5 to 10 years in this type of arthroplasty, in a center where an average of 11 arthroplasty procedures are performed per year.

The patients underwent general anesthesia and plexus block. In all of the cases, we used the deltopectoral pathway. In all of the cases, the subscapularis was completely uninerted, without further reinsertion. The prosthesis we used was the Equinoxe from Exactech (Exactech, Inc., Gainesville, FL, USA). The retroversion of the humeral component we used was of 20°. The direction of glenoid milling was previously planned using tomography data. In addition to the concern of placing the metaglene on the axis of the scapular body, we always avoided its superior inclination, placing it slightly inclined inferiorly. After the placement of the humeral and glenoidal components, the prosthesis was reduced and its stability was verified by assessing the tension of the deltoid muscle, range of motion, and if with piston force the components did not separate too much.

All of the patients were followed-up with periodic return after stitch removal, at 1 month, 3 months, 6 months, 1 year, and, thereafter, annually, with the execution of radiographs in anteroposterior incidences, shoulder blade profile and axillary profile. All of the patients were evaluated according to the DASH, SF-36, VAS and UCLA scores, both in the preoperative period and in the postoperative follow-up.

In the immediate postoperative period, the patients were left with a simple sling (for 3 to 5 days) for comfort only, with movements released according to pain, including active arm elevation. Physical therapy for range of motion gain was started at 2 weeks. We restricted effort and weight activities for 12 weeks.

Statistical analysis was performed by comparing pre- and postoperative measurements with the use of the Student t-test. Two-tailed and paired tests were used in all of the cases, and those with $p < 0.05$ were accepted as significant results. The statistical program used was IBM SPSS Statistics for Windows (IBM Corp, Armonk, NY, USA).

Results

Regardless of the severity of arthropathy, all of the patients had functional improvement (–**Figure 2**). The mean of postoperative scores was 18.7 (standard deviation [SD]: 24.8) points in DASH; 2 (SD: 2.4) points in EVA, of which 16 (77%) were of mild pain, 4 (18%) were of moderate pain, and 1 (5%) of severe pain; 29 (SD: 2.7) points in UCLA, of which 6 patients had a regular result (27%), 11 patients had a good result (50%), and 5 patients had an excellent result (23%); and 63 (SD: 19.2) points in SF-36. The mean postoperative range of motion was, 157° (20° to 80°) for anterior flexion (AF), 65° (40° to 80°) for abduction, 30° (-10° to 60°) for external rotation and internal rotation in L1 (T8 to S1). Comparing the pre- and postoperative scores, we observed a statistically significant improvement of all of the parameters

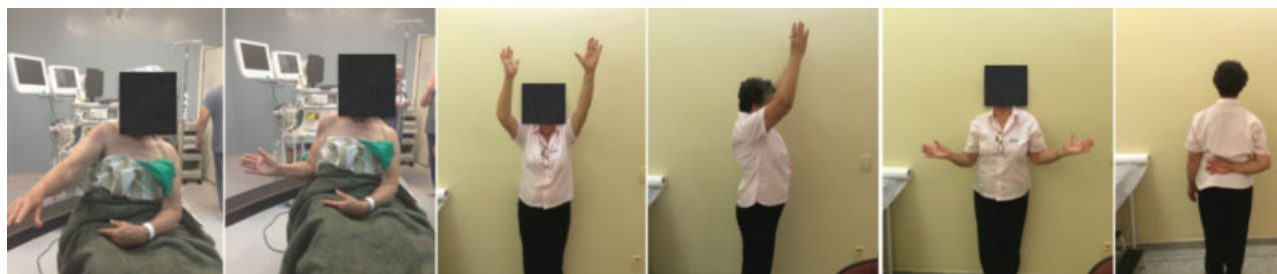

Fig. 2 Functional outcome – pre- and postoperative.

Table 1 Final results for DASH, UCLA and VAS scores*

	DASH	UCLA	VAS
Preoperative	67.2 ± 13.1 (41.6–93.2)	12.9 ± 4.8 (7–20)	7.7 ± 1.5 (5–10)
Postoperative	18.7 ± 24.8 (0–81.6)	29 ± 2.7 (22–34)	2 ± 2.4 (0–8)
<i>p</i> -value	<0.001	<0.001	<0.001
<i>n</i>	22	22	22

Abbreviations: DASH, Disabilities of the Arm, Shoulder and Hand; UCLA, University of California – Los Angeles; VAS, visual analogue scale.

*Values are the mean and the standard deviation; the interval is between brackets.

analyzed (►Tables 1 and 2). A total of 6 (28%) patients had postoperative complications, and of these, 4 presented with notching, diagnosed by postoperative radiographs; 1 case presented with postoperative infection requiring surgical revision, and 1 patient presented with acromion stress fracture.

Discussion

Reverse prosthesis is a valuable surgical option for treating rotator cuff arthropathy and has been shown, according to studies, to be able to restore free range of motion without pain, improving the clinical condition and clinical scores of the patients in a statistically significant way after surgery.¹⁴ In our study, we observed a significant improvement in all scores evaluated, consistent with what has been shown in the literature. In our study, notching was the most frequent complication, with 4 cases (18%), although it was not clinically

significant. We noticed that this complication was more frequent when the positioning of the glenosphere was slightly higher than the average; however, these patients had no differences in function or mobility. This percentage is similar to that found in the literature, which ranges from 19 to 100%.³ Infection is one of the most devastating complications of shoulder arthroplasty. Predisposing factors in reverse shoulder arthroplasty include a large subacromial space and a large surface area of the prosthesis. Infection rates range from 1 to 15%.¹⁵ In our study, this incidence was 1 case (4%). The revision of this patient was performed in a single time, removing the prosthesis, performing thorough surgical cleaning, and placing a new prosthesis with antibiotic cementation. This patient was discharged with culture-based antibiotic therapy for 6 months and performed 30 sessions in the hyperbaric chamber. Despite the need for prosthesis revision, this patient had satisfactory results (►Figure 3). As for the stress fracture of the acromion, it can occur in the postoperative period, with an incidence rate of ~ 5%. It is classified into 3 types, and its treatment, basically, depends on the postoperative moment when it appears.¹⁶ In our study, we observed only 1 case (4%), and the acromion fracture was classified as type 2, which in the absence of improvement with conservative treatment required an intervention to fix the acromion (►Figure 4). The patient who presented this complication was the one who underwent bilateral reverse arthroplasty. This patient was first operated on from her right shoulder, which was the most symptomatic, and began to present with severe pain 6 months after the procedure. A control tomography was performed, and an acromion stress fracture was diagnosed. Initially, conservative treatment was attempted, but there was no improvement, and a new surgical approach for

Table 2 Preoperative and postoperative comparative result of the Short-Form (36) Health Survey

	Functional capacity	Limitation by physical aspects	Pain	General state of health	Vitality	Social aspects	Limitations due to emotional aspects	Mental health
Preoperative	32 ± 22.5 (0–70)	3.5 ± 8.8 (0–25)	22.6 ± 16.1 (0–41)	61.7 ± 17.7 (30–92)	41.3 ± 16 (5–65)	46.6 ± 21.9 (0–75)	11.1 ± 20.6 (0–66.7)	46.7 ± 20.9 (8–96)
Postoperative	58.8 ± 27 (15–95)	52.5 ± 47.2 (0–100)	65.9 ± 24.1 (20–90)	49.3 ± 23.1 (20–87)	78.5 ± 17.2 (50–100)	77.5 ± 17 (25–100)	50 ± 47.8 (0–100)	71 ± 13.2 (48–92)
<i>p</i> -value	0.011	< 0.01	< 0.01	0.3	< 0.01	< 0.01	< 0.01	< 0.01
<i>n</i>	22	22	22	22	22	22	22	22

*Values are the mean and the standard deviation; the interval is between brackets.

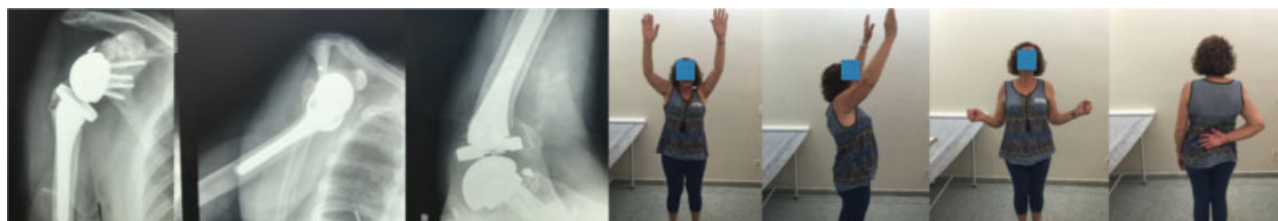


Fig. 3 67-year-old patient who presented postoperative infection requiring surgical revision, performed in a single time with antibiotic cementation on the glenoid and humeral components, showing good functional results.

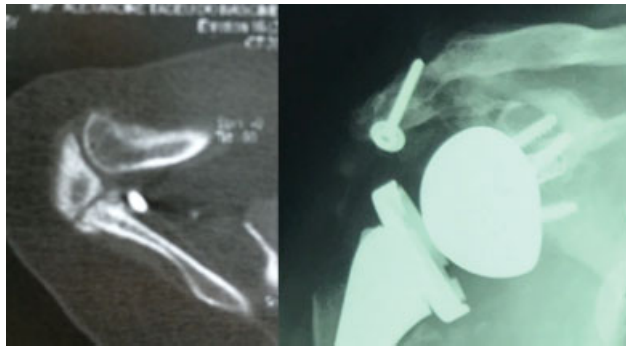


Fig. 4 This is a case of a 72-year-old woman who underwent bilateral reverse prosthesis, who evolved on the right side with a surgically treated stress fracture of the acromion.

acromion fixation and polyethylene exchange with a smaller size was indicated. With stabilization of the clinical condition of the right shoulder, with a good range of motion being observed, especially for internal rotation, which could limit personal hygiene, 1 year after the right-side reverse prosthesis, we performed the left side arthroplasty, which progressed without complications. Although we have not observed it in our series, a potential complication of reverse arthroplasty is instability. The instability of the interface of the glenosphere with the polyethylene of the humeral component leads to dislocation, and its incidence, according to the literature, ranges from 0 to 14%.² Inadequate muscle tension after prosthesis reduction, with consequent decrease in compressive forces on the components, is directly related to this complication, which is why we always test the stability of the prosthesis by making all range of motion and piston force movements, observing if there is not an excessive separation between the glenosphere and the polyethylene. When we observe this, we increase the size of the polyethylene and/or use constricted polyethylene.

Despite the complications presented in the six cases, accounting for 27%, this number is in agreement with the literature^{9,10} which shows similar numbers, and all of the patients had their problems resolved, with significant improvement in their scores, comparable to the scores of patients without complications, with no statistical difference (► **Table 3**). The reverse prosthesis improved the quality of life of virtually all patients in our study, with only 1 (4%) presenting with severe pain according to the VAS, in agreement with the literature, which shows a degree of satisfaction of 95% of the patients submitted to this procedure.¹⁷

Conclusions

Reverse shoulder arthroplasty has good functional results, with statistically significant improvement in all scores evaluated. The shoulder surgeon should keep in mind that despite the good results achieved with this procedure, there is a wide range of potential complications. For this reason, this procedure should be indicated with caution.

Table 3 Results of patients with complications

Patient	Complication	Age	Gender	Elevation	Abduction	ER	IR	UCLA	DASH	VAS
1	Notching	65	Male	170	80	40	L1	32	5	2
2	Notching	70	Female	160	70	20	L3	30	0.83	0
3	Acromion fracture	64	Female	160	60	30	L3	30	0.83	0
4	Notching	67	Female	160	50	20	L5	32	21.66	0
5	Postoperative infection	66	Female	160	60	60	L1	32	5	2
6	Notching	68	Female	170	70	60	L1	30	0.83	1

Abbreviations: DASH, Disabilities of the Arm, Shoulder and Hand; ER, external rotation; IR, internal rotation; UCLA, University of California – Los Angeles; VAS, visual analogue scale.

Conflict of interests

The authors have no conflict of interests to declare.

References

- 1 Ecklund KJ, Lee TQ, Tibone J, Gupta R. Rotator cuff tear arthropathy. *J Am Acad Orthop Surg* 2007;15(06):340–349
- 2 Favaro RC, Abdulahad M, Filho SM, Valerio R, Superti MJ. Artropatia de manguito: o que esperar do resultado funcional da artroplastia reversa? *Rev Bras Ortop* 2015;50(05):523–529
- 3 Neer CS II, Craig EV, Fukuda H. Cuff-tear arthropathy. *J Bone Joint Surg Am* 1983;65(09):1232–1244
- 4 Gerber C, Pennington SD, Nyffeler RW. Reverse total shoulder arthroplasty. *J Am Acad Orthop Surg* 2009;17(05):284–295
- 5 Zeman CA, Arcand MA, Cantrell JS, Skedros JG, Burkhead WZ Jr. The rotator cuff-deficient arthritic shoulder: diagnosis and surgical management. *J Am Acad Orthop Surg* 1998;6(06):337–348
- 6 Matsen FA 3rd, Boileau P, Walch G, Gerber C, Bicknell RT. The reverse total shoulder arthroplasty. *J Bone Joint Surg Am* 2007;89(03):660–667
- 7 Ferreira Neto AA, Malavolta EA, Assunção JH, Trindade EM, Gracitelli ME. Artroplastia reversa do ombro: avaliação dos resultados clínicos e da qualidade de vida. *Rev Bras Ortop* 2017;52(03):298–302
- 8 Schwitzguébel AJ, Haas C, Lädermann A. Reverse shoulder arthroplasty. *Rev Med Suisse* 2016;12(504):266, 268–269
- 9 Amaral MVG, Faria JLR, Siqueira G, et al. Artroplastia reversa do ombro no tratamento da artropatia do manguito rotador. *Rev Bras Ortop* 2014;49(03):279–285
- 10 Gerber C, Canonica S, Catanzaro S, Ernstbrunner L. Longitudinal observational study of reverse total shoulder arthroplasty for irreparable rotator cuff dysfunction: results after 15 years. *J Shoulder Elbow Surg* 2018;27(05):831–838
- 11 Smithers CJ, Young AA, Walch G. Reverse shoulder arthroplasty. *Curr Rev Musculoskelet Med* 2011;4(04):183–190
- 12 Nerot C, Ohl X. Primary shoulder reverse arthroplasty: surgical technique. *Orthop Traumatol Surg Res* 2014;100(1, Suppl):S181–S190
- 13 Seebauer L. Total reverse shoulder arthroplasty: European lessons and future trends. *Am J Orthop* 2007;36(12, Suppl 1):22–28
- 14 Petrillo S, Longo UG, Papalia R, Denaro V. Reverse shoulder arthroplasty for massive irreparable rotator cuff tears and cuff tear arthropathy: a systematic review. *Musculoskelet Surg* 2017;101(02):105–112
- 15 Boileau P, Watkinson D, Hatzidakis AM, Hovorka I. Neer Award 2005: The Grammont reverse shoulder prosthesis: results in cuff tear arthritis, fracture sequelae, and revision arthroplasty. *J Shoulder Elbow Surg* 2006;15(05):527–540
- 16 Crosby LA, Hamilton A, Twiss T. Scapula fractures after reverse total shoulder arthroplasty: classification and treatment. *Clin Orthop Relat Res* 2011;469(09):2544–2549
- 17 Zumstein MA, Pinedo M, Old J, Boileau P. Problems, complications, reoperations, and revisions in reverse total shoulder arthroplasty: a systematic review. *J Shoulder Elbow Surg* 2011;20(01):146–157